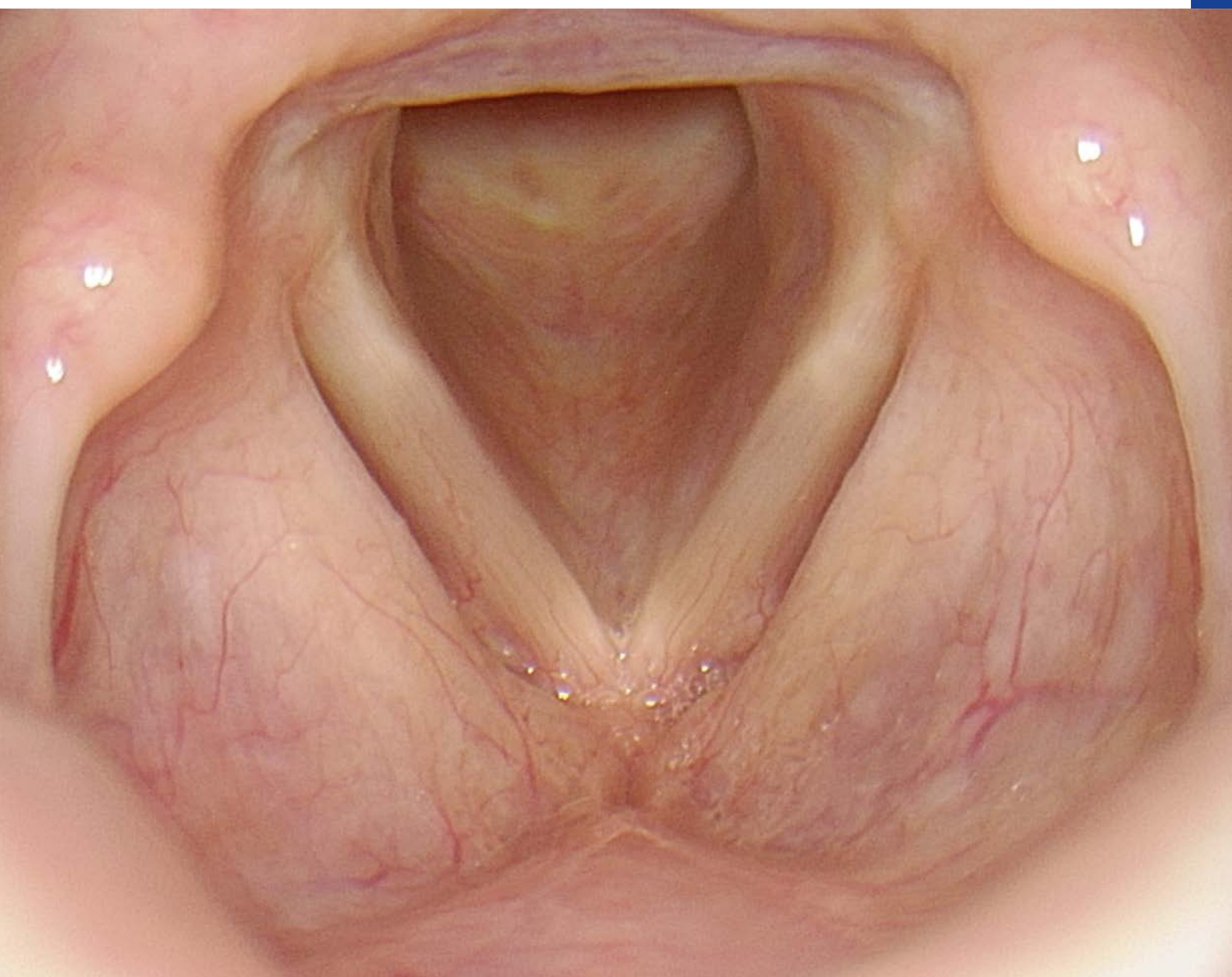


## OFFICE-BASED LARYNGOSCOPY

Good Practicing Laryngoscopy by Susanne Fleischer, MD and Markus Hess, MD



CONTENTS

1 INTRODUCTION ..... 5

2 EQUIPMENT FOR IMAGE ACQUISITION..... 9

2.1. Arrangement of the Examination Room..... 10

2.2. Image Acquisition and Processing ..... 11

2.2.1. General Remarks ..... 11

2.2.2. Preparing the Equipment..... 12

2.3. Examples of Poor Image Quality ..... 14

2.4. Endoscopes for Laryngoscopy ..... 15

2.4.1. General Remarks ..... 15

2.4.2. Rigid Endoscopes..... 18

2.4.3. Flexible Endoscopes ..... 24

3 ANESTHESIA..... 31

3.1. General Remarks ..... 32

3.2. Anesthetizing the Oropharyngeal Region..... 33

3.3. Anesthetizing the Nasal Cavity..... 34

3.4. Anesthetizing the Larynx. .... 35

4 ENDOSCOPY ..... 37

4.1. Considerations Before Starting Endoscopy ..... 38

4.2. Position of Patient and Examiner ..... 39

4.3. Transoral Rigid Laryngoscopy – Handling the Endoscope..... 46

4.3.1. Left Hand: Holding the Patient’s Tongue..... 46

4.3.2. Right Hand: Inserting the Endoscope..... 48

4.3.3. The Examiner’s Head Position ..... 49

4.4. Transnasal Flexible Laryngoscopy – Handling the Endoscope ..... 50

4.4.1. Insertion of the Endoscope..... 50

4.4.2. Rotation of the Endoscope ..... 51

4.4.3. Flexible Endoscopy – How NOT to Do It ..... 52

4.4.4. Transnasal Passage and Sequence of Endoscope Positions ..... 53

4.5. Special Maneuvers for Flexible Endoscopy..... 58

4.5.1. Endolaryngeal Dipping Maneuver..... 58

4.5.2. Transstomal Flexible Endoscopy of Subglottis and Trachea..... 60

4.5.3. Transnasal Flexible Endoscopic Examination of Swallowing (FEES) ..... 62

4.5.4. Transnasal Flexible Esophagoscopy (TNE)..... 64

4.6. Examination of Children..... 66

4.6.1. General Remarks ..... 66

4.6.2. Transoral Rigid Endoscopy of Children..... 67

4.6.3. Transnasal Flexible Endoscopy of Children..... 68

4.6.4. Transnasal and Transoral Endoscopy of Babies (Flexible and Rigid)..... 69

5 RECOMMENDED SEQUENCE OF PROCEDURES..... 71

6 TIPS AND TRICKS ..... 77

6.1. How to Solve Problems with Poor Image Quality ..... 78

6.2. Patient-Related Problems: Secretions and Gag Response..... 85

6.3. Special Maneuvers..... 87

6.4. Special Positioning of Endoscope or Patient ..... 93

7 STROBOSCOPY ..... 109

8 OFFICE-BASED PHONOSURGERY ..... 115

8.1. Phonosurgery, Rigid Transoral Procedure..... 117

8.2. Phonosurgery, Flexible Transnasal Procedure..... 118

8.3. Phonosurgery, Percutaneous Procedure with Transnasal Visualization..... 119

9 ACKNOWLEDGEMENTS / DISCLOSURE / THE AUTHORS..... 121

10 SPECIALIZED TECHNICAL EQUIPMENT..... 125

11 PREPARATION, CLEANING, AND HYGIENE..... 129

12 PRODUCT INFORMATION..... 139

## OLYMPUS DISCLAIMER

The information presented here is for your general knowledge and background only. Please thoroughly review the relevant Users Manual(s) for instructions, warnings and cautions. The information presented here comes from sources considered to be dependable. However, we make no representations, warranties or other expressed or implied warranties or guarantees regarding the accuracy, reliability or completeness of the information. To the maximum extent permitted by applicable law, under no circumstance shall Olympus or its employees, consultants, agents or representatives be liable for any costs, expenses, losses, claims, liabilities or other damages (whether direct, indirect, special, incidental, consequential or otherwise) that may arise from or be incurred in connection with the information provided or any use thereof. This limitation of liability shall not apply to acts of willful intent or gross negligence or to claims for culpable caused damages to life, body and health and to claims arising from the German Act on Product Liability (Produkthaftungsgesetz).

## INTRODUCTION



Universitätsklinikum  
Hamburg-Eppendorf



DEUTSCHE  
STIMMKLINIK



## INTRODUCTION

Recent progress in the development of optical systems means that there are now several ways to obtain great laryngeal images in the consulting room. As a general rule, combining different methods, i.e. rigid or flexible endoscopy with stroboscopy, or NBI, etc., helps to gather an extended amount of information about laryngeal structure and function. In this manual, we show practical routine procedures and special maneuvers for laryngoscopy as well as the manner in which they are performed. The aim of this is to improve imaging quality while making the procedure tolerable for patients. Because special maneuvers are needed to examine some functions in voice, swallowing, and breathing, we have summarized these examination techniques in a newly coined term: functional endoscopy.

Before starting the examination, it is advisable to familiarize yourself with the equipment. In the first part (chapter 2) the most important features of the endoscopes and the technical equipment with helpful handling techniques are explained. Because good anesthesia is of crucial importance for every examination, procedures for providing effective anesthesia are discussed in chapter 3. In chapter 4, endoscopy with rigid and flexible endoscopes is discussed – together with pre-conditions such as positioning of the patient and the examiner. Its emphasis is the accurate description of handling skills because these are an essential prerequisite for good imaging. This chapter also includes further indications for endoscopy, such as FEES and TNE, and a separate section describing how to examine children.

In chapter 5 we have made several suggestions about an effective order in which the various procedures may be carried out. Some special maneuvers, tips, and tricks are described in chapter 6. We outline stroboscopy (chapter 7) and office-based phonosurgery (chapter 8). Tables have been provided

within the chapters summarizing useful maneuvers, procedures, and techniques at a glance. For most procedures we tried to include all the information within the image, thus avoiding long text passages.

Olympus provides information about the special technique of NBI as well as about the preparation and cleaning of the endoscopes and delivers some product information (chapters 10–12).

It is obvious that a small booklet on practical office-based endoscopy cannot cover all features, prerequisites, and special cases that endoscopy requires. The endoscopist can only acquire the necessary skills and experience through daily practice and continued learning. We intentionally excluded endoscopy under general anesthesia. This would have inflated the manual too much.

We hope that this manual is of some help for those who want to get familiar and skilled in office-based laryngoscopy.

Hamburg, December 2015

Susanne Fleischer, MD  
Markus Hess, MD

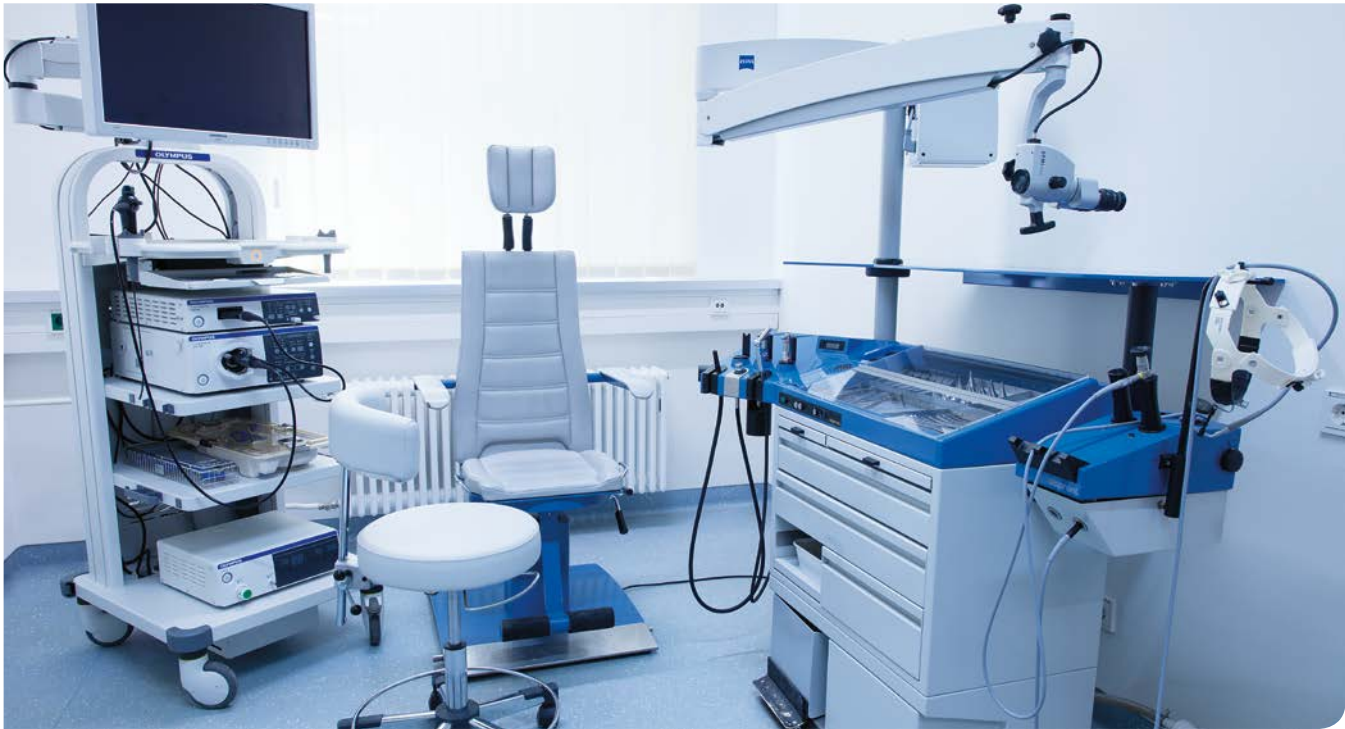

## EQUIPMENT FOR IMAGE ACQUISITION

# EQUIPMENT FOR IMAGE ACQUISITION

## 2.1. Arrangement of the Examination Room

- When arranging an office for laryngeal endoscopy there are some important aspects to consider.
- The room has to be large enough to place the necessary equipment while leaving enough space for the patient and the examiner(s) as well as for any assistants who may need to move around the examiner and patient.
  - When examinations or office-based operations are performed with the patient lying supine even more space will be required.
  - The chair for the patient should be placed so as to allow placing the equipment and instrumentation within easy reach and without cables to stumble across.
  - Place the video monitor next to the patient, so that the examiner can view both patient and monitor in a relaxed manner, either when sitting or standing.
  - Choose height-adjustable chairs for both the patient and the examiner.
  - The examiner should not be blinded by a light source or with a daylight window during the examination.



### Criteria for the Examination Room:

- Enough space for a patient, examiner and assistant.
- Enough space for a patient lying on a stretcher.
- Endoscope equipment and ENT instruments within easy reach of the examiner.
- Choose a monitor position that permits the clinician to view both the screen and the patient in reasonable comfort.
- Avoid loose cabling on the floor to avoid tripping accidents.
- Window light and room light should be dimmed.

## 2.2. Image Acquisition and Processing

### 2.2.1. General Remarks

In this section we want to stress the fact that video endoscopy relies on a series of well-attuned components. Although we cannot deal with cameras and image processing in this endoscopy manual, it needs to be said that the weakest component determines the image outcome. However, we address some aspects in the following sections.

**Keep in Mind Which Parameters Determine the Quality of Your Images:**

- Optimum illumination
- High resolution for the smallest structures
- Image centered on region of interest (ROI)
- Focus on ROI
- No image rotation (see alignment)
- Lens of endoscope should be clean; check with microscope
- Optimal distance to ROI (optimal size)
- Balanced colors (white balance)
- Adequate color and contrast balance

- In most ENT offices providing laryngoscopy, video or computer recording is usually available.
- Video recording of the whole examination is recommended for comprehensive assessment and reevaluation as well as for documentation, demonstration to the patient, teaching and monitoring pre- and postoperative outcome.
- Video editing saves data space, but requires extra time. In busy offices, there might not be enough time to edit videos.
- All components for video laryngoscopy and archiving be adjusted and balanced in order to optimize image quality: Endoscope, light source, camera, recorder, monitor, stroboscope, light filters (e.g. NBI), printer, computer, server.
- When video recording of huge data sets is mandatory, choose the best trade-off between image quality and compression ratio for digitized video.
- We believe that in the near future one can expect easy image acquisition with mobile devices, e.g. with an adapter connected to a smart phone.

2.2.2. Preparing the Equipment

- Before starting the examination, the equipment (which includes light source, camera, endoscope and recorder) has to be prepared and connected.
- Adjust the focus of the endoscope and the camera.
- There are various parameters determining image quality that need special attention (also see chapter 6.1.).
- Be sure you have chosen the right settings. Check before the examination starts.
- There are various different systems, so we can only describe the most important and most common parameters.
- Depending on your system, some parameters can be selected either on the camera or on the processor.

Checklist: Preparing the Equipment

Processor

☐

Switch on devices

☐

Archive patient's data

☐

Connect the endoscope, camera, recorder and light source

☐

Select light control (automatic/manual)

☐

Connect fiber-optic light cable either to a continuous light source or stroboscope

Endoscope

☐

Adjust white balance in the image

☐

Calibrate image with a test chart

☐

Focus for distance (4–6 cm works well in most cases)

☐

Defocus to avoid moiré pattern (fiberscope)

☐

Align camera

☐

Apply antifog agent on tip of endoscope

☐

Check the image orientation on the monitor

Examiner

☐

Ensure you are in a comfortable sitting position including comfortable height of chairs

☐

Choose suitable position for the foot pedals

☐


Use gloves

☐

Dim room light and sunlight

☐


Ensure that your head is in a comfortable position that permits a view of the patient and the monitor



In some systems, focus and zoom can be adjusted with buttons, i.e. electronically, or with adjustment rings (mechanically)



2.3. Examples of Poor Image Quality



Acceptable image: Centered, not rotated, focussed, well illuminated, sufficient magnification, white-balanced, not blurred





Image rotated



Region of interest not centered





Image too dark



Image overmodulated



Not white-balanced



Not well focussed – or fogged





Image blurred due to fluid on lens



Region of interest too far away

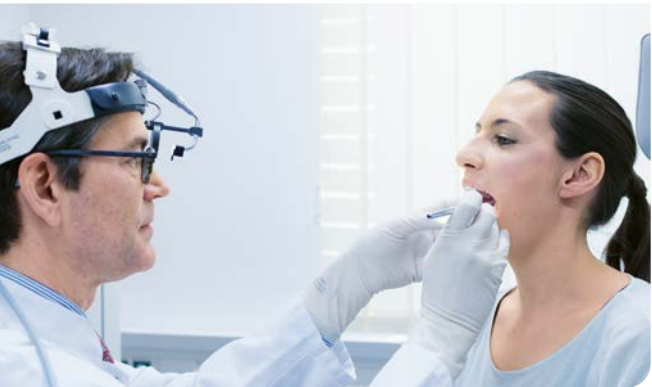
Here, reasons for poor image quality are shown. Laryngoscopic images with the same problems are shown in chapter 6.1.

2.4. Endoscopes for Laryngoscopy

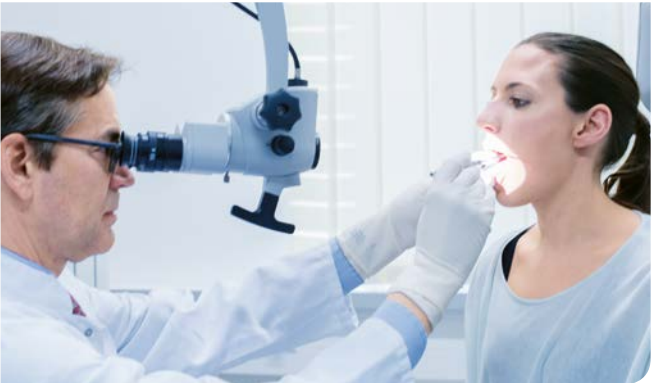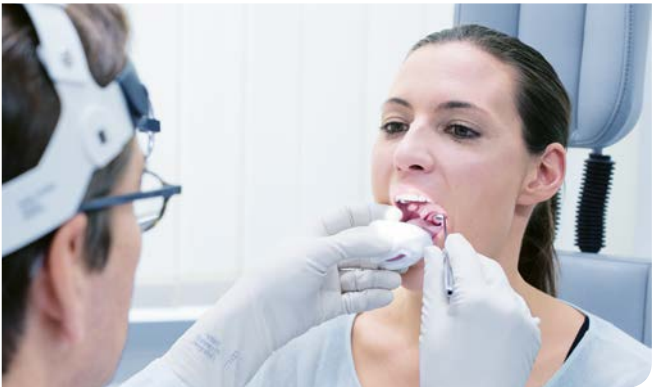
2.4.1. General Remarks

- It is important that the examiner is entirely familiar with all instruments and devices so he can concentrate fully on the examination itself and doesn't have to struggle with problems with instrument handling.
- In this chapter you can find some basic information about endoscopes, camera systems and video images.
- Additionally, we describe some helpful tips and techniques for endoscopy. You can easily try these tricks before examining a patient.
- With the perfect knowledge of your instrumentation it is easier to take advantage of all possibilities during endoscopy.

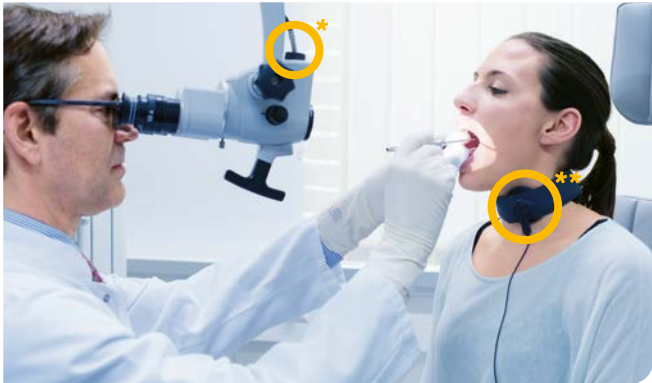
Traditionally, examination of the larynx with a mirror was standard. Here, the examiner has to pay attention to the direction of the light beam – it should be in the same axis as his viewing axis. In some situations this technique can still be helpful, e.g. for assessment of level differences, for true 3D imaging or when you want to see the true colors of the larynx.



Traditional examination of the larynx with a mirror. Position of hands similar to rigid endoscopy.



Magnified view with microscope. Use 350 mm lens for the microscope.

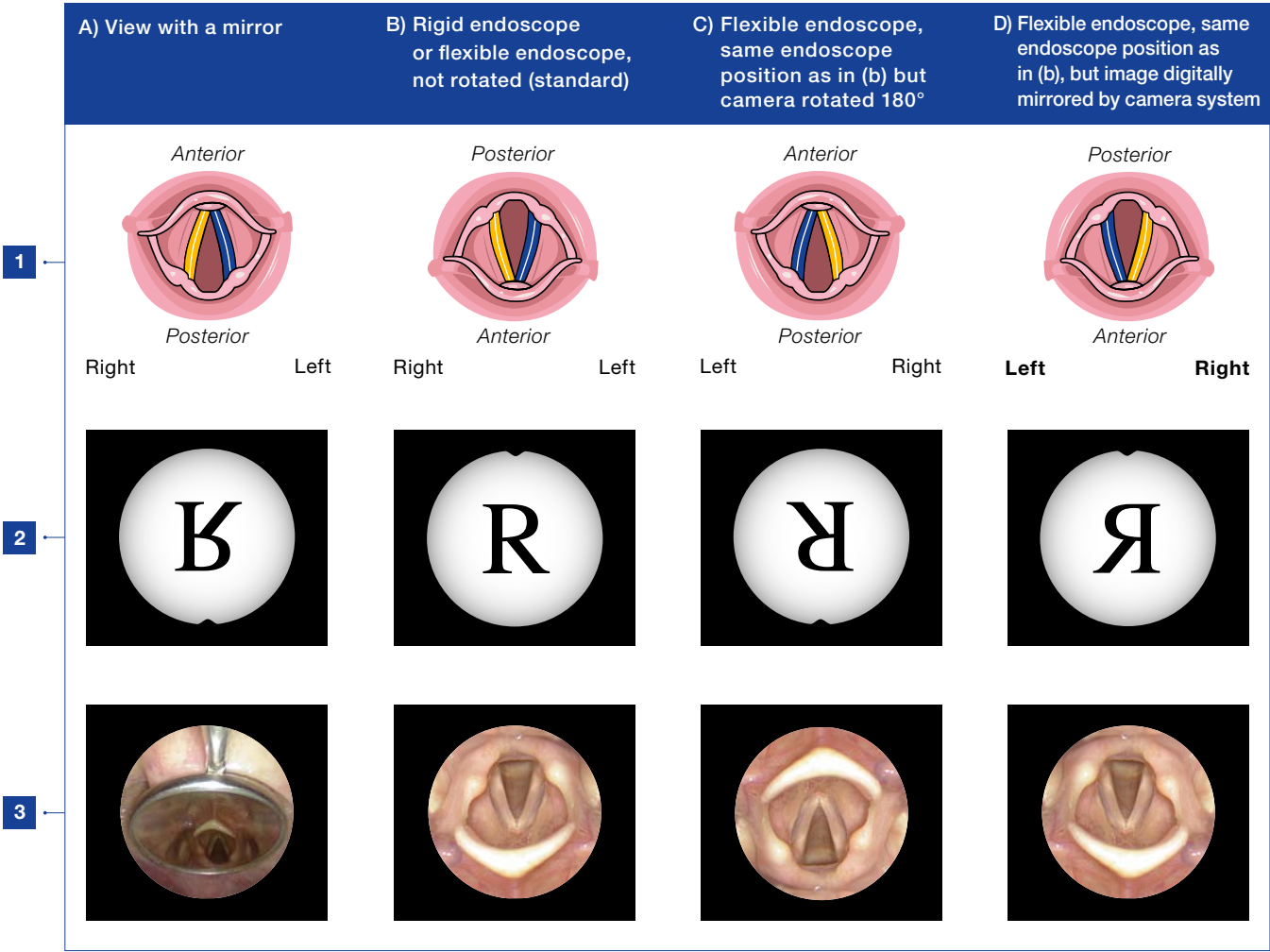


For 3D stroboscopy attach strobe light to microscope\* and trigger with microphone (here: Neck microphone\*\*). You can get stereoscopic 3D stroboscopic imaging of vocal-fold vibrations.



Relation of Image to Larynx

- When performing indirect laryngoscopy it is important to remember that the final image that is projected is dependent on the equipment being used. In practice, with modern camera systems, every orientation of anterior to posterior and right to left is possible. Get to know your instrumentation.
- In the traditional view with (A) a mirror compared with (B) rigid endoscopy, the anterior and the posterior aspects of the larynx are reversed (vertical inversion).
- For flexible endoscopy (B, C, D), depending on how the camera is connected and adjusted and how the examiner holds the endoscope, the image may be rotated by 180° or it may be mirrored vertically or horizontally.
- Caveat: the left and right sides in (B) and (D) are switched.



The Possibilities of Image Projection Are Illustrated Here:

- Line 1 shows a scheme of the vocal folds with the specification of anterior to posterior and right to left.
- Line 2 illustrates with the letter R what happens to a picture.
- In Line 3 laryngoscopy was performed in that specific way and the picture of the larynx is shown.

Indication for Rigid and Flexible Laryngoscopy

- There are numerous endoscopes available on the market for indirect laryngoscopy.
  - When choosing between rigid and flexible laryngoscopy, it is important to know the specific advantages of both techniques.
  - To obtain maximum information from the examination it is often best to use both techniques (see Table 2.1. and Table 5.1).
  - With the development of the distal-chip cameras the image quality of flexible endoscopy has improved dramatically.
  - Advantages of rigid endoscopy are less significant now than in former times when compared with glass-fiber flexible endoscopes. But rigid endoscopes can still provide high-quality images.
  - Controlling the position of the endoscope tip is easier when using a rigid endoscope rather than a flexible one. Symmetry and orientation of the image is easier to maintain during rigid endoscopy.
  - For rigid laryngoscopy, endoscopes with 70° and 90° angles have different advantages. Typically, 70° laryngoscopes are best examining of children and visualizing the anterior commissure.
  - In some countries flexible endoscopes must be cleaned in a time-consuming way. Rigid endoscopes are mostly cheaper and easier to clean. Thus, some examiners might prefer rigid endoscopes.
  - In the future, high-definition flexible chip-on-the-tip endoscopes may shift your choice to flexible endoscopy.
- Experience shows ...
- ... that where a flexible chip-on-the-tip endoscope is available it will be used more and rigid endoscopy will be performed less frequently.
  - ... that when no flexible chip-on-the-tip endoscope is available and a fiberscope must be used, rigid endoscopy will be performed more frequently as the image quality is significantly better than that of the glass-fiber instruments.

Endoscope		Advantage	Special Application
Rigid			
	70°	Autofocus	Children examination, anterior commissure
	90°	Zoom (bifocal) in some endoscopes	Same magnification as with 70° and close-up position
Flexible			
	All flexible endoscopes		Patients with severe gag response Examination of subglottis/trachea Examination of arytenoid mobility Vocal tract configuration during running speech and singing Examination of swallowing
Smallest size (<2 mm) to largest useable size (nearly 5 mm)	<2 mm glass fiberscope	Very small diameter	Babies and toddlers Transglottal examination in laryngeal stenosis
	Standard fiberscope	Adaptable to different light sources (CW, strobe)	Bedside examination (because of portable pocket-sized light source)
	Chip-on-the-tip videoendoscope (smallest size 2.6 mm)	High-quality images	Looking for fine structures
	With instrument channel (≥4.8 mm)	Instrument channel allows operation, suction, etc.	Office-based surgery

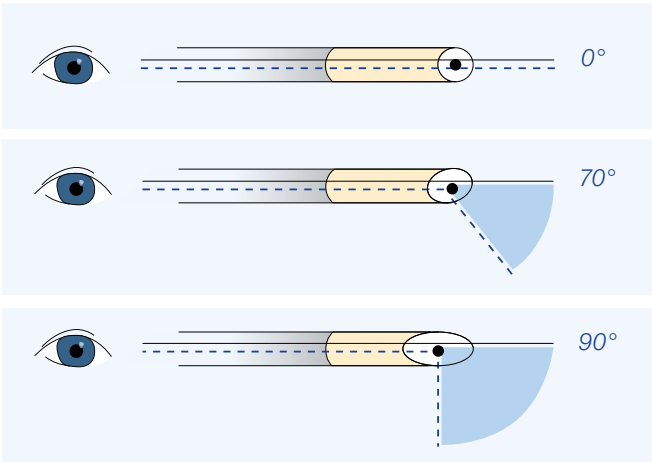
Table 2.1: Applications for rigid and flexible endoscopes (see Table 5.1)

2.4.2. Rigid Endoscopes

Characteristics

- Rigid endoscopes angled at either 70° or 90° are suitable for indirect laryngoscopy.
- For both there are different versions on the market with different diameters and various handgrips.
- In Europe rigid endoscopy was traditionally performed with a 90° endoscope. Now the 70° endoscope seems to increasingly be the instrument of choice.
- The 90° rigid endoscopes may provide dual focus for zooming.
- The 90° rigid endoscope may also have an antifog ventilation channel.

Optical Axis for Various Rigid Endoscopes:



Tip of 70° (left) and 90° (right) rigid endoscope



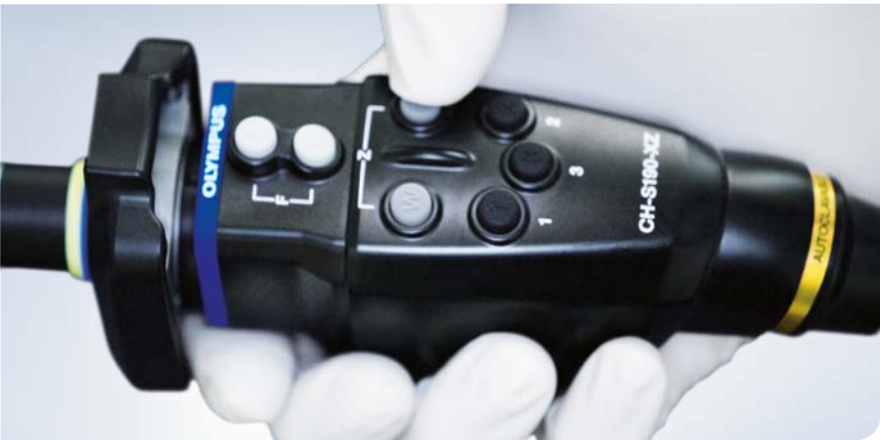70° (left) and 90° (right) rigid endoscopes – different position for same vertical optical axis

Magnification Possibilities with Rigid Endoscopes

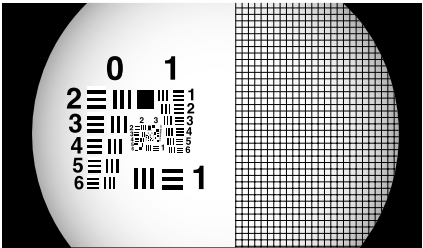
- Magnification can be determined by the distance to the object.
- Some rigid endoscopes have the option of a bifocal zoom.
- In some camera systems you can additionally zoom with the camera (see chapter 2.2.2.)
- The zoom can either be optical (within the endoscope or the camera) or digital (using image processing within camera).



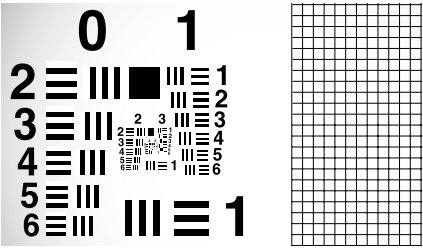
90° rigid endoscope with manual (finger) dual focus for zooming; endoscope is attached to camera




Zoom in camera




A) Test chart with normal focus of 90° rigid endoscope



B) Test chart, same distance from lens to object as in (A), but digitally zoomed. Image resolution is changed when zoom is used.



C) 70° rigid endoscopes, distance to test chart of 6 cm

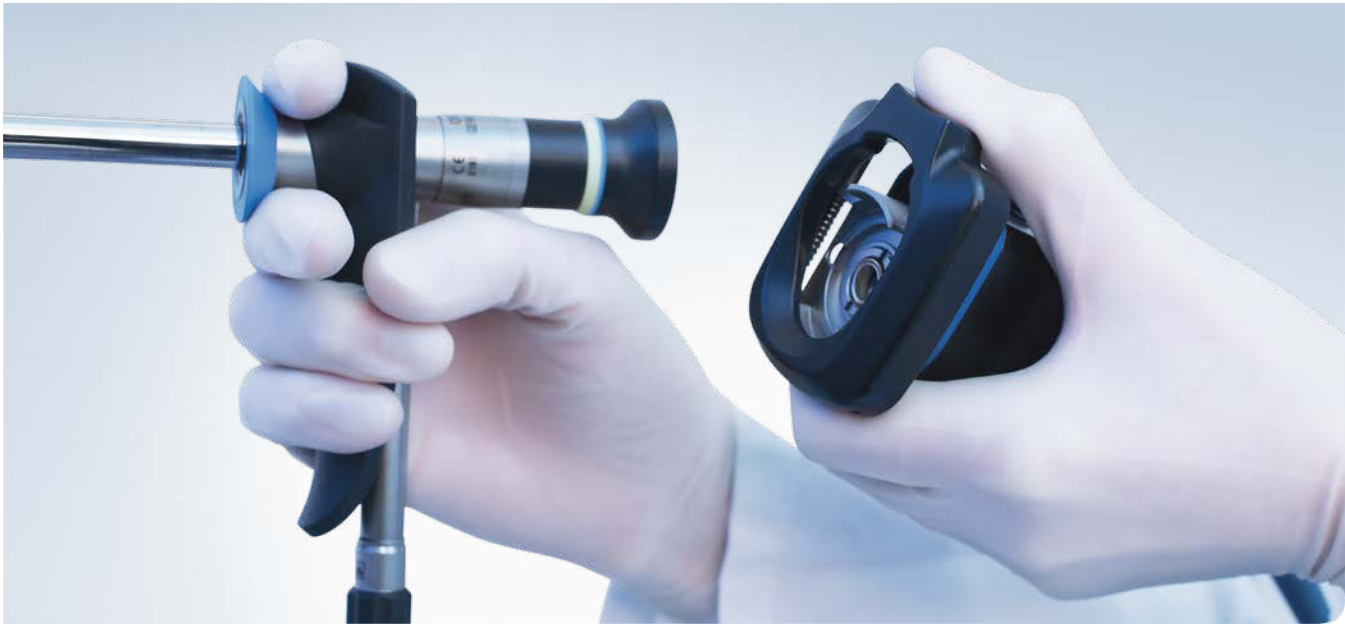

D) Same setting as in C) but with a distance of 3 cm

Rigid Endoscope and Camera Alignment

Alignment is defined as the process of adjusting parts so that they are in the proper position relative to one another.

- For rigid endoscopes correct camera alignment is important.
- When the image is rotated, laryngeal cartilage frame asymmetry is difficult to diagnose.
- When the image is rotated, assessment of arytenoid movements may be difficult.
- The patient’s anterior–posterior (i.e. sagittal) axis should be aligned with the vertical axis of the image.
- Most adapters permit rotation of the camera, enabling manual alignment as seen in the following pictures.



Attaching of endoscope and camera. Here, a clip-on adapter is shown. Most adapters allow rotation of the camera, enabling manual alignment as well as “corrective alignment,” seen in the following figures and photos.

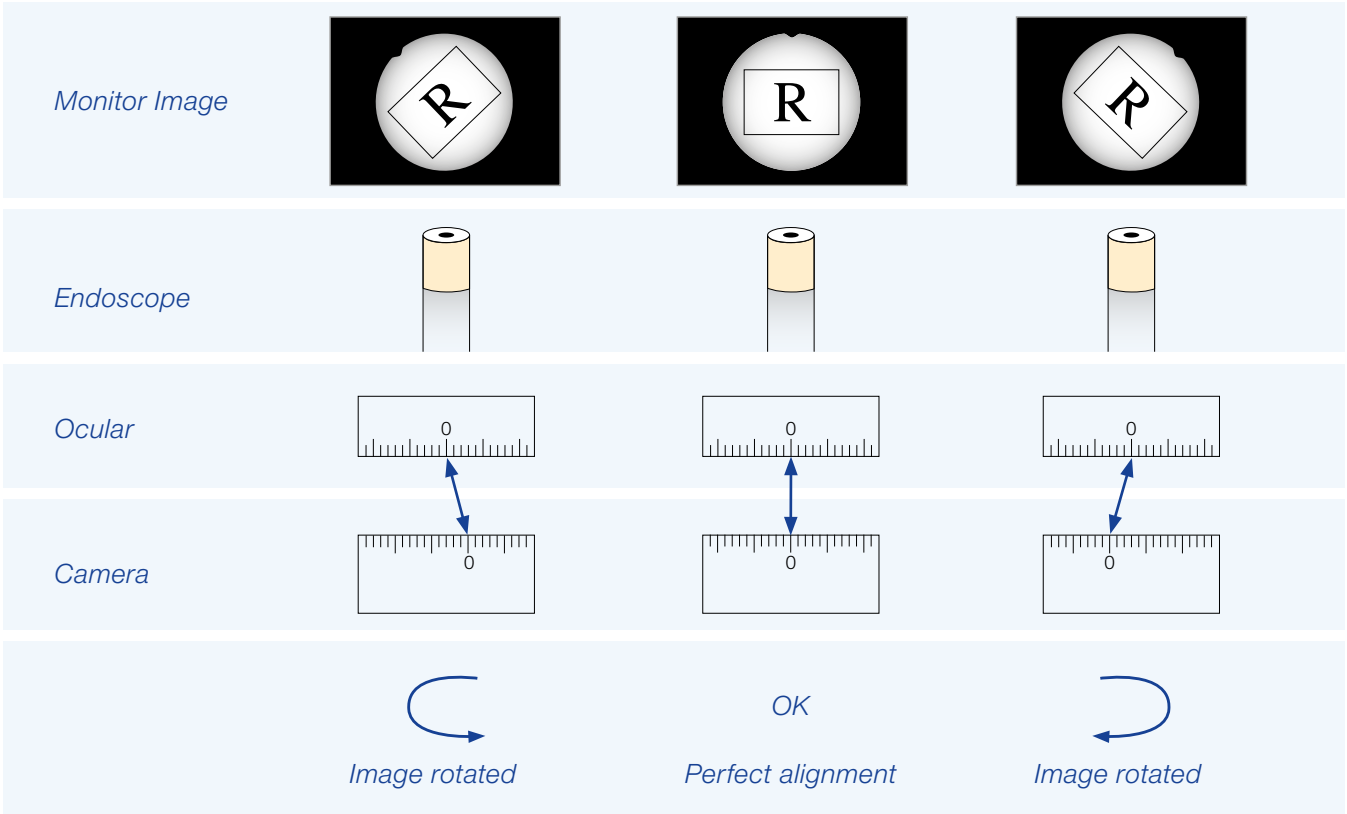
**Alignment:**

In clinical practice when performing laryngoscopy, it is assumed that the larynx is symmetrical and the vocal folds form a V. When a rigid endoscope is in an ideal median laryngoscopic position, it is in a “perfect sagittal” direction as well. In order to achieve a perfect V on the monitor it is mandatory that the camera and adaptor are aligned with the endoscope (see examples, page 21).

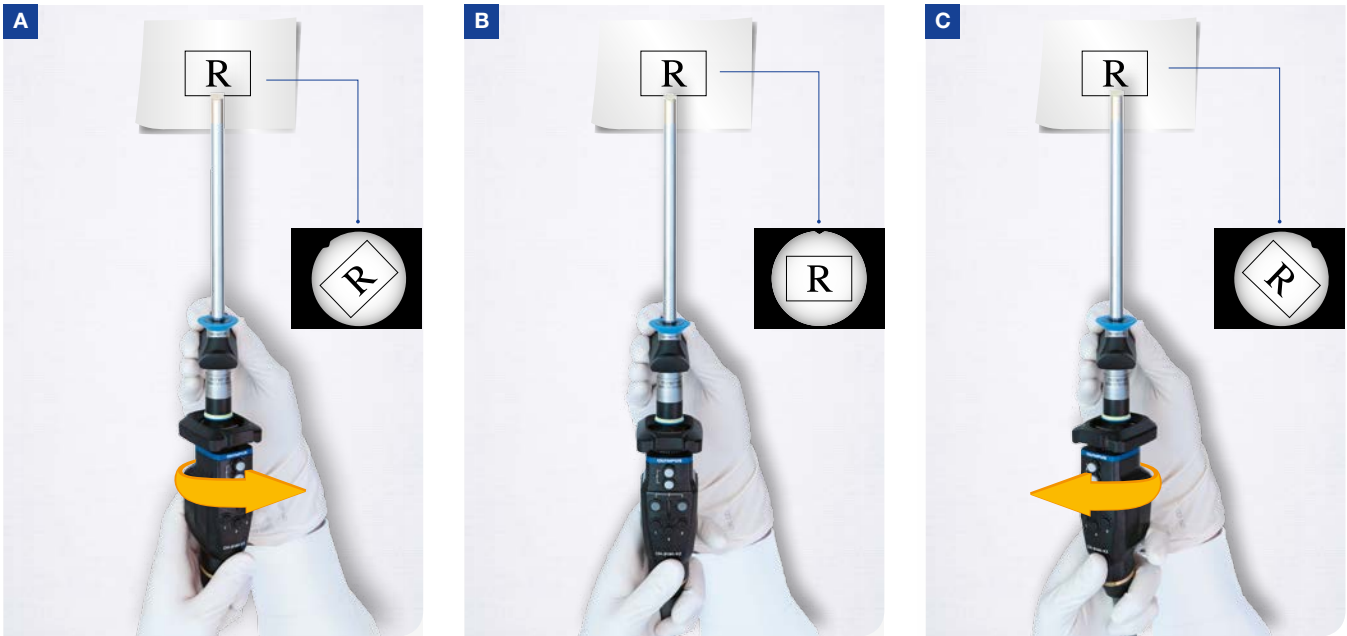
**Corrective Alignment:**

Intentional correction for (monitor) image alignment: The camera is intentionally rotated to compensate an oblique position of the rigid endoscope. The resulting image on the screen is perfectly adjusted (perfect V). Corrective alignment can be used to rectify and adjust a monitor image by rotation of the camera attached to the endoscope’s eyepiece (see examples, page 22).

How Alignment Can Influence Your Imaging




Alignment of endoscope with camera, with and without rotation: The rotated image cannot be satisfactorily corrected simply by altering the endoscope position. On the other hand, you can compensate for an oblique endoscope position with a corrective alignment of the camera.



Alignment of endoscope with camera, with and without rotation. A) If the camera is rotated clockwise, as illustrated with arrow, then the image is rotated counterclockwise. B) Perfect alignment. C) If camera is rotated counterclockwise (see arrow), then the image is rotated clockwise.

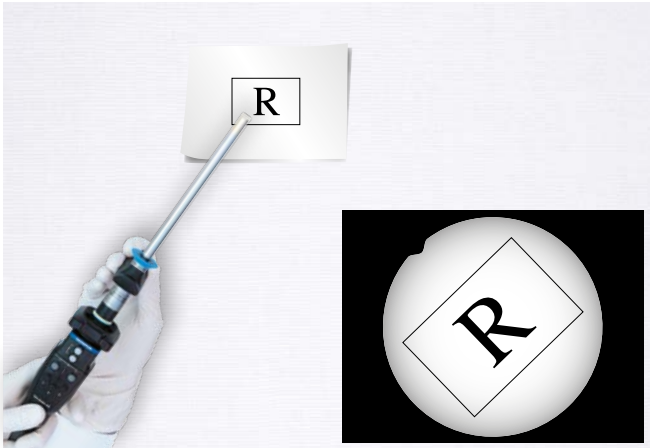


Corrective Alignment

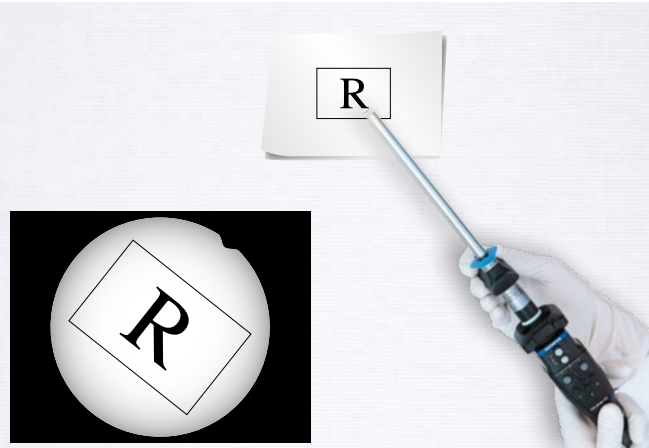


(1) Alignment of camera and endoscope is completed, when the R is not rotated on monitor.


- Perfect sagittal projection with the rigid endoscope in an ideal median position and correctly aligned (1).
- With normal alignment and an oblique endoscope position, the image seems rotated (2–3).
- You can compensate for an oblique endoscope position with intentional corrective alignment (4–5). This effect may be helpful when it is necessary to place the rigid endoscope laterally e.g., during transoral indirect surgery.




(2) When the endoscope is in alignment with the camera, but not aligned with the object, then the image seems rotated.



(3) Same situation as in (2), but from the other side



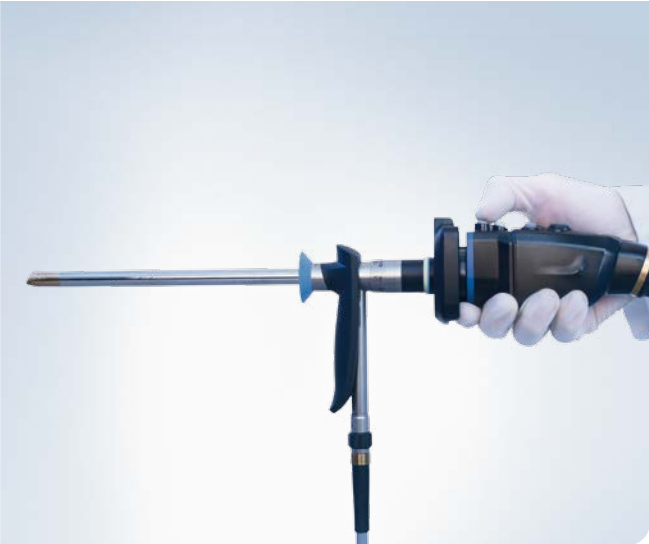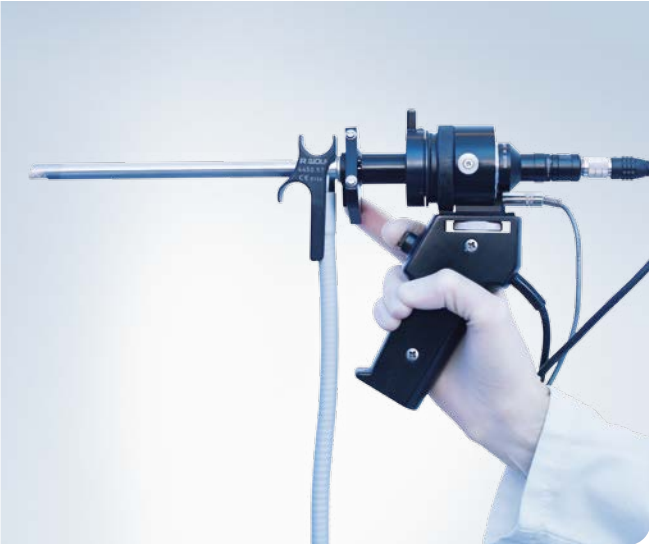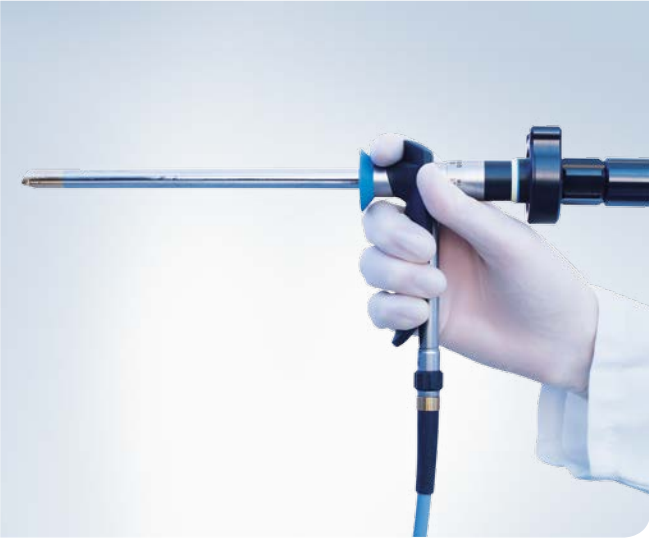
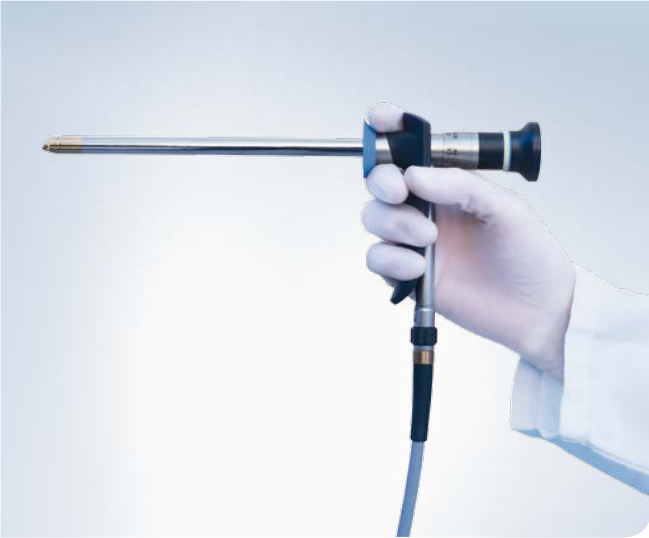(4) Oblique imaging from object to endoscope can be corrected by endoscope camera rotation. Perfect correction may result in an ideal "aligned" monitor image comparable to (1)



(5) Same situation as in (4), but now from the other side

How to Hold Rigid Endoscopes

- There are various possibilities for holding the endoscope and camera. In the following pictures, some typical handgrips are shown.
- The most appropriate grip must be chosen individually and will depend on additional switches, buttons and zoom-scrollers which have to be handled, the size of the user's hand, and on the weight of the endoscope and camera.
- The standard in endoscopy is to hold the endoscope with the right hand (because most people are right-handed).
- In office-based phonosurgery, the standard is to hold the endoscope with the left (nondominant) hand so your right (dominant) hand is free for the operation.
- There are no special recommendations for left-handed examiners.





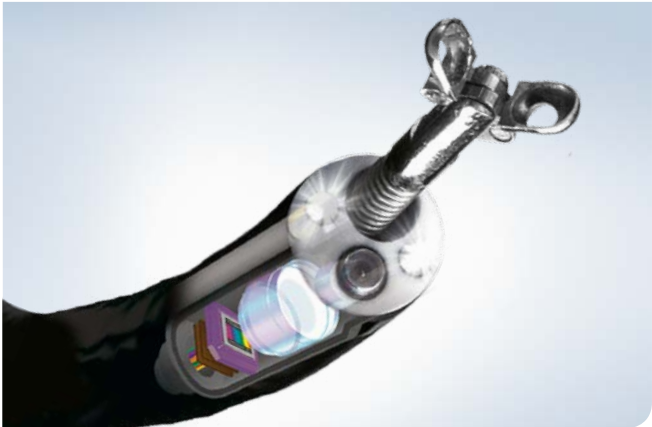2.4.3. Flexible Endoscopes

Characteristics

- All flexible endoscopes for laryngoscopy, even the newest generation, still feed light via glass fibers to the object. However, in the future modern technology will take advantage of illumination by LEDs mounted on the tip of the endoscope.
- The standard flexible endoscope also uses glass fibers (this type of endoscope is known as a fiberscope) to transmit the image to the camera.
- Endoscopes and cameras do not need to be part of a single manufacturer’s system; mixing and matching is perfectly acceptable.
- The camera of the chip-on-the-tip flexible endoscope is built into the tip. Glass fibers are only used for light transmission.
- Using a chip-on-the-tip flexible endoscope means that the examiner can only observe the larynx on a monitor screen.
- Since the implementation of chip-on-the-tip cameras, the image quality of flexible endoscopy has improved significantly, particularly when combined with high-definition TV (HDTV).
- The diameter of the chip-on-the-tip endoscope is slightly greater, but in most cases nasal passage is no problem. Diameters of > 5 mm may be too uncomfortable for most adults.



Battery pack LED light source



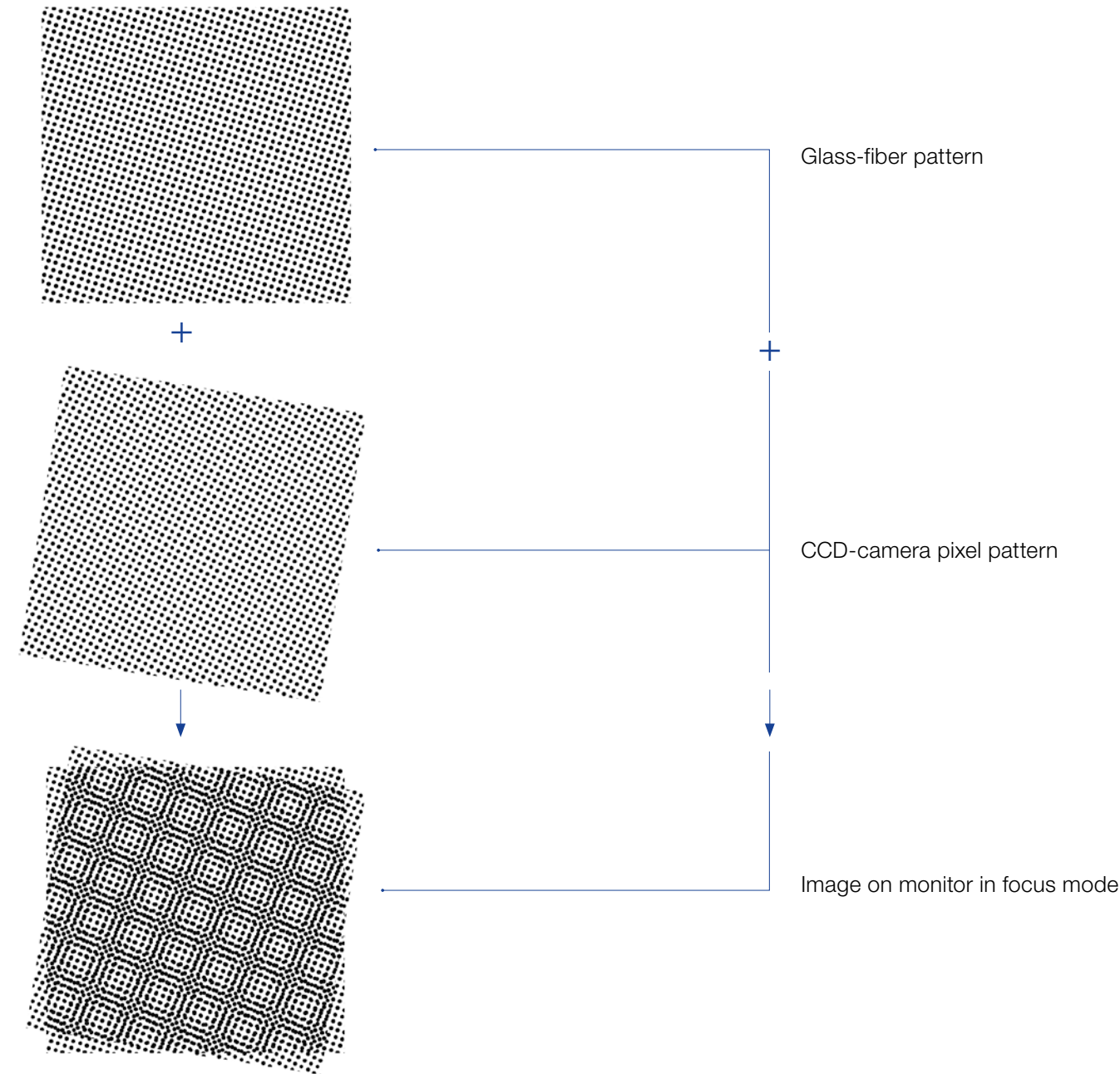
Chip-on-the-tip endoscope with instrument channel



Diameter of different flexible endoscopes for transnasal examination (standard glass fiberscopes and chip-on-the-tip endoscopes):  
Smallest size <2mm to largest size approx. 5 mm

Flexible Endoscope and Camera Adjustment

- Chip-on-the-tip cameras do not need adjustment (no alignment, no focussing), because the image is not transmitted through glass fibers.
- Glass-fiber flexible endoscopes (fiberscopes) not only need adjustment for alignment and focus, but also to minimize the moiré pattern. The superimposition of the glass-fiber pattern and the camera pixel pattern produces a secondary interference pattern known as the moiré pattern.
- This effect can be minimized by slightly defocussing the image.
- Some cameras have the option of an automatic filter for minimizing the moiré pattern.



Source: <http://de.wikipedia.org/wiki/Moiré-Effekt>










How to Hold a Flexible Endoscope

- There are various possibilities for holding a flexible endoscope. In the following some typical handgrips for a chip-on-the-tip flexible endoscope are shown.
- The most versatile grip must be chosen individually, and will vary depending on any additional switches, buttons and cameras which have to be handled as well as the weight of the apparatus and the size of the endoscopist's hand.
- In Germany, the standard for laryngoscopy is to hold the endoscope with the right hand and move the tip with the index finger (A). When the endoscopist is sitting, grip A might be the most feasible choice.
- When thumb control is preferred, you might want to choose grip B or C.
- There are no special recommendations for left-handed examiners.
- The design of the endoscope and the shape of the camera and adaptor will also determine the most useful grip.

Our Standard: Index Finger Controls Tip Deflection	Different Handling: Thumb Controls Tip Deflection	Alternative Handling: Thumb Controls Tip Deflection, Endoscope Is Held Horizontally
<div>A</div>  <p>Viewed from left</p>	<div>B</div>  <p>Viewed from left</p>	<div>C</div>  <p>Viewed from left</p>
<div>A</div>  <p>Viewed from right</p>	<div>B</div>  <p>Viewed from right</p>	<div>C</div>  <p>Viewed from right</p>

How to Move the Tip of a Flexible Endoscope

- In our department the standard grip for laryngoscopy is to hold the endoscope with position A and move the tip with the index finger.
- Keep in mind what is happening to the image when you rotate endoscope and camera (see chapter 2.4.1.).
- Make sure that you can grip the endoscope firmly and that you can take advantage of the full range of motion of the lever.
- In the following pictures, the alternative grip with the endoscope held horizontally, as demonstrated in the previous set of pictures under C, is not shown.

Tip of Endoscope	Position A: Index Finger Controls Tip Deflection	Position B: Thumb Controls Tip Deflection
 <p>Tip curved backwards</p>	<div>A</div> 	<div>B</div> 
 <p>Tip straight</p>	<div>A</div> 	<div>B</div> 
 <p>Tip curved forwards</p>	<div>A</div> 	<div>B</div> 



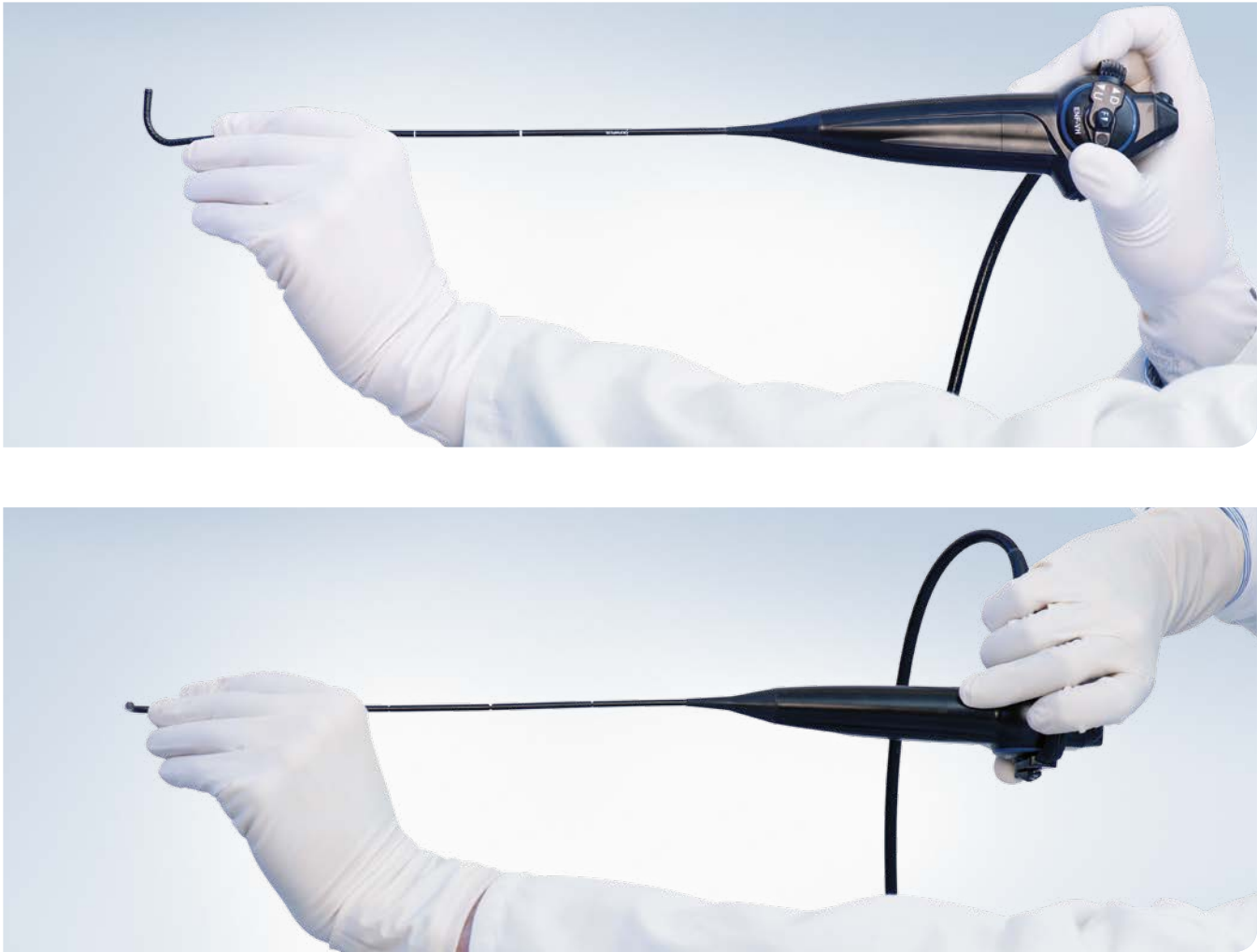
How to rotate the tip of a flexible endoscope

- In some situations it is helpful to rotate the tip of the endoscope axially, in order to alter the view of the vocal folds.
- There are two ways to achieve this:
  - A) By rotating the whole endoscope
  - B) By rotating the tip alone which becomes possible after bending the flexible shaft into a siphon shape

Terminology:


When describing how to hold a flexible endoscope, the hand holding the handpiece is referred to as the “proximal” hand and the other hand holding the flexible part the “distal” hand. Thus, for right-handed endoscopists the right hand is generally the proximal hand whilst the left is the distal hand.

Demonstration of Rotating the Tip with the Whole Endoscope



A) When the flexible part is held in an extended straight line, axial rotation using the fingers is not possible. Rotation of the tip is only possible by rotating the whole endoscope.

Demonstration of Tip Rotation Using the Fingers of the Distal Hand by Slackening the Flexible Shaft of the Endoscope to Form a Siphon



Look at the thumb position of the distal hand: Rotation is possible without twisting the handle of the endoscope.

B) By forming a siphon within the proximal flexible part of the endoscope, rotation of the tip is possible by rotating the flexible shaft between the thumb and index finger of the distal hand. **Try it!**

ANESTHESIA



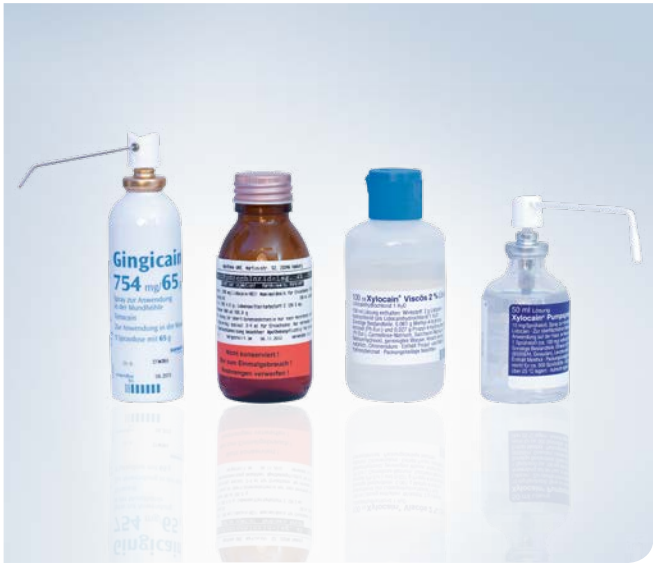# ANESTHESIA

## 3.1. General Remarks

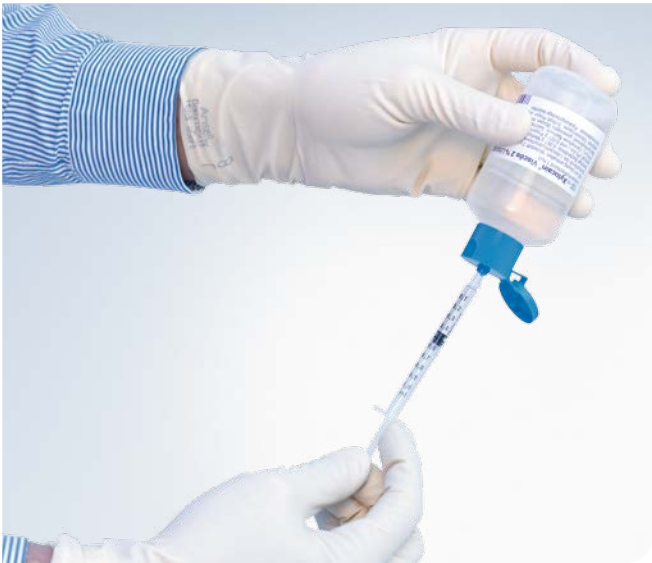- Topical anesthesia can help a lot and is frequently necessary if a good-quality recording is to be achieved.
- In our office, anesthesia of the oral cavity and/or nasal cavity is used routinely.
- But, before administering topical anesthesia
  - Ask about any history of allergic reactions (extremely rare for lidocaine)
  - Ask for patient’s general health condition and history concerning medication.
  - Explain the effects of topical anesthesia, e.g. when anesthetizing the pharynx: *“First it might burn for some seconds, then you will taste the medicine and for some minutes you will experience a sensation of swelling and an inability to swallow – this all is just a sensation, nothing like that will actually happen”*.
  - A burning sensation comes from the alcohol as a component of some lidocaine products. In children, use anesthesia without alcohol.

List of Some Useful Topical Anesthetics:

Nose:	Pharynx, Larynx:
<ul style="list-style-type: none"><li>· Lidocaine 2%, 4%</li><li>· Tetracaine</li><li>· Procaine</li></ul>	<ul style="list-style-type: none"><li>· Lidocaine 2%, 4%, 10%</li><li>· Tetracaine</li><li>· Procaine</li></ul>



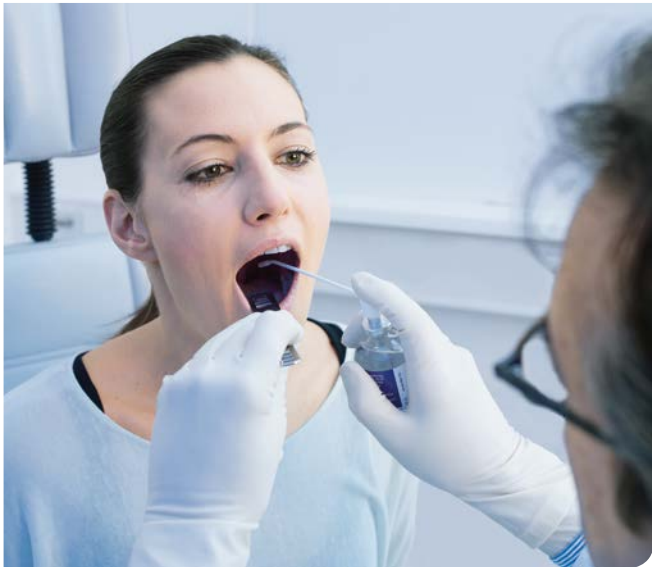
Examples for topical anesthetics



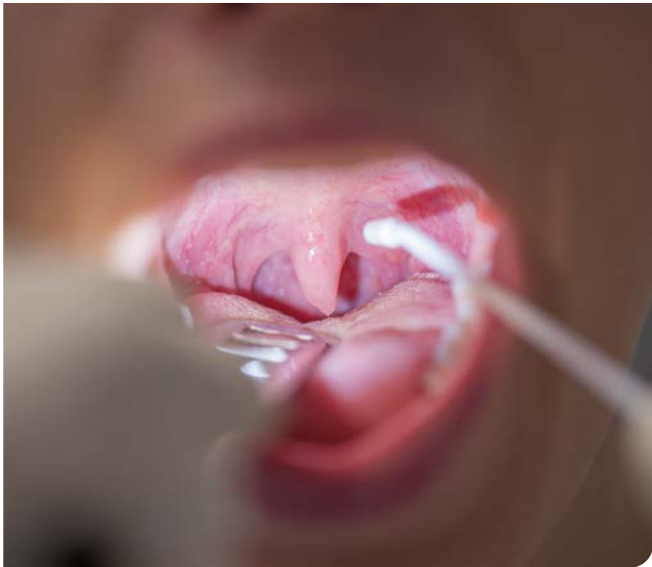In some cases the application of lidocaine gel in the nasal cavity, applied with a syringe, is a good alternative to spraying.

## 3.2. Anesthetizing the Oropharyngeal Region

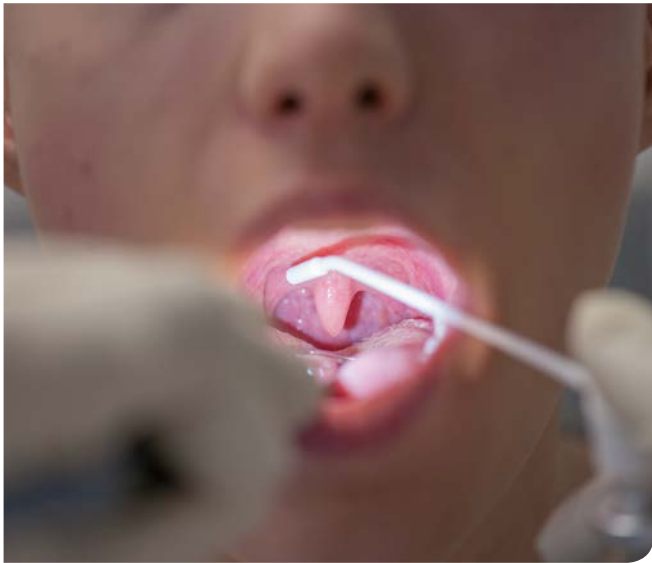- To anesthetize the oropharynx depress the tongue with a spatula.
- Ask the patient to say “aaah” and spray the velum, posterior pharynx and right and left faucial pillars.
- Count the squirts and keep the daily maximum dose of local anesthesia in mind.



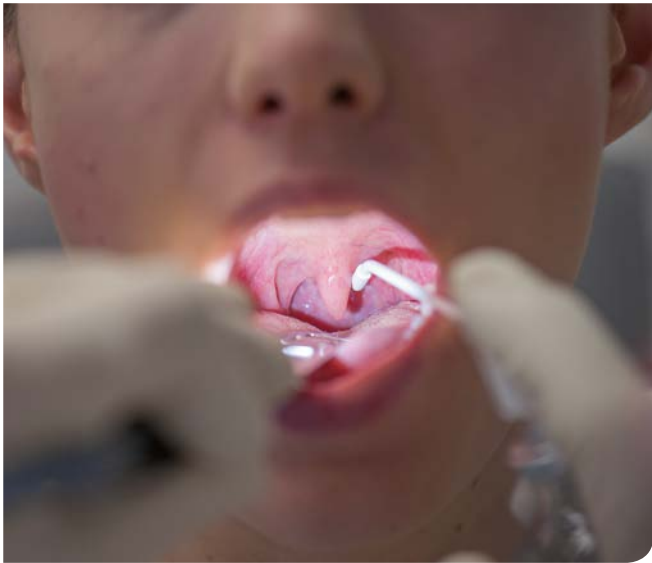Ask the patient to breathe through their mouth. Be prepared for a sudden cough in response.



First squirt goes onto the soft palate (velum).



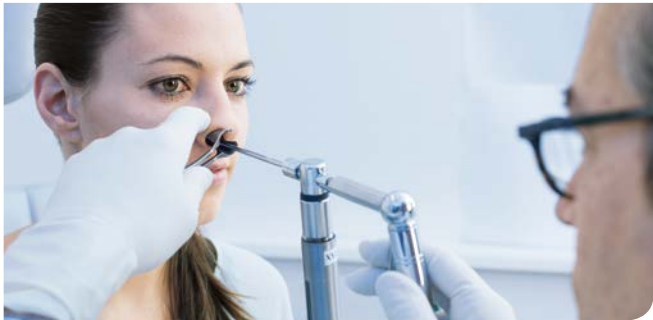Second squirt onto right posterior pharyngeal wall without touching it. Allow for swallowing if patient so wishes.



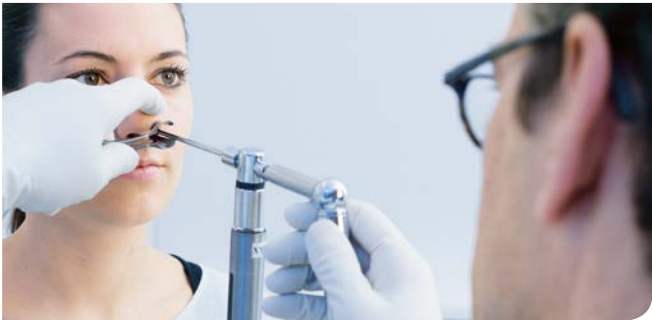Last squirt onto left posterior pharyngeal wall. Allow for swallowing. Wait for one minute before starting endoscopy.

3.3. Anesthetizing the Nasal Cavity

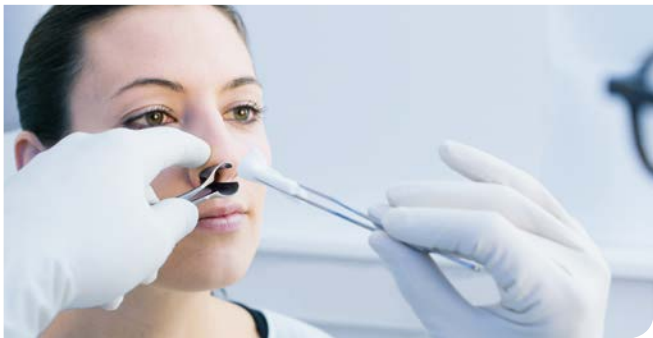- The nasal cavities are frequently asymmetrical, with one side being narrower than the other. Check both sides before inserting an endoscope.
- When anesthetizing the nasal cavity choose the side with a larger aperture in the vestibulum and anterior nasal cavity.
- Open the nostrils with a speculum and spray decongestant and local anesthetic into the lower and middle nasal meatus.
- Keep in mind that there is a daily maximum dose for local anesthetic agents.
- When choosing the side, also consider whether a particularly clear view of the left or right vocal fold is necessary – then you should choose the contralateral nasal cavity to pass the endoscope.



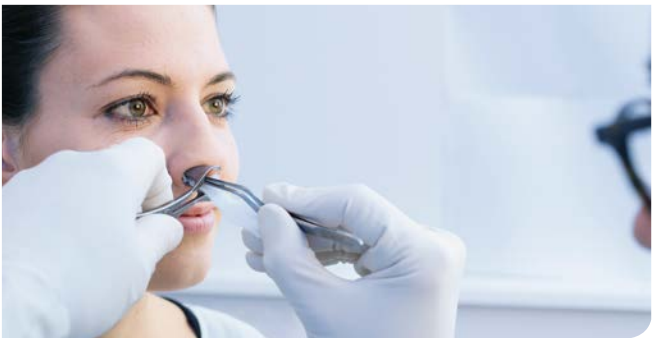Intranasal spray to the right nasal cavity: How to hold the speculum with the left hand; When spraying the nasal cavities, apply a decongestant before applying local anesthetic.



Intranasal spray to the left nasal cavity: How to hold the speculum with the left hand



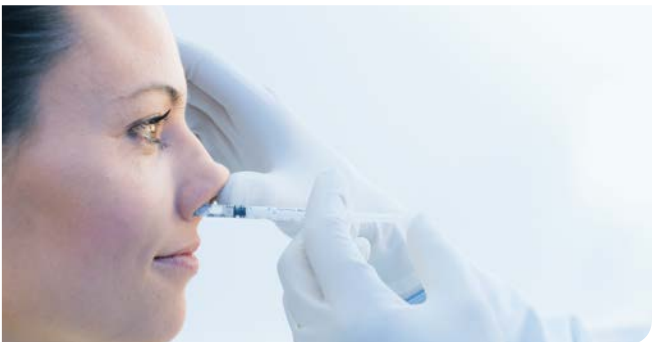Anesthetizing with nasal packing where the nasal cavity is very narrow



Putting the nasal packing into the right nasal cavity



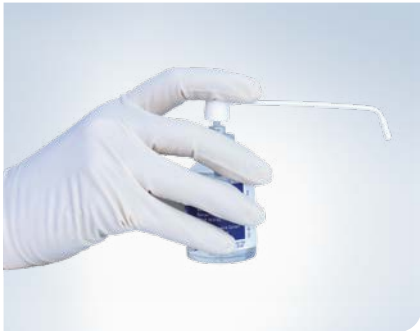A good alternative to spraying is to apply lidocaine gel with a syringe. This may be particularly helpful for bedside examination or when examining children.



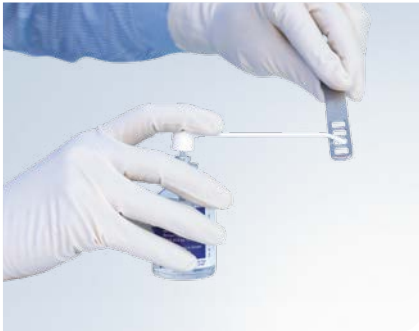For application of the gel into the lower meatus, slightly lift the tip of the nose.

3.4. Anesthetizing the Larynx

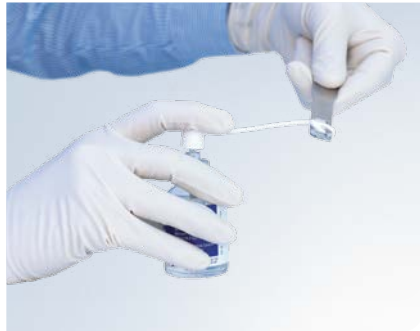- Anesthetizing the larynx can be very helpful in patients with a pronounced gag response.
- It is recommended for flexible endoscopy of the subglottis and trachea.
- It is obligatory in indirect phonosurgery.
- When spraying the larynx you may want an angled spray nozzle. The standard spray nozzle can be re-shaped to suit the individual patient.



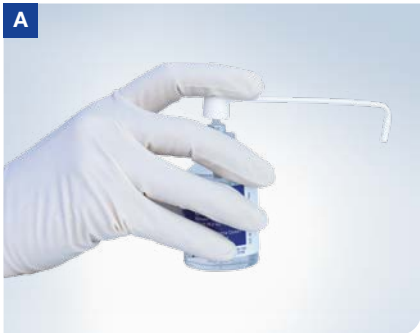Normal spray nozzle



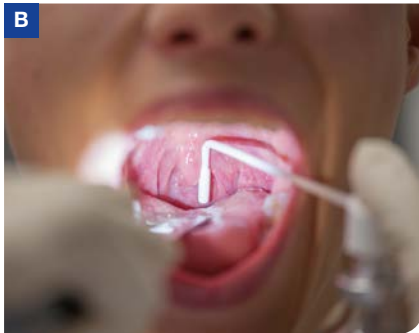Bending the spray nozzle to 90° with an instrument



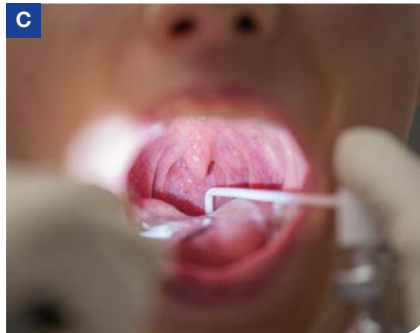Bend the spray nozzle more than 180° so it will finally stay in a position of 90°



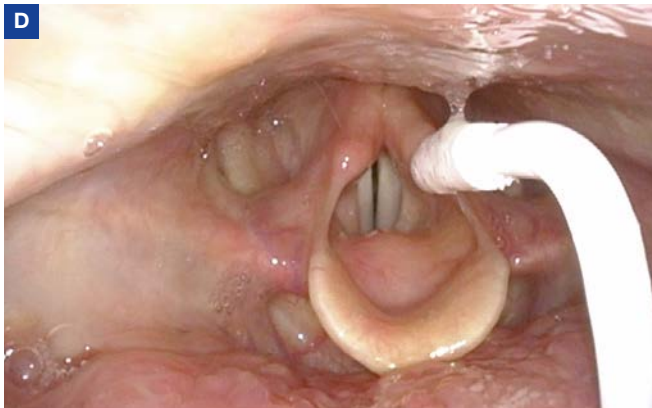Anesthetizing the larynx transorally with a bent spray nozzle (A).



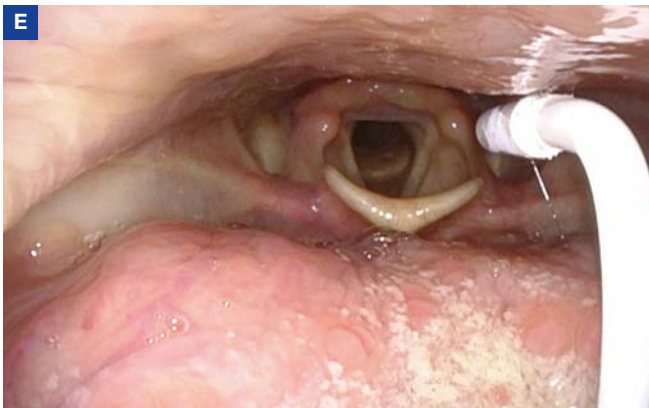Insert into mesopharynx (B),



lower tip behind the tip of the epiglottis (C), ask for long phonation of “eee” and spray during phonation (D). Avoid spraying into the trachea and causing any unnecessary tracheal burning sensation (E).



D) Spray while patient is phonating “eee” ...



E) ... and not during respiration.





# ENDOSCOPY

## 4.1. Considerations Before Starting Endoscopy

- Criteria as to whether rigid or flexible endoscopy should be performed (see Table. 2.1, Table. 5.1):
- Pronounced gag response? Use flexible endoscopy.
  - What is the indication for laryngeal endoscopy examination:
    - ➔ Vocal fold mobility? Swallowing disorder? Subglottic or tracheal alterations? Use flexible endoscopy.
    - ➔ Tiny benign mass lesions? Rigid endoscopy might be considered.
  - General health condition and individual anatomy of patient (e.g. narrow nasal cavity, reduced jaw opening, the patient is lying flat)?
  - Is the patient able to cooperate?
  - What does the patient prefer?
  - Where possible it is often most helpful to use both techniques.

### Setting Up The Patient:

- Technique for administering local anesthetic: See chapter 3.
- Explain to the patient what you are about to do, what sensations are regularly encountered by patients and how the patient has to cooperate (how to breathe, how to sit, give a paper towel for saliva, use the tips that help limit an increased gag response (see chapter 6.2.))
- When performing rigid endoscopy, instruct the patient to breathe through the mouth!
- When performing flexible endoscopy, instruct the patient to breathe through the nose!

**Note:**

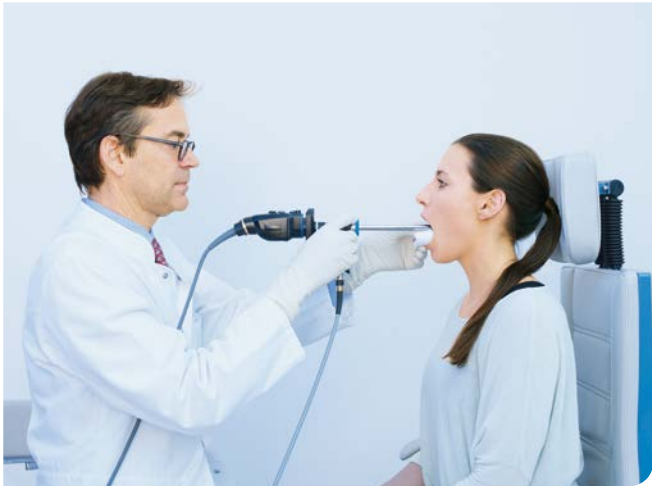
In the following chapters we show how endoscopists with a dominant right hand can perform the procedure. An endoscopist can of course perform the same procedure with their left hand.

## 4.2. Position of the Patient and Examiner

- There are various possible options when positioning the patient and examiner.
- In particular, when performing rigid endoscopy the angle of the endoscope and the chosen position determines what you will see.
- Various criteria should be considered:
  - The position of the patient (sitting or lying)
  - The instrumentation (flexible or rigid endoscope, handling preferences, type of camera)
  - Ensure comfortable examination body level
  - Does the patient have a pronounced gag reflex?
  - Are there features of special interest around the anterior commissure or posterior larynx?
  - The expected duration of the examination
  - For more: See Tips and Tricks/Special Positioning of Endoscope or Patient (chapter 6.4.)

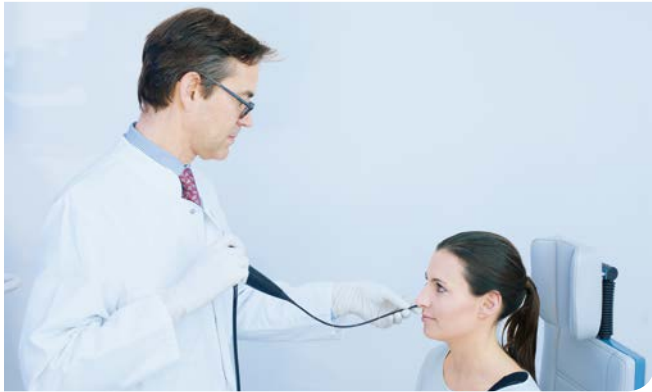Patient	Examiner
Sitting	Standing opposite the patient
	(Standing behind the patient)
	Sitting higher than the patient
	Sitting at the same level as the patient
	Sitting lower than the patient
Standing	Standing
	Sitting
Lying	Standing
	Sitting
	Standing at the head of the bed (rare cases)

Table 4.1: Possible variations of position of patient and examiner



Patient sitting, examiner sitting. Height of both chairs is adjustable, the head of the examiner is slightly higher.

- When choosing your position for examination ensure that the monitor is within easy line of sight - avoid extreme head rotation to either side for longer examinations.
- Adjust the height of both chairs – it is usually more comfortable for the examiner to sit in a slightly higher position than the patient.
- The examiner’s arms should be adducted during prolonged endoscopy procedures.
- The examiner’s elbows should be comfortably flexed.



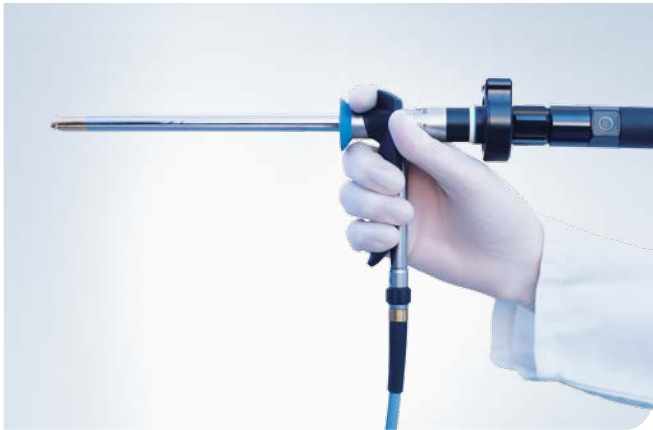
Patient sitting, examiner standing. Note that the examiner's left elbow is angled, his right arm adducted.



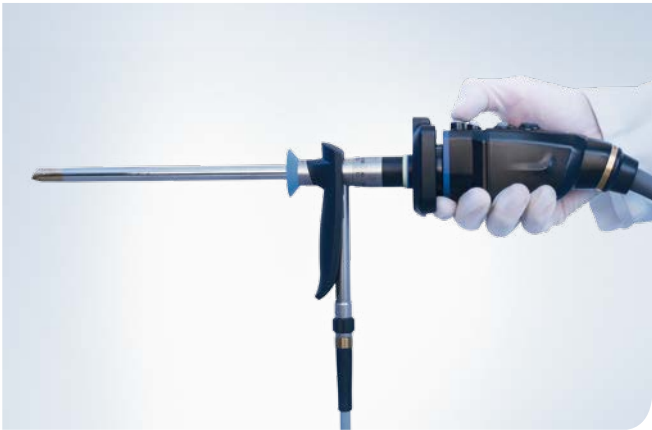Position of the Patient and Examiner: Rigid Endoscopy

- Rigid endoscopy with a 90° or with a 70° endoscope can be performed either from a standing or sitting position.
- In some countries, it is common for both the examiner and patient to sit.
- However, when using some cameras, it may be easier to stand while the patient remains seated.
- While seeking a particular view, it may be necessary to alter the normal positions for examination (see chapter 6.4.).

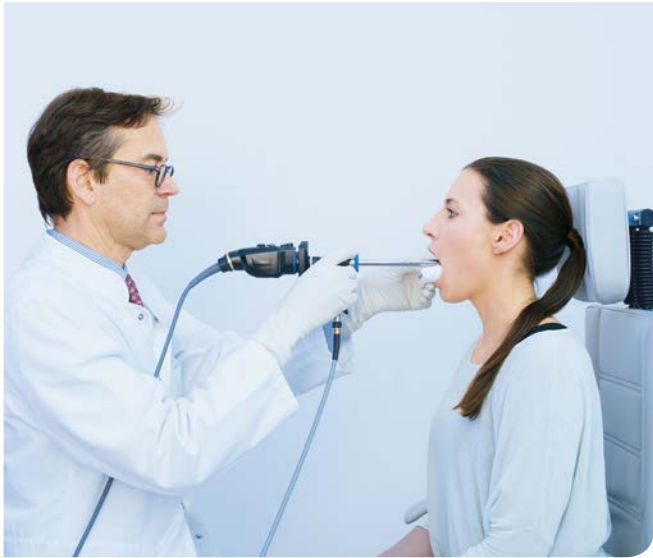The most comfortable position for the examiner will depend on the manner in which the endoscope is gripped:



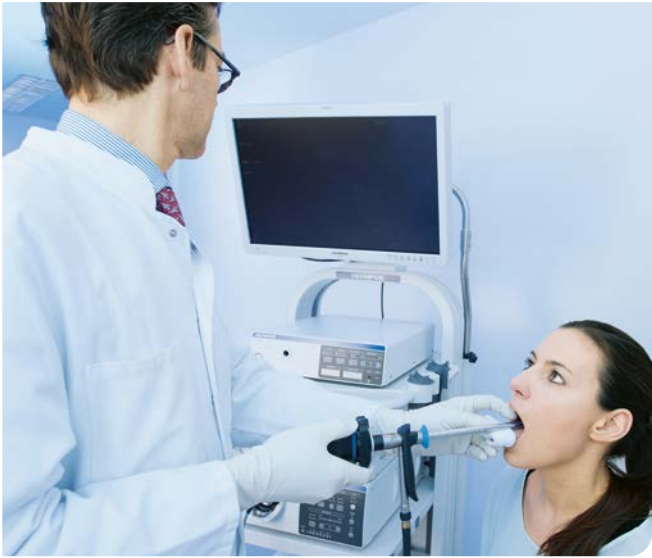
*Note that by holding the endoscope in this manner both sitting and standing are possible and convenient.*



*Gripping the camera as illustrated is easiest from a standing position.*



*Patient sitting, examiner sitting. Note the manner in which the endoscope is held from below.*



*Patient sitting, examiner standing. Note the manner in which the endoscope is held.*

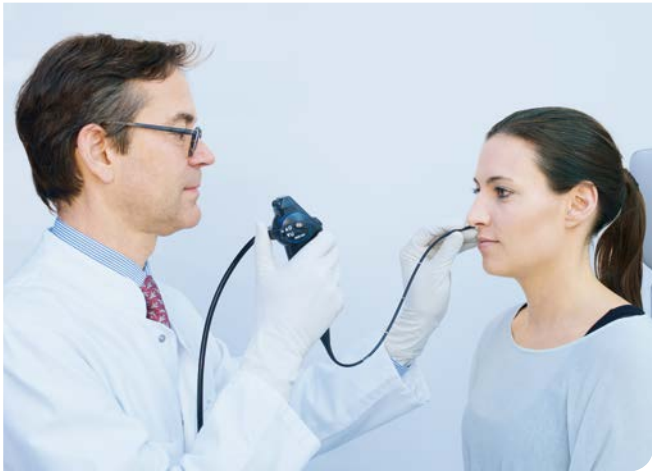Position of the Patient and Examiner: Flexible Endoscopy

- Examinations with flexible endoscopes can be performed while the examiner is either sitting or standing.
- Especially for longer procedures, e.g. examination of swallowing, it is sometimes more comfortable for the examiner to stand in order to reduce the strain on their arms.
- Another possibility for flexible endoscopy is to stand behind the patient so the examiner and patient can watch the monitor. We are not fond of this technique because the examiner cannot see the patient's face, and is therefore unable to check their reactions, e.g. an impending vagal response.

Patient sitting, examiner standing: Two alternative styles for grasping the endoscope's handpiece. Look at the levels of their heads: The head of the examiner is held in a slightly higher position than that of the patient.

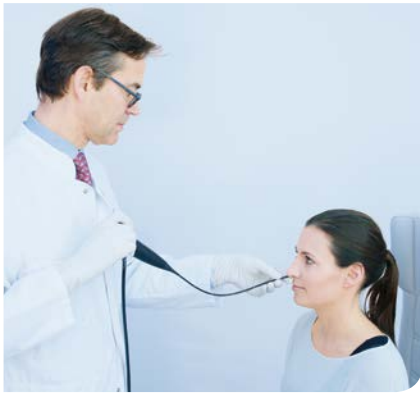

*A) Standard handling, right index finger controls tip deflection*

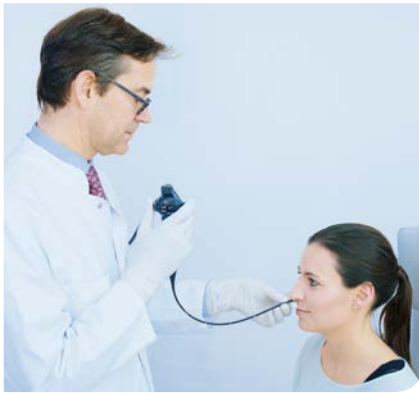

*B) Right thumb controls tip deflection in this examination.*

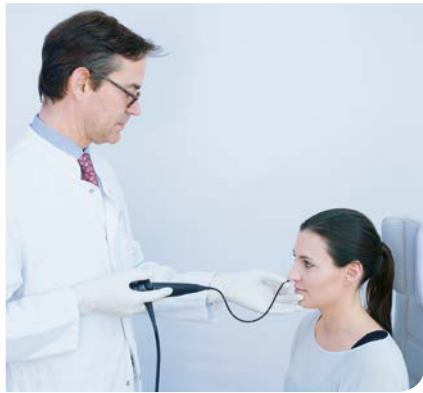
Patient sitting, examiner standing: Three alternative ways to grasp the endoscope handpiece (see 2.4.3.)



*A) Standard grip, index finger controls tip deflection*



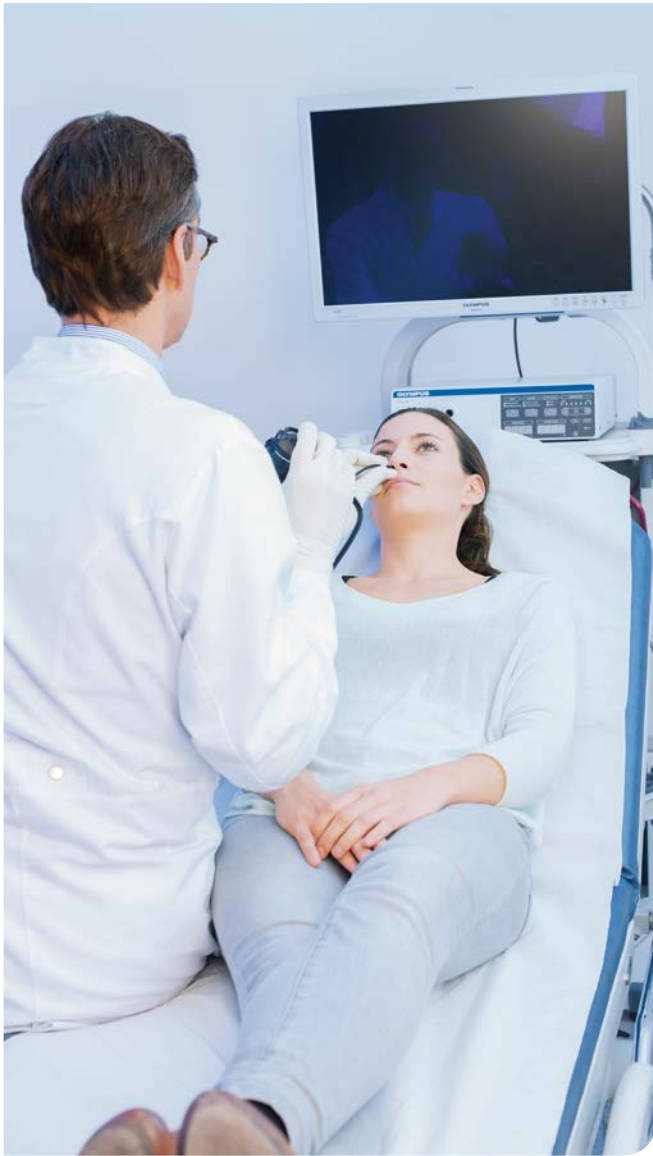*B) Endoscope rotated, thumb controls tip deflection*



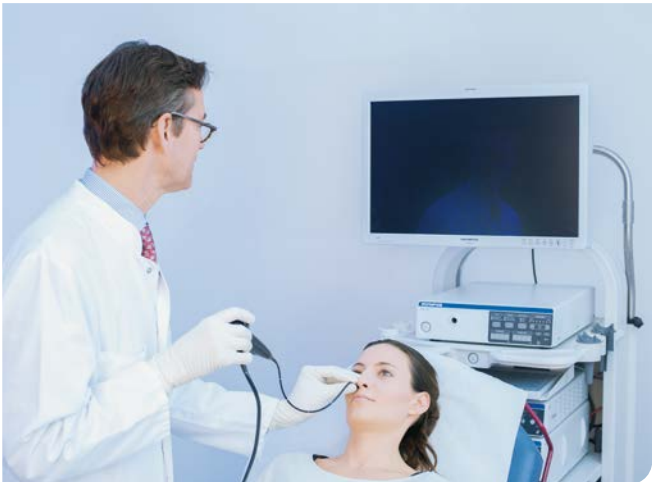*C) Endoscope held horizontally. This handling requires examination in a standing position.*

The Patient in Supine Position

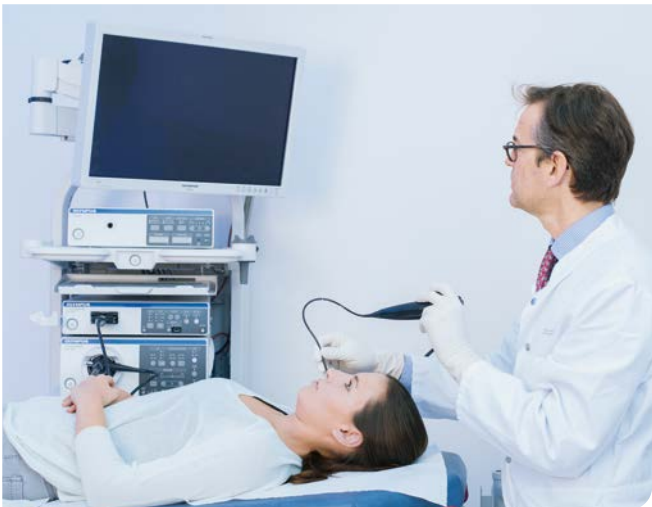
- Flexible endoscopy is more ergonomic and thus easier to perform than rigid endoscopy when the patient is lying in a supine or semirecumbent position.
- The examiner may sit or stand as appropriate, using whichever position is the most comfortable.



The semirecumbent patient with the examiner sitting on the edge of the bed. This arrangement is helpful when the bed is so wide that the examiner has to bend sideways in order to reach the patient.



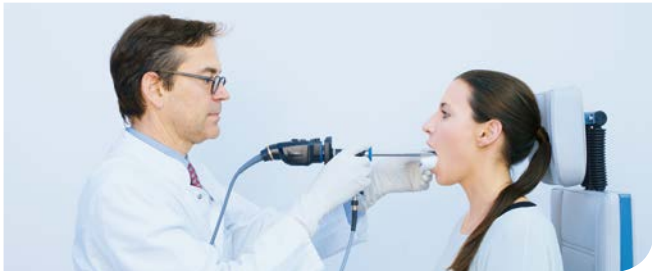The semirecumbent patient with the examiner standing. This is a convenient position for the examination of swallowing. The examiner can watch both the patient and monitor easily.



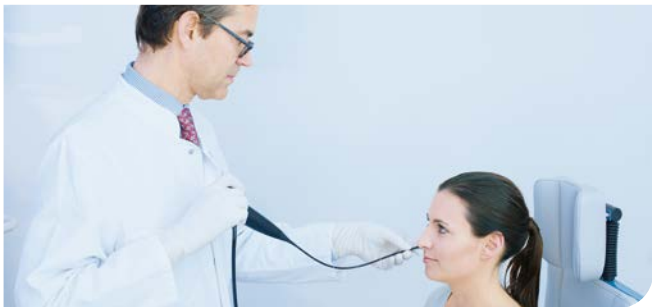
When the patient is lying supine, the examiner may sit at the head end of the bed. In this position it may be helpful to rotate the endoscope and use the thumb to control the tip deflection. Note the repositioned monitor.

Posture of Examiner – How to Do It

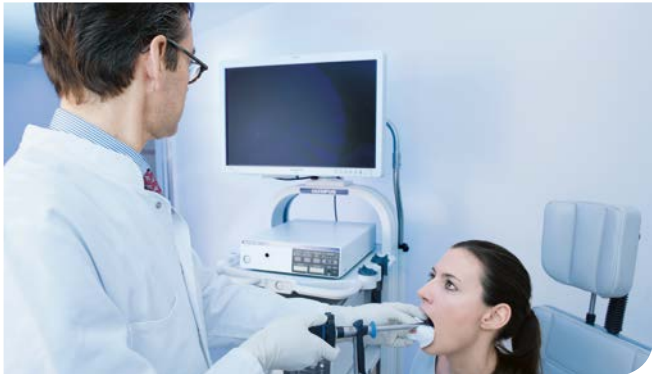- For both rigid and flexible endoscopy it is important to find a neutral, comfortable (i.e. not tiring) position, especially for the arms, head, and back.
- The examiner's elbows should not be abducted, nor held any higher than necessary.
- The examiner's arms should be adducted during long endoscopy exams.
- During protracted examinations, standing may be a more comfortable option for the examiner.
- The distance between the examiner and patient should not be so great as to prevent the examiner from sitting or standing upright with a straight back and neck.
- Make sure that the monitor is positioned so that the examiner can see the screen and the patient with a minimal amount of head turning.



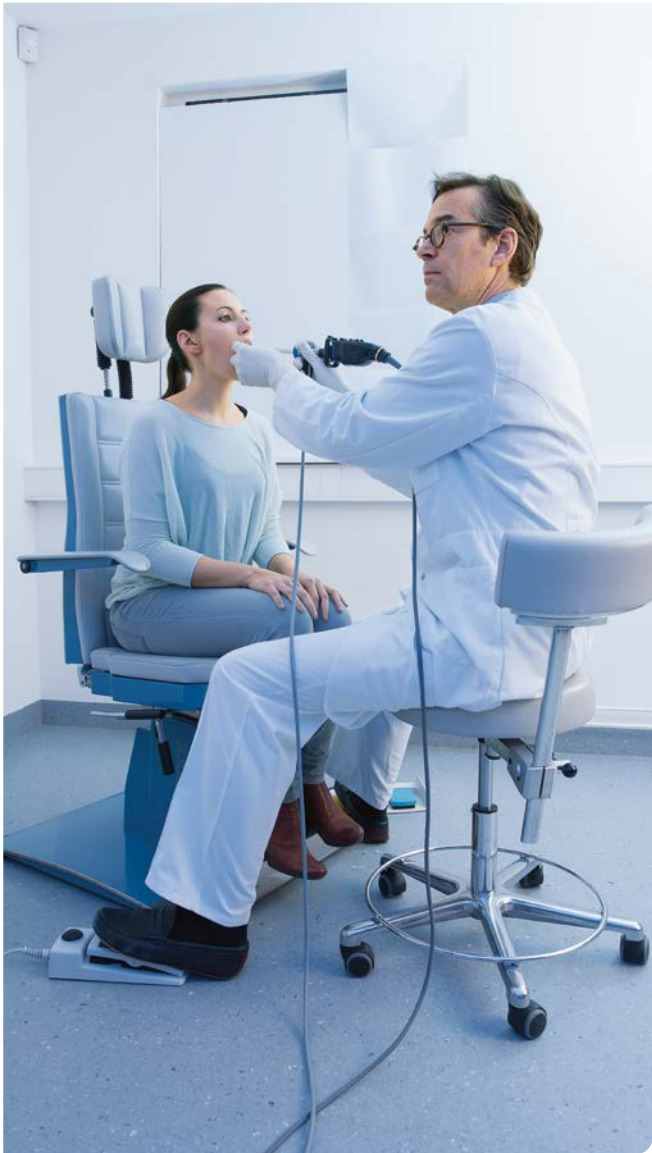Example of good ergonomic posture. The examiner has a straight back and his arms in a low, elbows-in position.



Note the examiner's left elbow is angled and the distal part of the flexible endoscope is not straightened. The examiner's right arm should be relaxed with the elbow dropped towards the body during protracted endoscopy exams.



Make sure that you can see the monitor and the patient with a minimal amount of head turning.

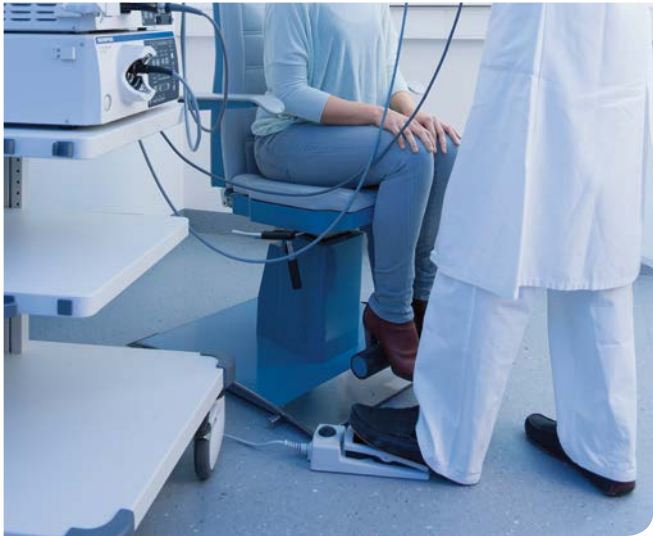

Note the examiner sits up straight. The distance between the patient and examiner should be reasonably short, as shown here.

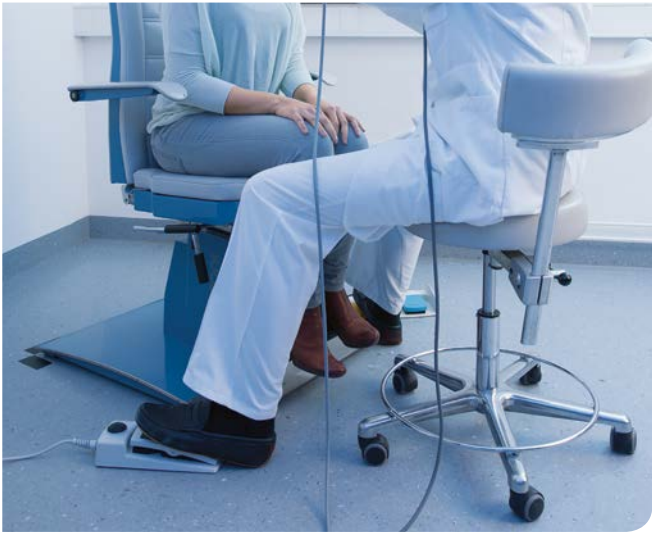


Position of Examiner's Legs and Feet

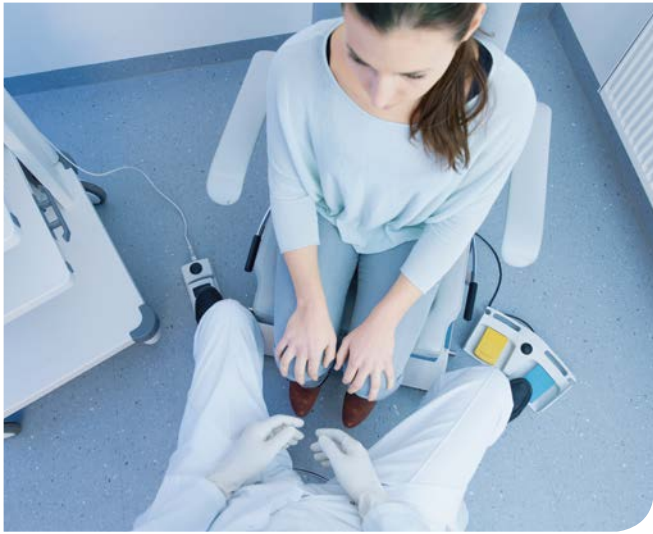- Foot pedals may be required during some examinations in order to operate recording, stroboscopy, laser, etc.
- Be prepared to reach all necessary foot pedals.
- Sit or stand up straight.
- Avoid getting your feet tangled in cables.
- There are several options for where to place your feet when sitting opposite a patient. When using a foot pedal, the patient's knees should be facing the examiner, who can then arrange his own legs to the left or to either side of the patient's knees.
- Check that the distance between examiner and patient is small enough to permit both to sit upright.



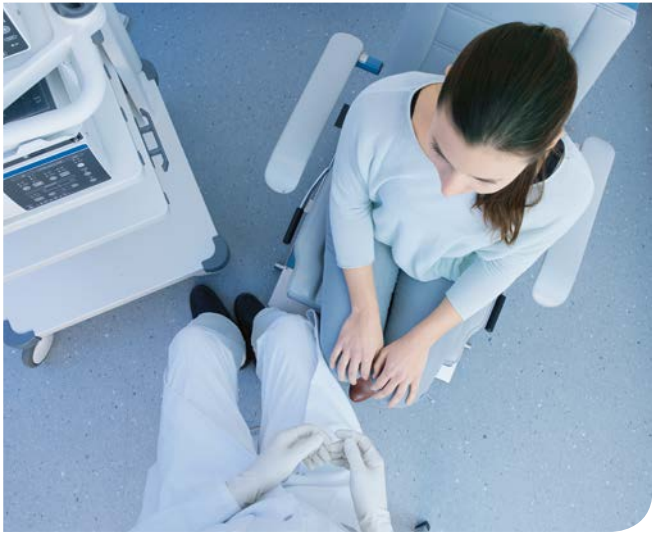Check the position of the standing and free leg



Check how easy it is to reach all the necessary foot pedals. Try to avoid getting the feet tangled in stray cables.



Position of the examiner's legs on either side of the patient's knees.

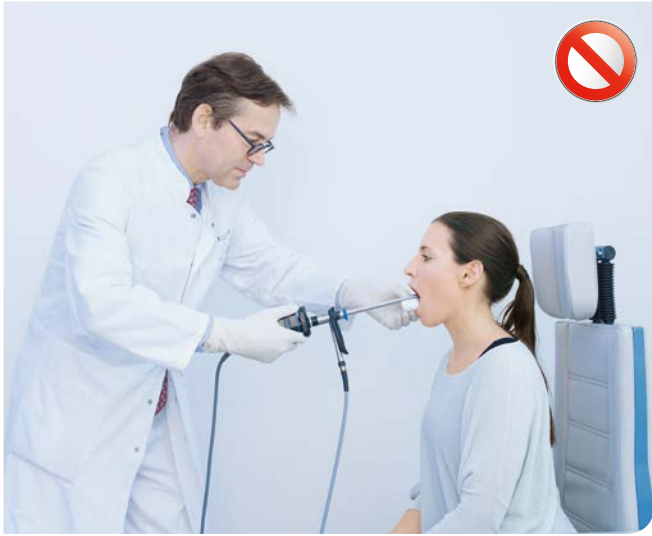


Position of the examiner's legs to one side. Both are turned towards the monitor.

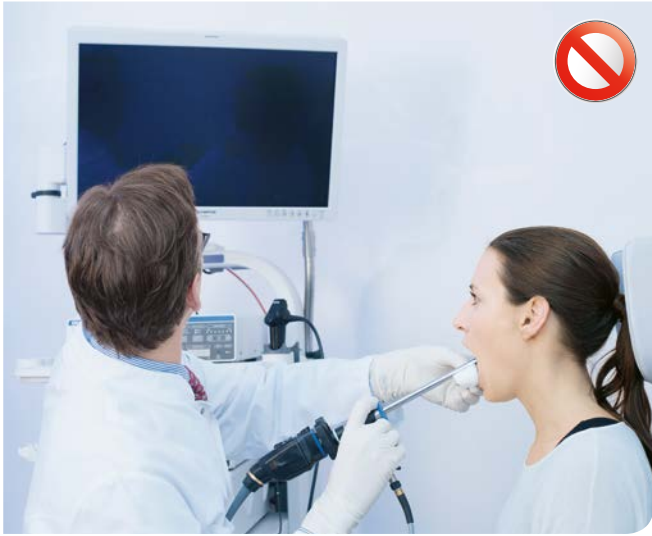Examiner – How NOT to Do It

Example of nonergonomic posture:

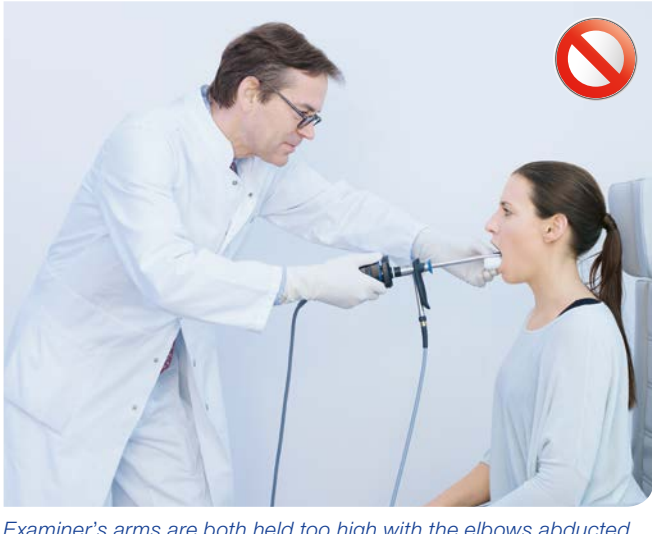
- Note the bent back and arms held high and abducted.
- Note the distance between the examiner and the patient.
- Also note the wide angular change in direction required to view either the patient or the monitor.



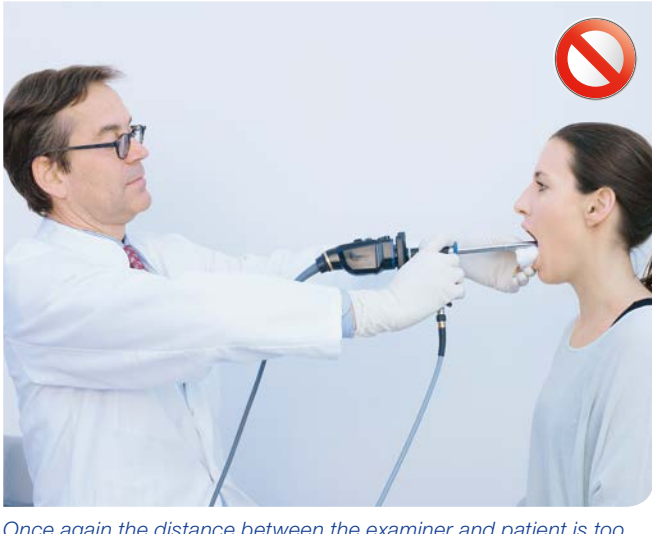
The distance between the examiner and patient is too great, causing unnecessary forward bending of the examiner's back and neck.



Poor location of the monitor demands considerable and unnecessary head turning.



Examiner's arms are both held too high with the elbows abducted.



Once again the distance between the examiner and patient is too great, despite the back and neck not being bent. Both arms are abducted and too high.



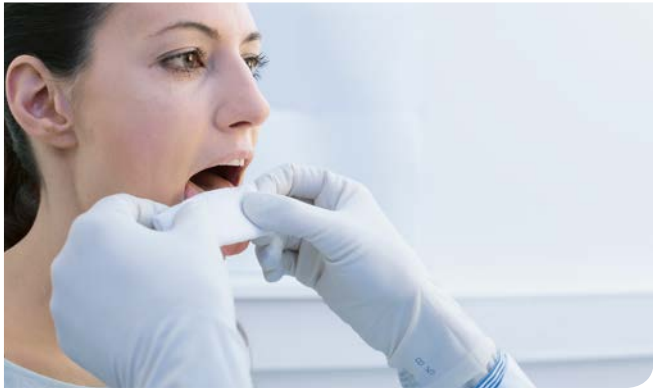
4.3. Transoral Rigid Laryngoscopy – Handling the Endoscope

4.3.1. Left Hand: Holding the Patient’s Tongue

- We recommend the use of gloves when holding the patient’s tongue.
- Ask the patient to stick out their tongue. Grip the tongue tip by placing your thumb on the superior surface and the middle finger underneath.
- Be careful not to hurt the patient by pressing the tongue against the lower incisors or by pulling too much.
- Keep finger contact with the patient’s cheek or chin using either your left index or little finger in order to control the position of the patient’s head.
- There are various ways to use the left index finger.
- Use a cotton gauze square rather than paper as it has better gripping properties.



Ask the patient to stick out their tongue



Start by wrapping the tip of the tongue with a gauze square.



The left index finger can be placed and used in a variety of ways. Here it is under the tongue and holding the tongue.



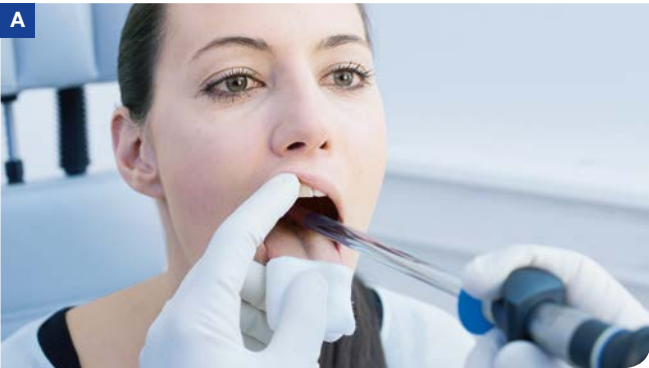
Here the left index finger is touching the patient’s cheek, thus enabling some control of the patient’s head position. The thumb is on the upper side of the tongue, with the middle finger underneath.



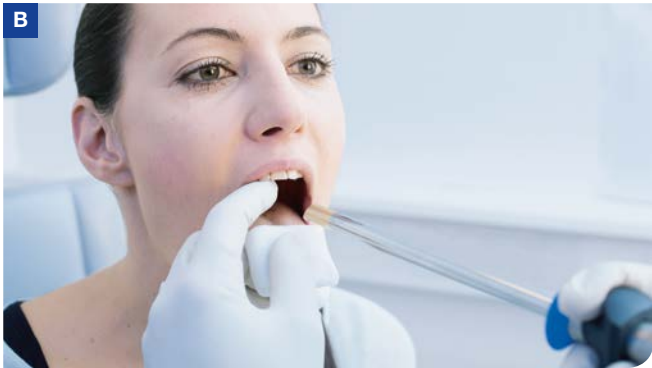Sometimes it is easier when the patient holds the own tongue, especially during indirect phonosurgery.

Use of the Left Hand While Inserting the Endoscope

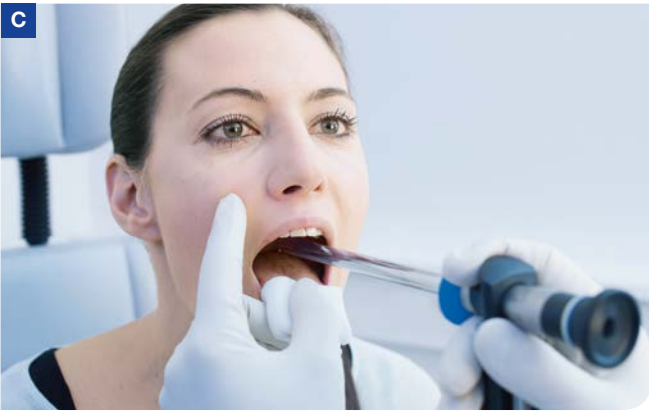
- There are various ways in which the left hand can be used while inserting the endoscope into the oral cavity.
- You can control the position of the patient’s head (A, B, C) and their mouth opening (A, B) with your left index finger.
- You can also control the position of the patient’s head by using your little finger to lift the patient’s chin (D, F).
- Additionally, you can stabilize the position of the endoscope with your left index finger (D, E, F).



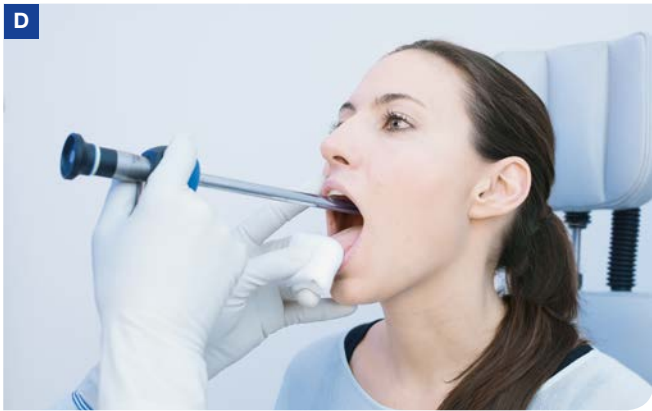A) Variation: Left index finger lifts the upper lip



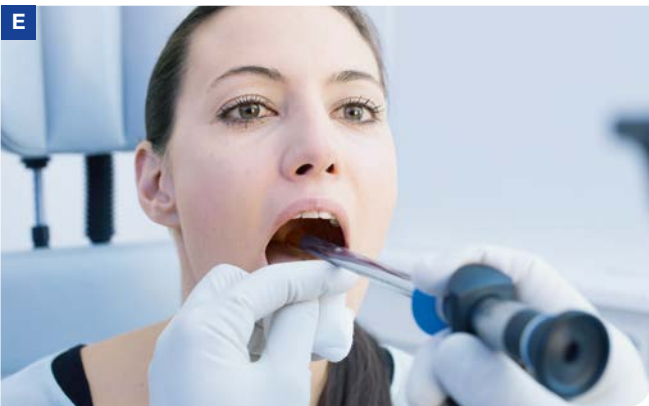
B) Variation: Left index finger beneath the upper teeth



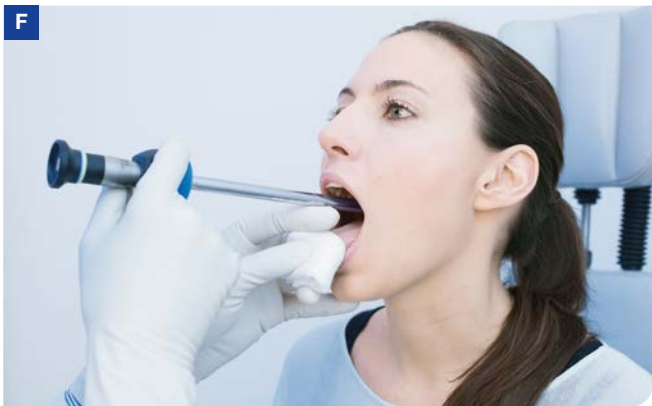C) Variation: Left index finger above the upper lip, directing the head's position



D) Variation: Left index finger above upper lip, directing head position, supported by the little finger under the patient’s chin. With this 3-point-grip you can “move” the head into any required position.



E) Variation: The endoscope rests on the left index finger

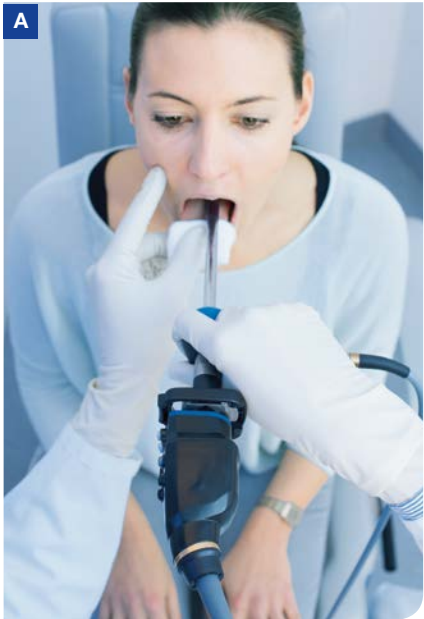


F) Variation: The endoscope rests on the left index finger, the little finger is under the chin directing head position.




4.3.2. Right Hand: Inserting the Endoscope

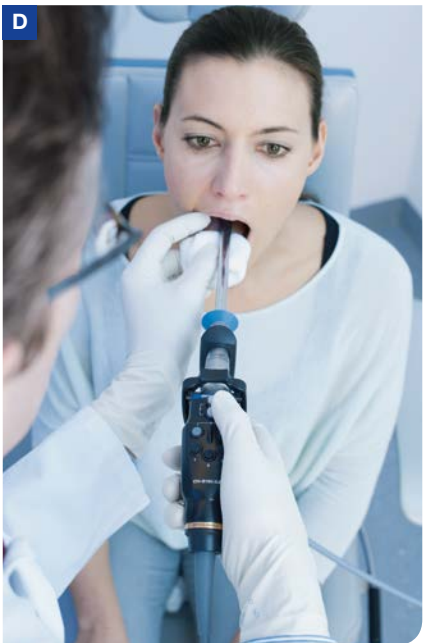
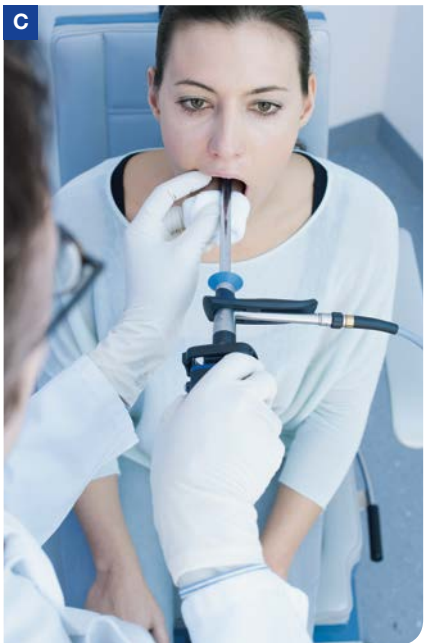
- The position of the right hand varies, depending on the different handgrips which can be used with the camera and endoscope.
- By rotating the endoscope sideways during intraoral passage you can avoid touching the tongue base and consequently blurring the lens. Simply rotate the endoscope downwards when its tip is behind the uvula.
- For special positions of the tip of the endoscope, see chapter 6.4.



A, C): Endoral passage



B, D): Tip of endoscope in oropharynx. Rotation downwards completed.



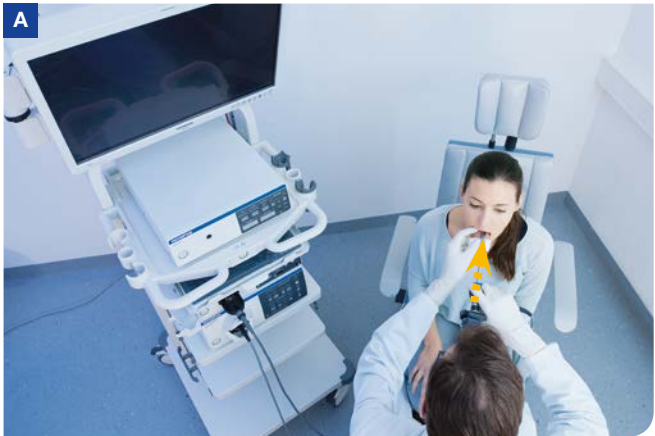A, B): Holding the endoscope from below, examiner sitting.

C, D): Holding the endoscope from above, examiner standing.

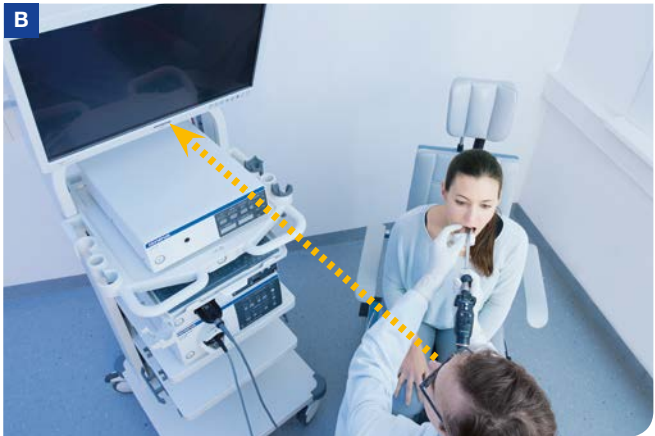
4.3.3. The Examiner's Head Position

When the endoscope has advanced through the oral cavity towards the oropharynx, the examiner has to change his direction of view from the patient's mouth to the monitor:

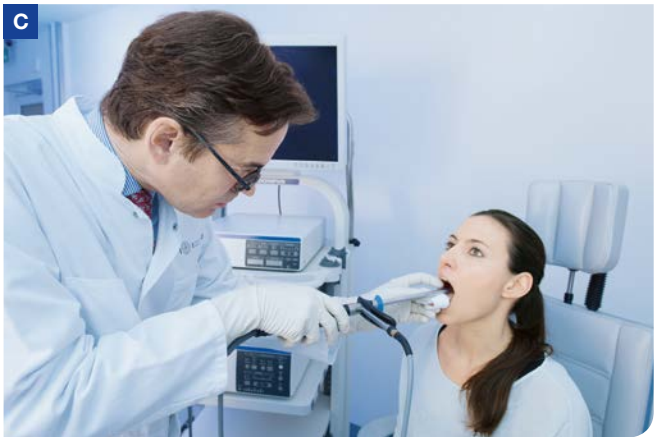
- While entering the mouth, the position of the endoscope, the elevation of the velum, and the opening of the oropharynx are controlled by looking into the patient's mouth.
- Ask the patient to breathe through the mouth.
- When the endoscope tip passes the uvula, i.e. the faucial pillars, the rest of the endoscopy is visualized on the monitor screen.
- Pay attention to the position of the monitor and the height of the chairs – you should be able to see both the patient's mouth and the monitor with a minimal amount of head turning.



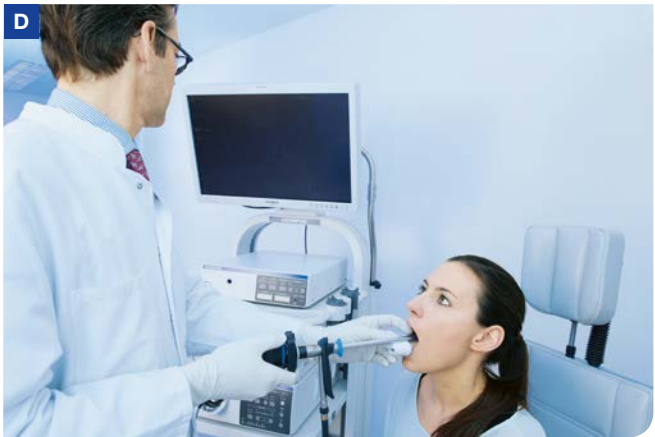
A) Examiner sitting; endoscope tip in oral cavity



B) Examiner sitting; endoscope tip passes the uvula, examiner turns head to monitor



C) Same as (A), but now examiner standing. Check position of endoscope by looking directly in the mouth.



D) Same as (B), but now examiner standing. After the endoscope tip passes the uvula continue to control the endoscopy via monitor

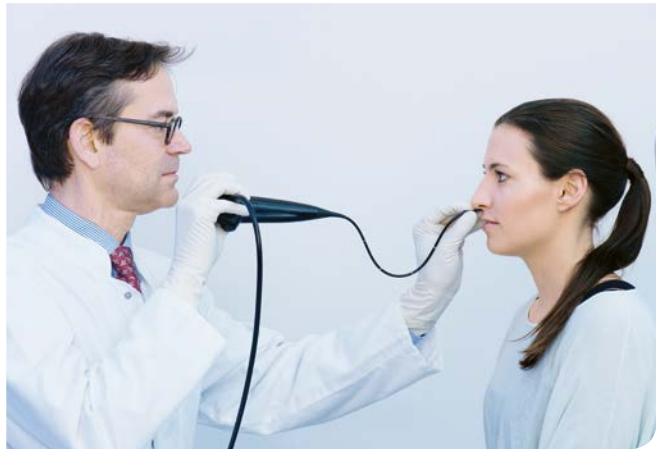A) Examiner sitting, C) Examiner standing. Intraoral passage: The endoscope is rotated to the side and the endoscopist is watching the patient.

B) Examiner sitting, D) Examiner standing. When the tip of the endoscope reaches the oropharynx, rotation backwards is completed and the endoscopist turns and continues the examination using the monitor image.

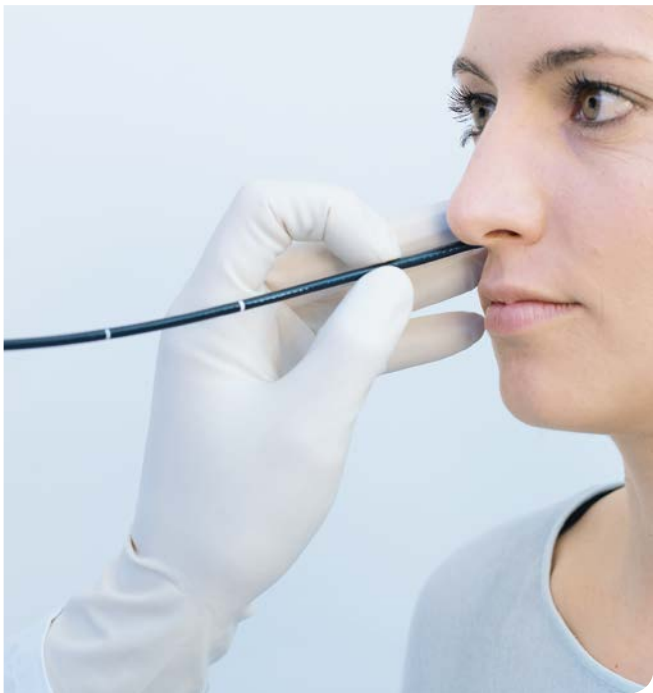4.4. Transnasal Flexible Laryngoscopy – Handling the Endoscope

4.4.1. Insertion of the Endoscope

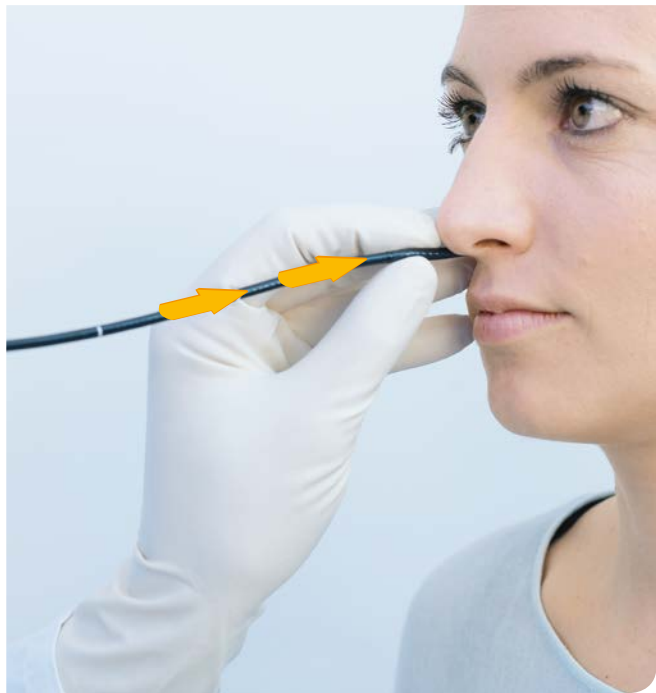- Insert the endoscope slowly and with permanent skin contact of the fingers of your left hand with the patient's nose or cheek. This helps prevent accidental displacement of the endoscope should the patient move unexpectedly.
- When the endoscope tip has passed the anterior nasal cavity, advance the endoscope slowly using just the thumb and index finger.
- Keep finger contact with the nose throughout the examination.
- Be careful not to hurt or to scare the patient with any sudden movements of the endoscope.
- When finishing the examination, withdraw the endoscope slowly and cautiously to avoid hurting the patient.
- During the examination, you should have slackened the flexible shaft of the endoscope into a siphon configuration (see chapter 2.4.3.).



*Keep contact with your fingers to the nose or cheek during the whole examination.*



*Check that both fingers are holding the endoscope before advancement. Then, push endoscope in.*



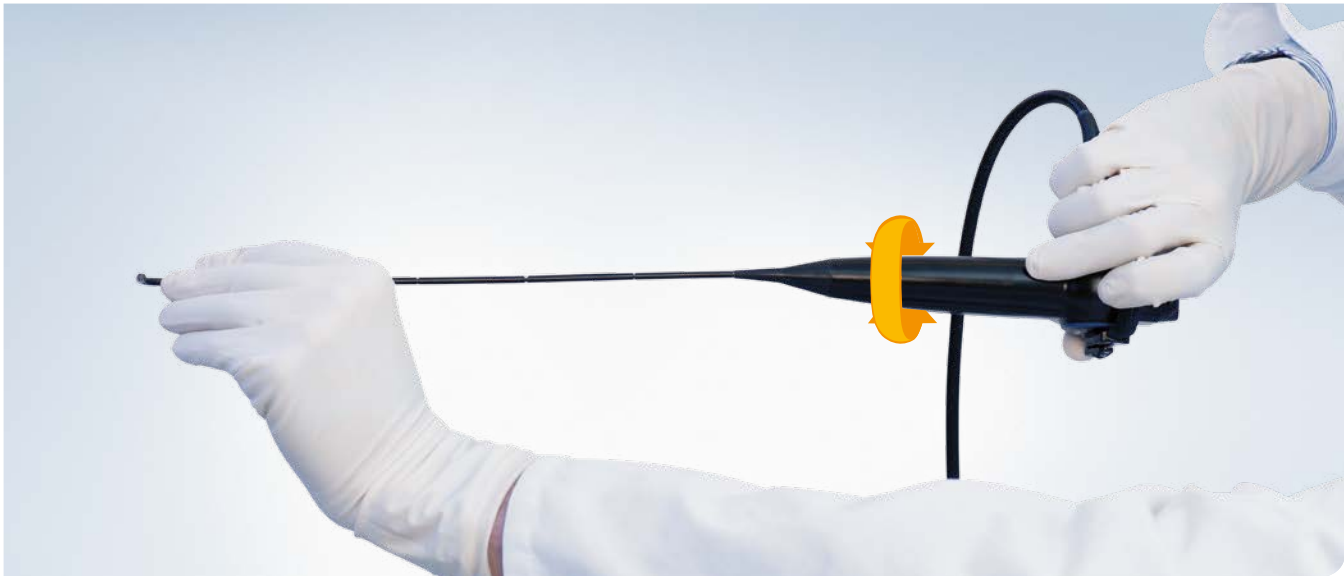*Advance the endoscope slowly and by moving only the thumb and index finger.*

4.4.2. Rotation of the Endoscope

- The flexible shaft of the endoscope should not be straight but bowed into a siphon configuration (see chapter 2.4.3.) so you can rotate the tip of the endoscope with the fingers of your left hand (A).
- Alternatively, you can rotate the tip by rotating the whole endoscope when the flexible shaft is held straight (B).



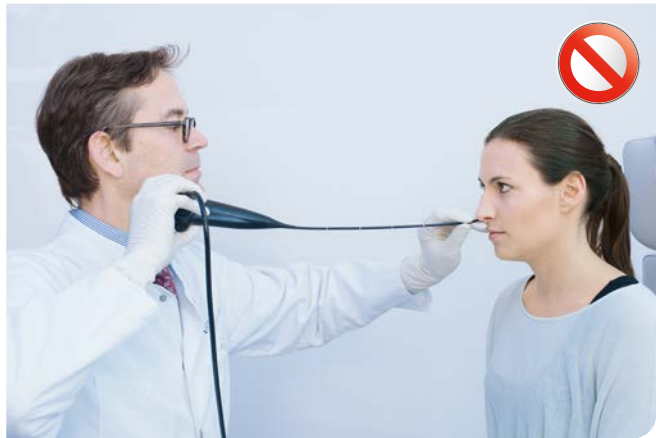*A) Having formed a siphon shape in the flexible shaft, it is now possible to rotate just the tip of the endoscope.*



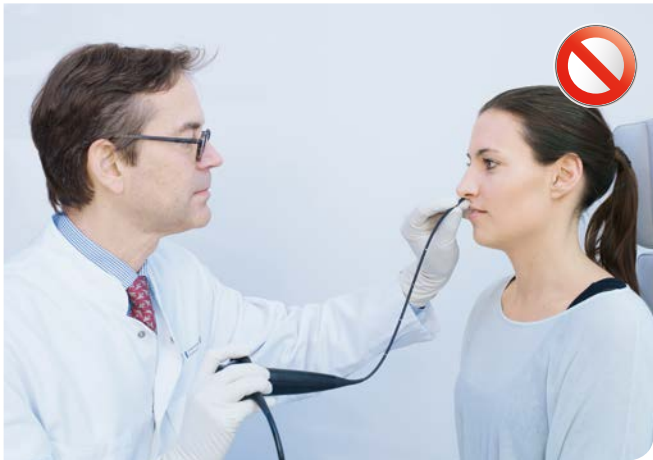*B) When the flexible shaft is fully extended, the tip can only be rotated by turning the whole endoscope.*



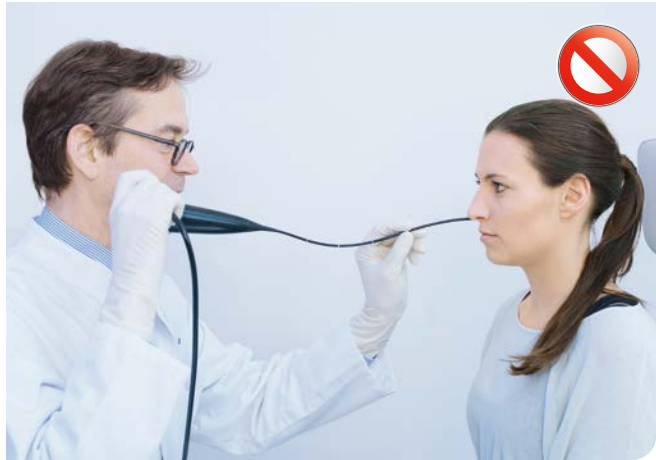4.4.3. Flexible Endoscopy – How NOT to Do It  
These are fairly common mistakes.



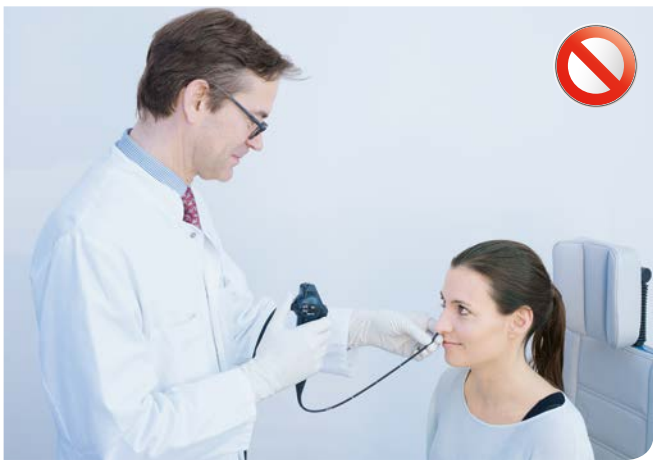
Right arm too high and the flexible part of the endoscope too straight.



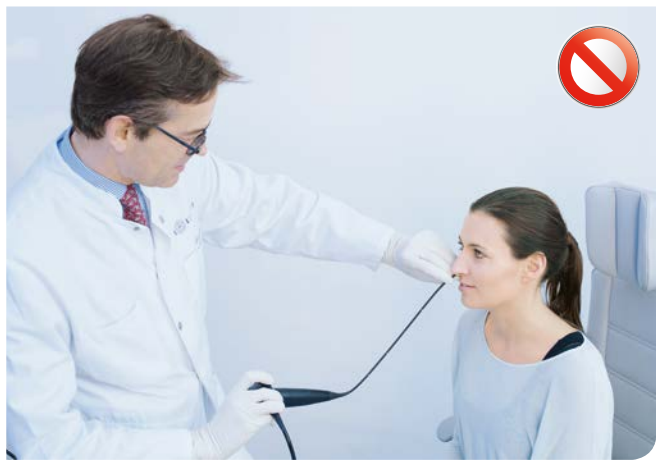
Examiner pulling down on the endoscope, thus straightening the flexible shaft.



No contact of left hand to nose or cheek of patient. When the patient suddenly comes forward, the endoscope might injure the nasal mucosa.



The tip of the endoscope is too high up. The position of the left hand does not allow the endoscope to be inserted with movements of the thumb and index finger.



Again, the position of the left hand does not permit insertion of the endoscope using movements of the thumb and index finger. Also note that the flexible part of the endoscope is too straight.

4.4.4. Transnasal Passage and Sequence of Endoscope Positions

- Before introducing the endoscope decide which side is more suitable for the nasal passage (e.g. by anterior rhinoscopy).
- The choice of side also depends on what you want to see. For instance, the contralateral vocal fold will mostly be exposed better (see chapter 6.4).
- For the patient the procedure is more convenient after anesthetization of the nasal cavity (see chapter 3.3.).
- In some cases decongestant spray is helpful.
- During transnasal endoscopy the nasal cavity, nasopharynx, velopharyngeal function, oro- and hypopharynx, and the larynx can be examined.
- For special indications different examination positions might be chosen.
- See Table 4.2: Useful maneuvers in flexible laryngoscopy depending on the position of the of endoscope tip.

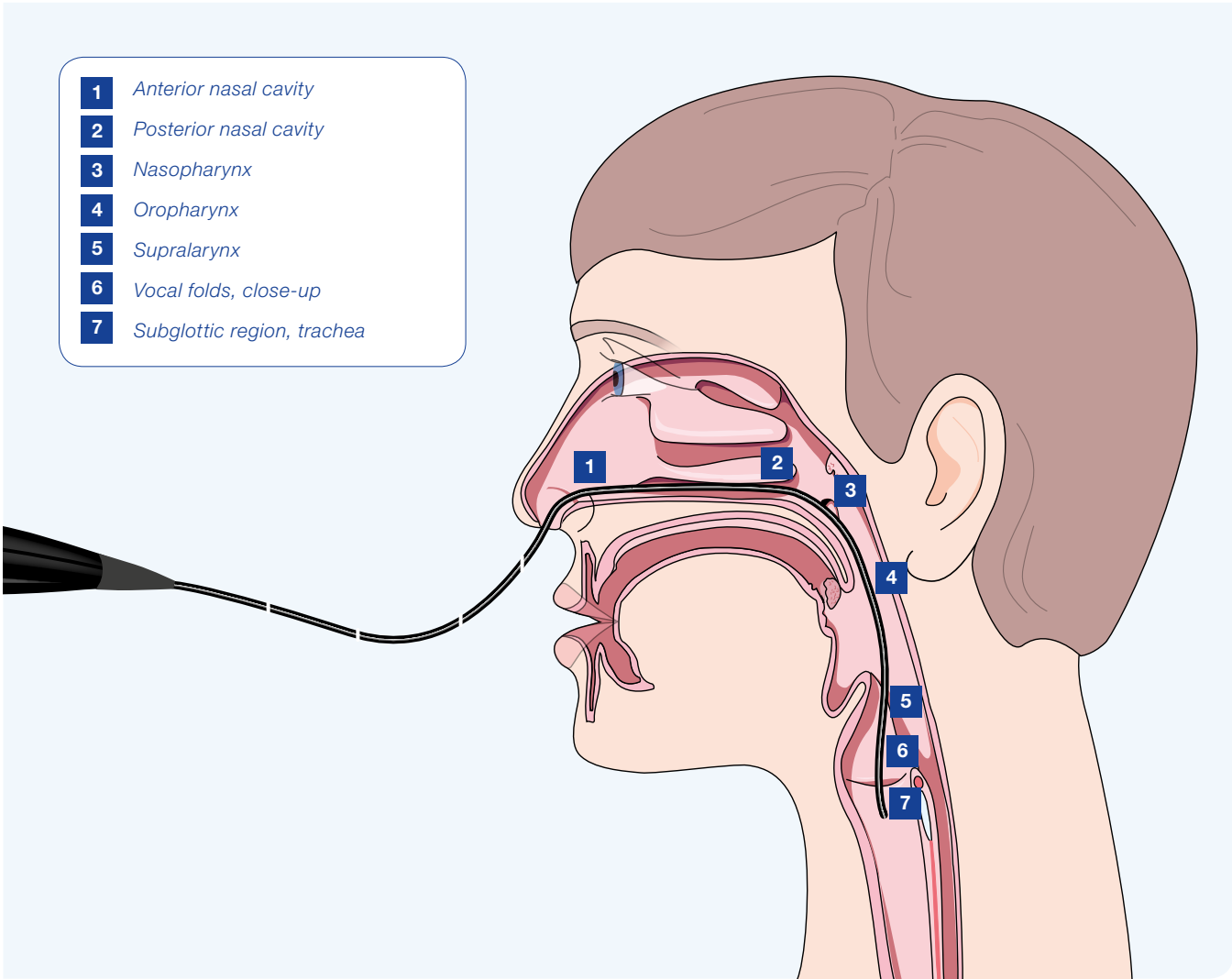
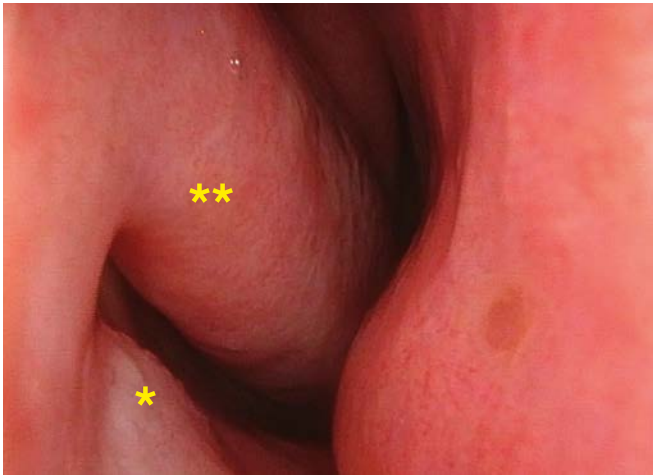


Fig. 4.1.: Transnasal passage of the flexible endoscope with important reference points (1–7)

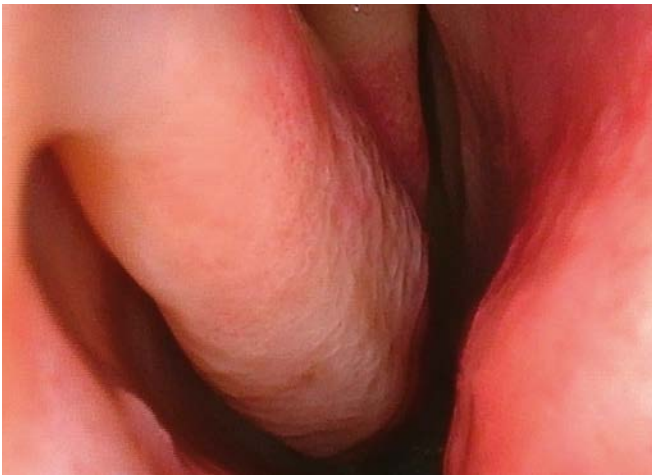Transnasal Passage: Nose and Nasopharynx

- Avoid advancing towards the septum – the mucosa of the turbinates will generally yield but the mucosa of the septum does not.
- Where the nasal cavity is narrow, try the middle meatus. The two turbinates will generally yield enough space to permit passage of the endoscope. Try the inferior meatal route only when this approach fails.

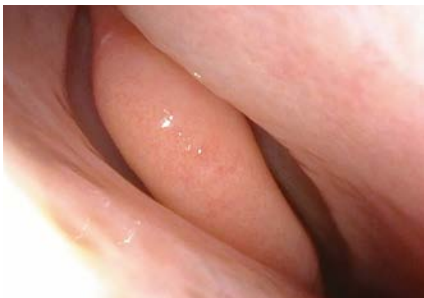Positions of the Endoscope Tip within the Nasal Cavity



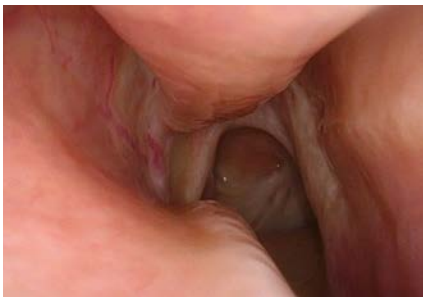Anterior nasal cavity, right side:  
See asterisk at inferior (\*) and middle (\*\*) turbinate  
In some cases decongestant spray is helpful. Here: Before ...



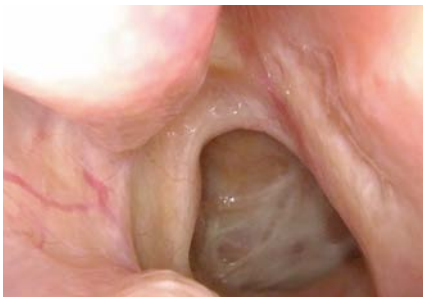... and after decongestant spray. Note the lumen enlargement.



Middle turbinate (right side)



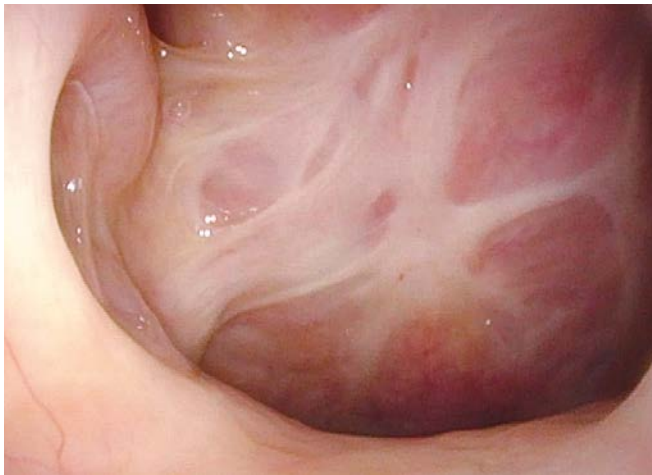
Meatus between inferior and middle turbinate (right side)



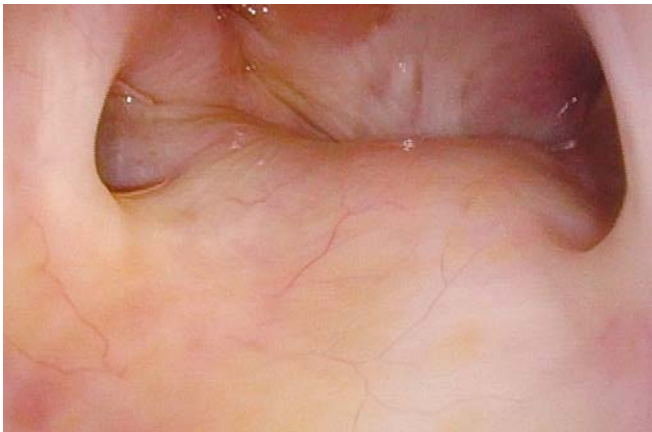
Posterior nasal cavity and nasopharynx

- When passing the endoscope into the nasopharynx, ask the patient to breathe through his nose so that the velum relaxes.
- When examining velopharyngeal function, ask the patient to swallow or to phonate e.g. “eee” or “coke”.

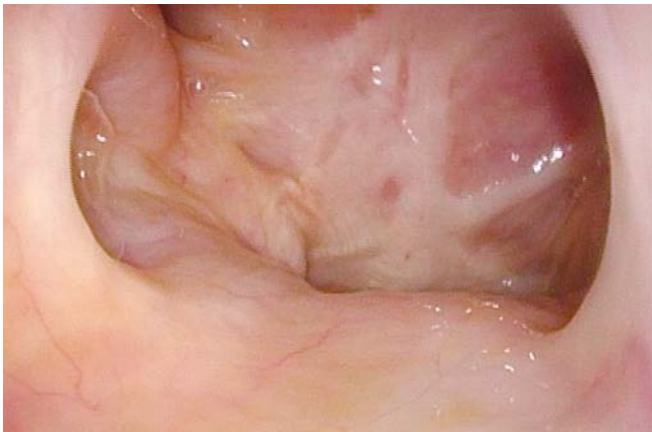
Positions of the Endoscope Tip within the Posterior Nasal Cavity



Velum, seen from above while breathing through the nose



Velum, seen from above, while articulating “coke”



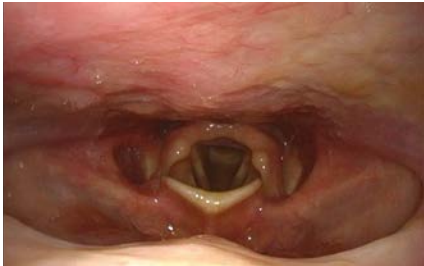Velum, seen from above, while swallowing



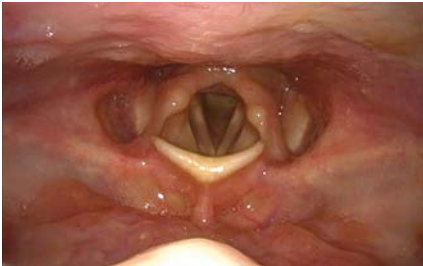Transnasal Passage: Oro- and Hypopharynx, Larynx, Trachea

- With flexible endoscopy it is possible to evaluate the vocal tract configuration during speaking, singing and special maneuvers.
- For assessing the morphology of the vocal folds it is recommended to position the tip of the endoscope very close to the glottis. It is often possible to pass the glottis and have a look at subglottis and trachea (see 4.5.1. Endolaryngeal Dipping Maneuver).
- In case subglottis and trachea are part of the clinical question anesthetize the larynx.

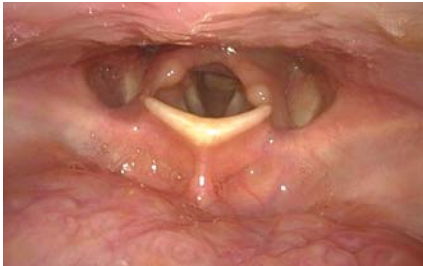Positions of Endoscope Tip within the Naso-, Oro-, and Hypopharynx and the Larynx



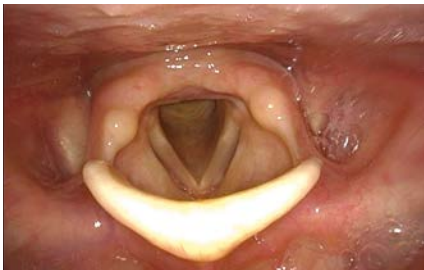Larynx with vocal tract, seen from nasopharynx.



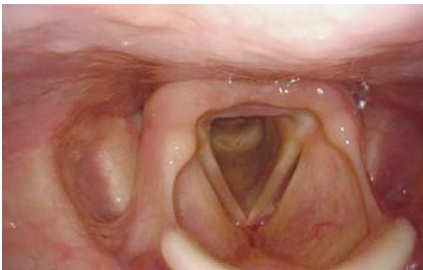Larynx seen from base of uvula level.



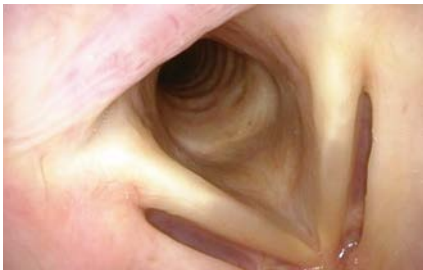Larynx seen from uvula tip level; the epiglottis typically covers the anterior glottic area.



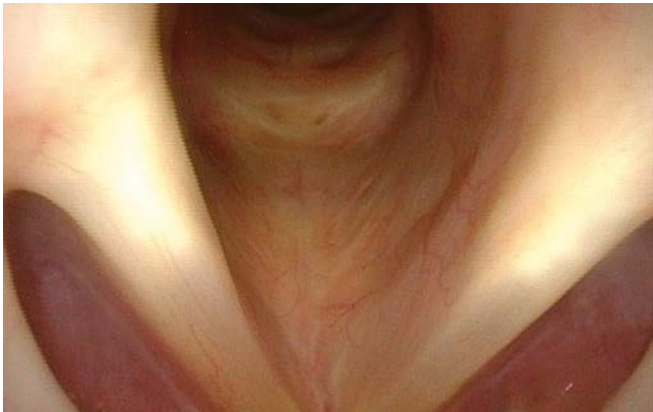Larynx seen from oropharyngeal level



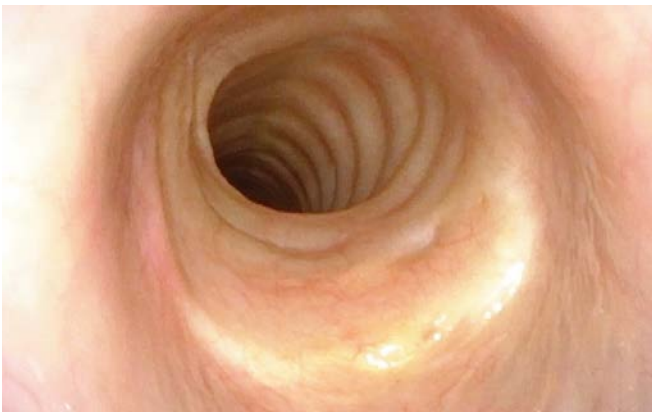Larynx seen from upper epiglottal level



Larynx with vocal folds, tip of endoscope next to the arytenoids



Larynx with vocal folds, tip of endoscope close to glottis



Passing the glottis enables a good view of subglottic region and upper trachea.

Numbers According to Reference Points (see Fig. 4.1.)	Position of Endoscope	Maneuver	Pay Special Attention to:
2, 3	Posterior nasal cavity above velum and nasopharynx	Breathe through nose	Spontaneous movements of velum and upper pharyngeal muscles; velopharyngeal distance
		Swallow	Velopharyngeal closure, regurgitation
		Articulation of e.g. “coke”	Velopharyngeal contact
4	Oropharynx	Breathing at rest	Spontaneous movements of lower pharyngeal and laryngeal muscles, acute signs of VCD, tremor, dystonia
		Repeated phonation of “eee” following by sniffing	Mobility of arytenoids
		Throat-clearing, coughing, laughing	Nonphonatory rapid movements, diadochokinesis of arytenoids
		Counting softly and with habitual loudness level	Vocal tract configuration
	Oro- and hypopharynx	Examination of swallowing	Intraoral control of bolus, pre-, intra-, and postdeglutitive laryngeal penetration/aspiration
4, 5, 6	Oro- and hypopharynx, larynx	Forced and rapid inspiration	Extent of edema Pedunculated lesions Stability of arytenoid complex
		Inspiratory phonation	Pliability of mucosa Extent of edema, pedunculated lesions
		Stroboscopy: 10 sec. “eee” with habitual loudness level and pitch	Phonatory involvement of mucosal wave, pliability of mucosa, regularity of vibration
6, 7	Position close to glottis or subglottis / in trachea	Long nasal inspiration (dipping maneuver)	Fine structures of vocal fold Morphology of Morgagni’s ventricle, anterior commissure, subglottis, trachea
7 (in case of tracheostomy)	Transstomal and intratracheal	Breathing at rest	Visualization of glottis transstomal Visualization of trachea Cannula-induced ulcers
		Phonation	Respiratory mobility
		Examination of swallowing with transstomal visualization	Aspiration (turn endoscope upwards to inspect glottis and downwards to inspect lower trachea)

Table 4.2.: Flexible laryngoscopy: Useful maneuvers depending on position of endoscope (see Fig. 4.1)



## 4.5. Special Maneuvers for Flexible Endoscopy

### 4.5.1. Endolaryngeal Dipping Maneuver

- Fine structures of the vocal folds can be evaluated best when the tip of the endoscope is advanced very close to the intralaryngeal target, almost touching the vocal folds.
- To avoid triggering gagging and cough reflexes, be careful not to touch any laryngeal structures.
- Experience shows that this close-up maneuver is most easily performed during long nasal inspiration.
- We recommend that the patient practices the breathing maneuvers prior to performing the so-called dipping maneuver.
- With this practice run, the patient learns to tolerate the endoscope and the endoscopist becomes acquainted with the patient's individual reactions.
- In order to achieve a longer inspiratory phase it can be helpful to increase the inspiratory resistance by closing the nasal ala not being examined with an endoscope using a finger of your distal hand.
- Alternatively, the patient can help by closing the unoccupied nasal ala himself / herself.
- Sometimes it is advisable to change the light source setting from automatic gain control (AGC) to manual gain control, or to use blue stroboscopy light to avoid overmodulation / "washout" under zoom conditions.

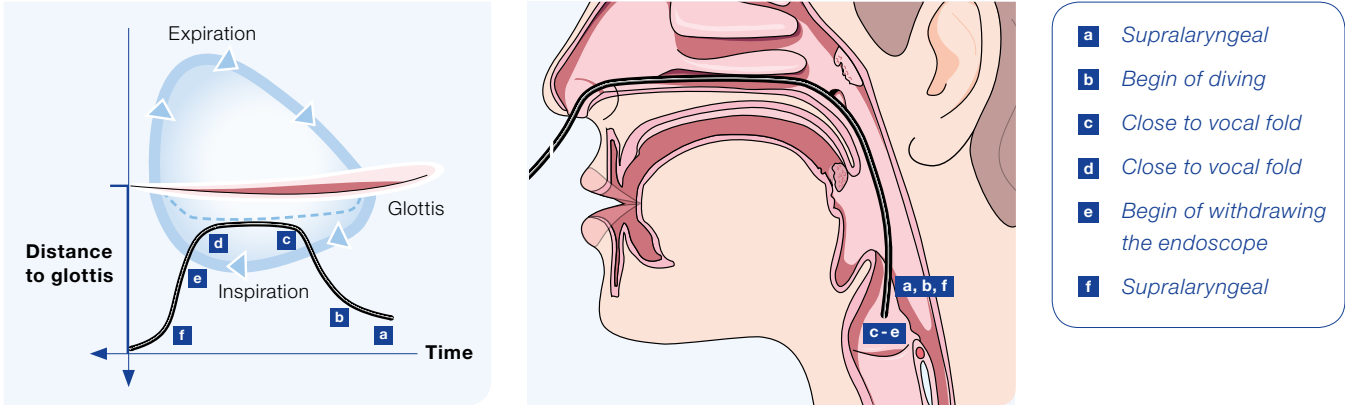
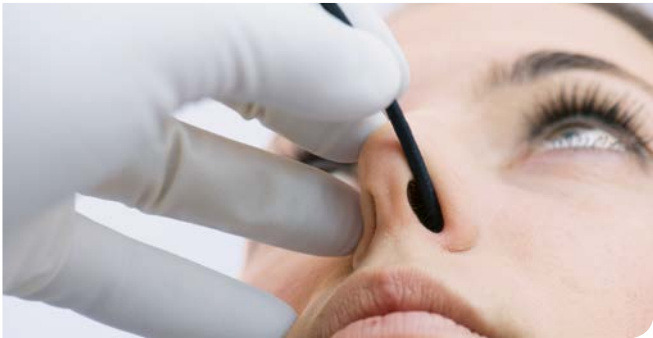
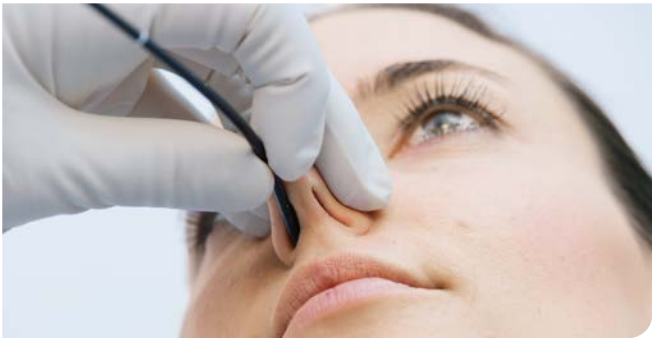
Fig. 4.2.: Combined scheme showing the timing of the "dipping" into the endolarynx. Because the maneuver depends on prolonged inspiration with high nasal airway resistance, we display the movements of the endoscope in relation to the inspiratory flow-volume loop (lower part of FVL).

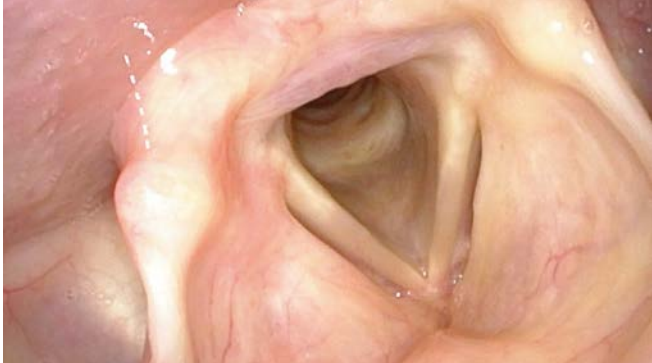Nasal inspiration is now intentionally prolonged due to the small lumen and high nasal airway resistance.



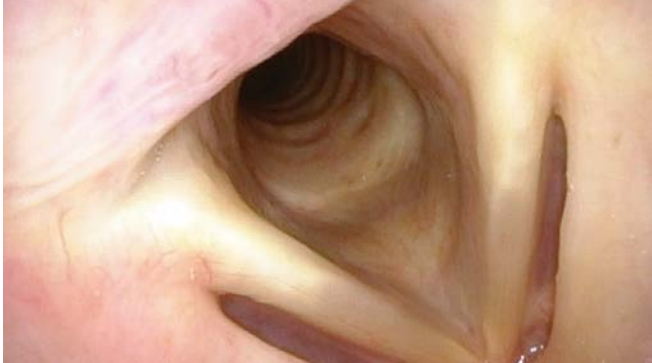Endoscopy through the left side of the nose; the finger of the left hand closes the right side of the nose.



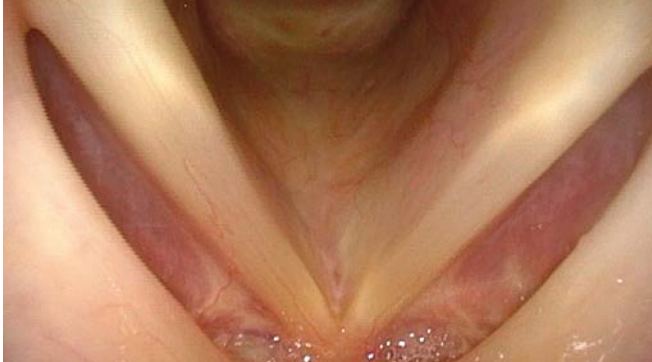Endoscopy through the right side of the nose; the finger of the left hand closes the left side of the nose.



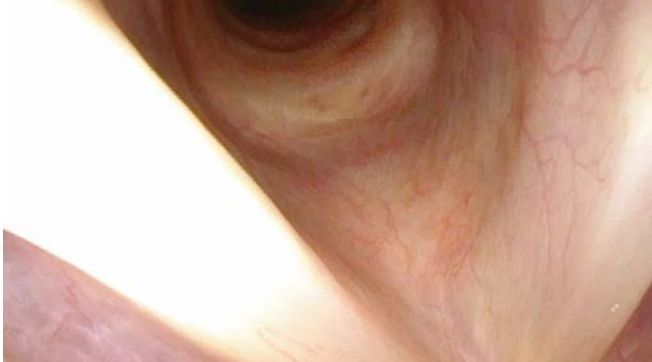Overview showing vocal folds and ventricular folds



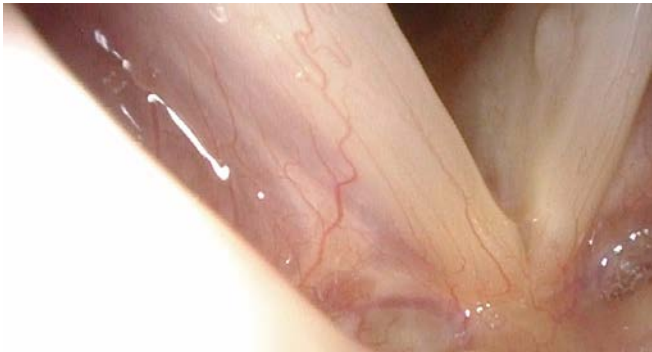
Closer view of glottis and Morgagni's ventricle



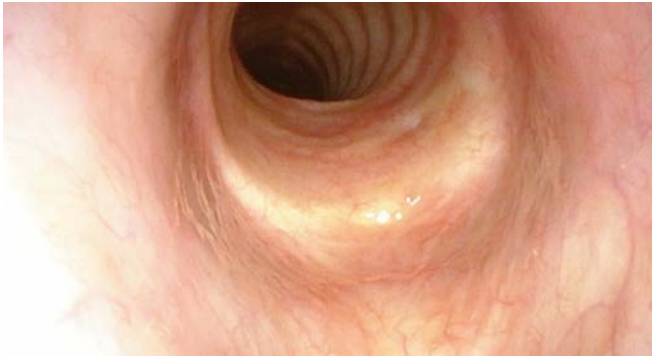
Morgagni's ventricle and anterior commissure



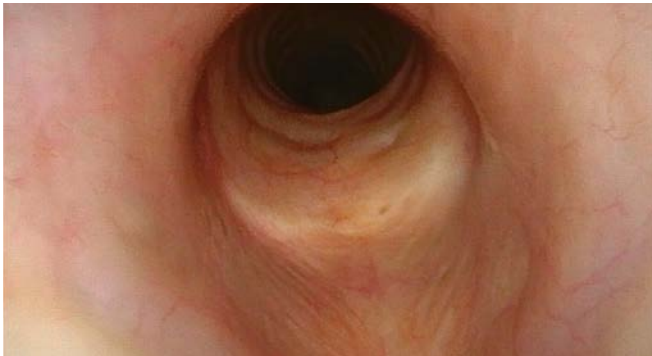Very close to posterior vocal fold – the tissue appears white where it is overmodulated; the region of interest is the anterior commissure (which is illuminated appropriately).



Close to vocal folds



Subglottic region

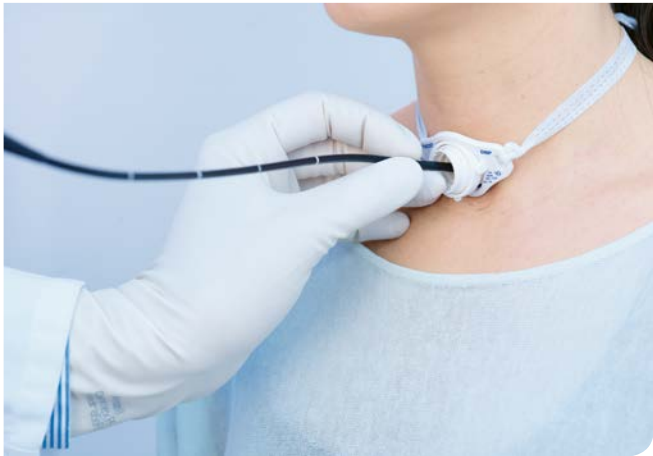

Passing the vocal folds: subglottis and trachea



4.5.2. Transstomal Flexible Endoscopy of Subglottis and Trachea

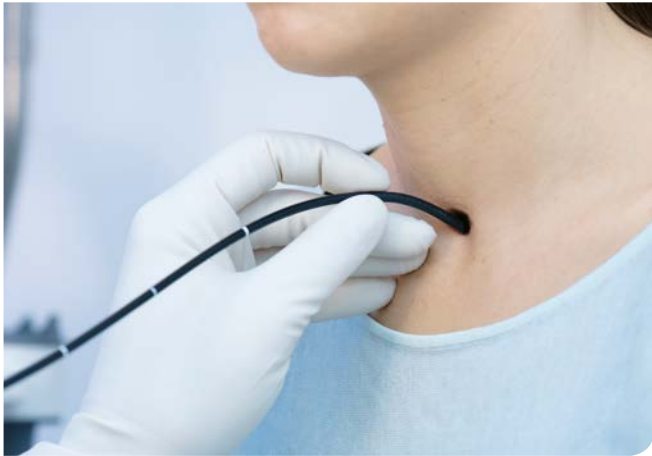- In patients with tracheostoma, transstomal flexible endoscopy is performed to visualize the trachea as well as the subglottis and glottis from an inferior approach.
- The lower trachea can be examined with or without cannula.
- Cannula-induced erosions, lacerations or ulcers of the tracheal mucosa are best seen without cannula, with the endoscope inside the cannula while pulling the cannula out simultaneously with the endoscope, or while reinserting it.
- For visualizing the subglottis and glottis, the tip of the endoscope has to be angled at approx. 90° upwards or more because of the tracheal-laryngeal curvature.
- Stabilize your distal hand next to the tracheostoma, avoid sudden movements, and avoid touching the trachea with the endoscope.
- Be prepared for the patient to cough! Ask the patient to shield the stoma with a gauze square.
- Do not insert a flexible endoscope through a speaking valve. The endoscope tip might be damaged when pulled out.



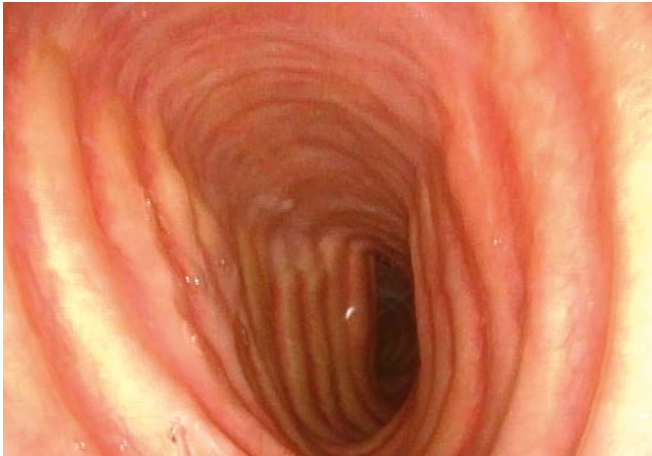Endoscope through tracheostoma with cannula. Stabilize the position of your distal hand by placing your fourth and fifth fingers next to the tracheostoma. Insert endoscope by moving thumb and index finger.



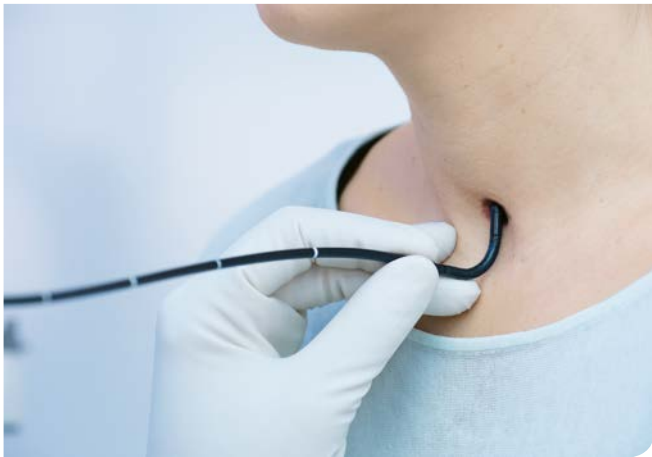Trachea seen through cannula



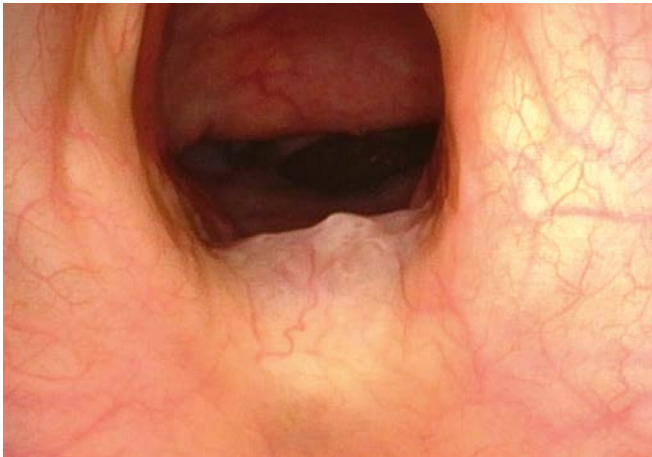
Tracheoscopy with endoscope through tracheostoma without cannula



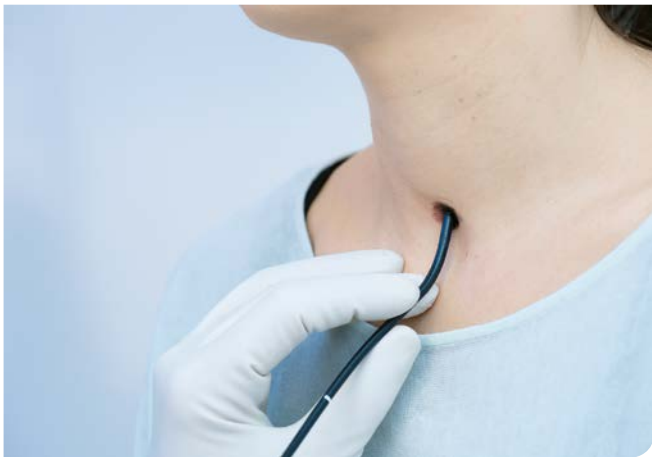Trachea seen through tracheostoma without cannula



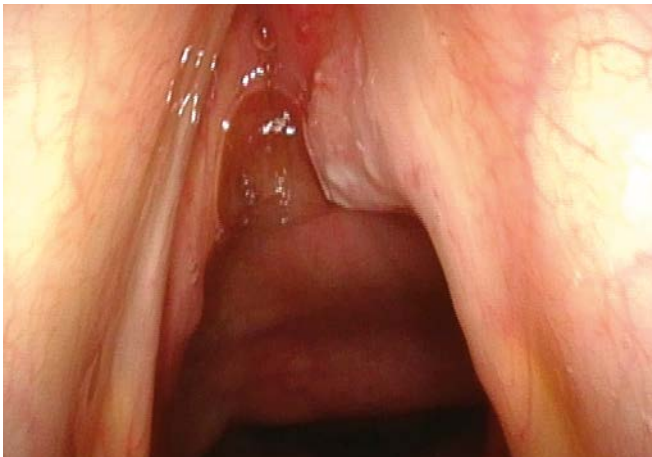Endoscope through tracheostoma without cannula, tip directed upwards.



Glottis seen from inferior through tracheostoma: The endoscope is not bent enough so the anterior part of the glottis cannot be seen.



For visualizing the anterior glottis: The tip of endoscope is angled and the endoscope is advanced from below. Avoid sudden movements, and avoid touching the trachea. Be prepared for the patient to cough!



Same patient as in preceding figures. Here, the glottis is shown again from inferior through the tracheostoma, but the endoscope was maximally bent so the anterior glottis can be seen now – and a tumor is visible on the left vocal fold.



4.5.3. Transnasal Flexible Endoscopic Examination of Swallowing (FEES)

- The oropharyngo-esophageal swallowing assessment is a complex procedure. Here we can only address a few aspects.
- FEES stands for fiberendoscopic examination of swallowing.
- Prior to any examination of swallowing, take the patient's history: Which problems occur while swallowing and what consistency of food / fluids does the patient feel is easiest to swallow? Which is the most problematic?
- Try the easier consistencies first.
- Evaluate the morphology and mobility of laryngeal and pharyngeal structures using normal flexible endoscopy prior to starting the FEES.
- Assess voice and test voluntary coughing before and after examination of swallowing.
- The patient should sit upright (as upright as possible even when FEES is being performed at the bedside).



Water coloration and thickening

Preparation for FEES

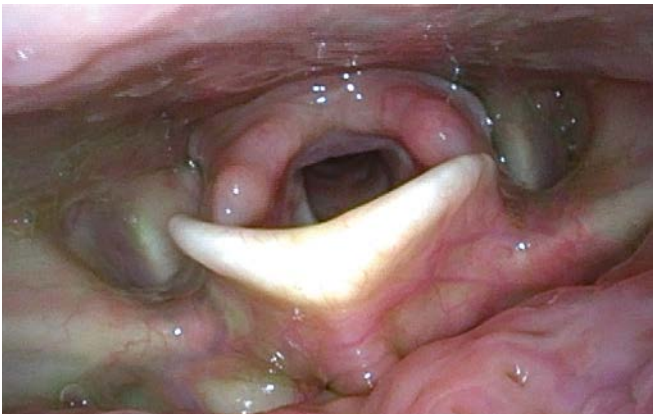Water coloration

- Green or blue food colorant provide the best contrast
- Use enough color dye to ensure vivid contrast of the mixture
- Special tip: use green colorant and NBI for High Sensitivity FEES (see next page)
- Protect the patient's clothes
- Also take care not to stain your own clothes and your fingers

Thickening of water:

- Decide which consistency you want to test
- Sometimes it makes sense to test with biscuit or other crumbly foodstuffs

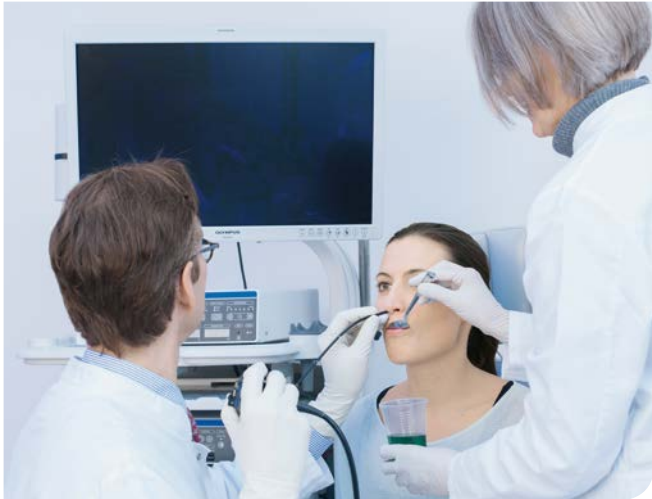Use a straw, spoon, or special feeding cup



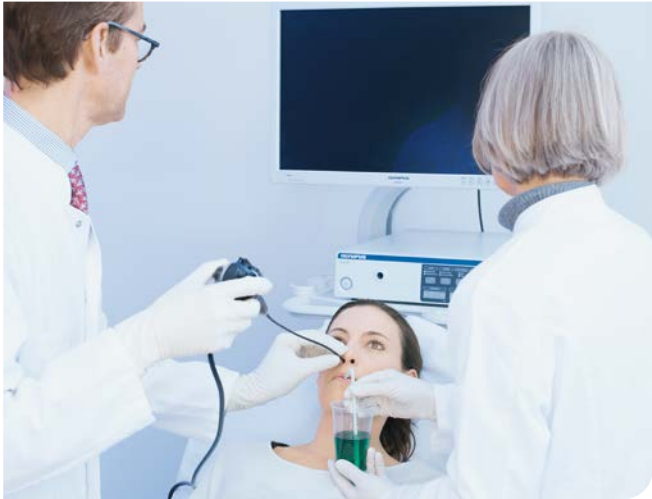On normal swallowing, the bolus disappears immediately and completely from all pharyngeal regions after one swallow.

Look For

- Intraoral control of bolus
- Drooling
- Leakage
- Retention
- Pooling
- Laryngeal penetration
- Aspiration
- Silent aspiration
- Pre-, intra-, and postdeglutitive aspiration
- Regurgitation



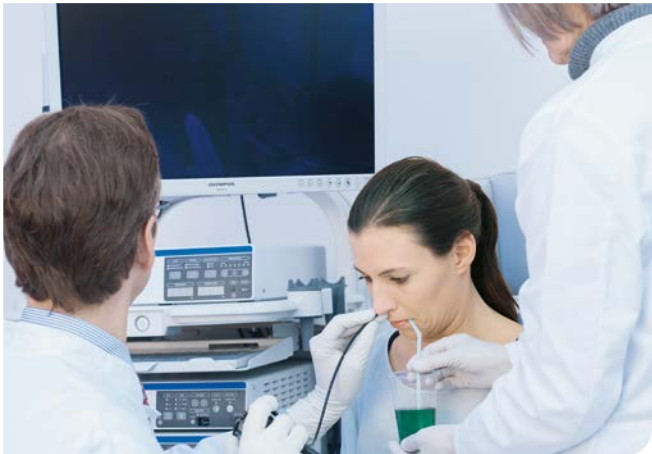
Give precise instructions to the patient and nurse. Sometimes fluids can be administered more easily with a spoon than with a straw. Pay attention to the size of the bolus.



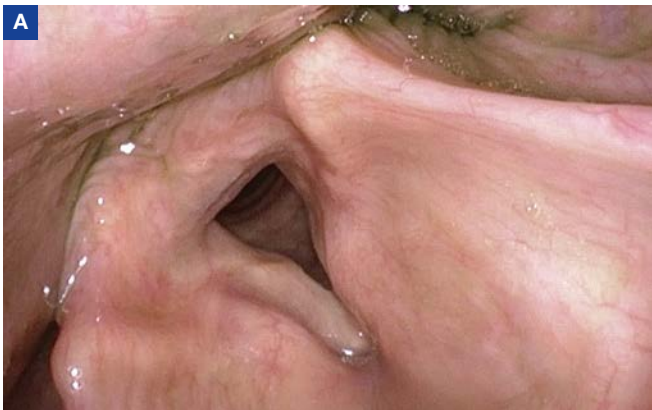Patient lying on a stretcher, upper part of the body as upright as possible



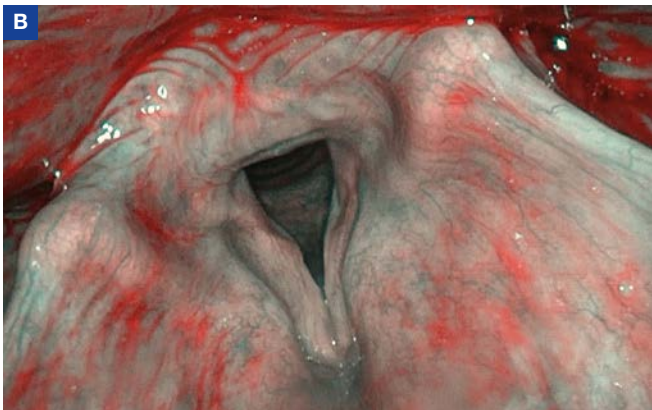
Therapeutic maneuvers can also be assessed during the endoscopy. Instruct the patient to take a bolus into the oral cavity and hold it there until asked to swallow. Then test the swallowing in various postures or maneuvers to establish which are the most helpful.



Here: Chin-tuck maneuver



A) Laryngeal penetration, shown with green colorant. One can hardly see the penetrated material because of insufficient contrast.

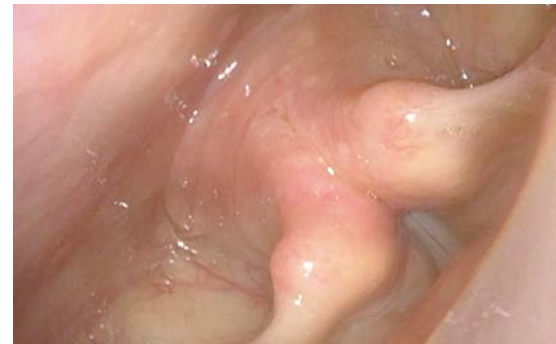

B) High Sensitivity FEES: Same situation as in A, one second later, but now with NBI illumination. The bolus is colored bright red with an enormous contrast enhancement that can be seen very well.

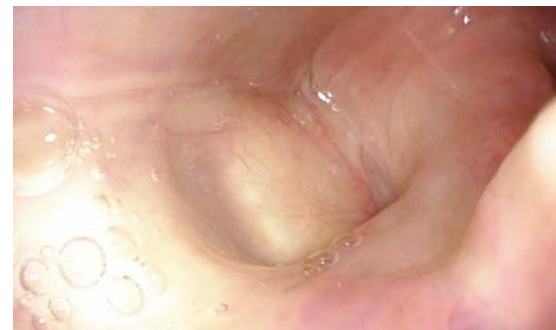


#### 4.5.4. Transnasal Flexible Esophagoscopy (TNE)

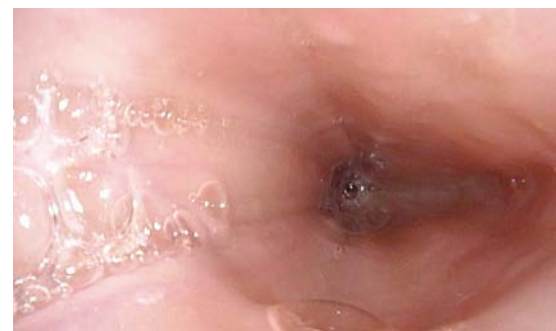- After performing flexible pharyngolaryngoscopy, it is possible to additionally perform a transnasal esophagoscopy of the upper esophagus to get an impression of its morphology and function.
- From our experience, anesthetization of the pharynx is not necessary.
- TNE can be most easily performed when the patient (while holding a deep breath) keeps on swallowing while the endoscope advances. It is recommended to ask the patient to drink a glass of water with a straw.
- Advance the endoscope actively towards the postcricoid region. Do not push the flexible endoscope into the esophagus, let it be pulled down while the patient is in the act of swallowing.
- Take advantage of the fact that during the pharyngo-esophageal phase of swallowing, the larynx is elevated and the upper esophageal sphincter opens. Within a split second, the sphincter closes while the larynx is still elevated. Thus, the sphincter grabs the endoscope tip and pulls it downwards when the larynx descends again.
- As an alternative, you can position the tip of the endoscope in the piriform sinus and let the patient swallow.
- The advancement of the endoscope from the pharynx to esophagus is very similar to the insertion of a nasogastral feeding tube.
- While the patient is repeatedly swallowing, visualization of the upper sphincter is not possible because of bubbling bolus and secretions.
- The inner esophagus is physiologically open, i.e. a lumen can be seen continuously. It is filled with air and aerosols are usually seen as tiny floating particles.
- Peristaltic movements are very slow and can be seen as superior-to-inferior constricting motions.



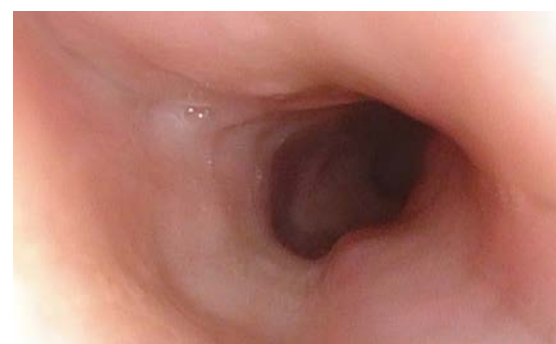*Endoscope superior to entrance of esophagus, waiting until patient swallows*



*Endoscope immediately before swallowing. Tip of endoscope moves slightly to the right*



*Endoscope in the esophagus*

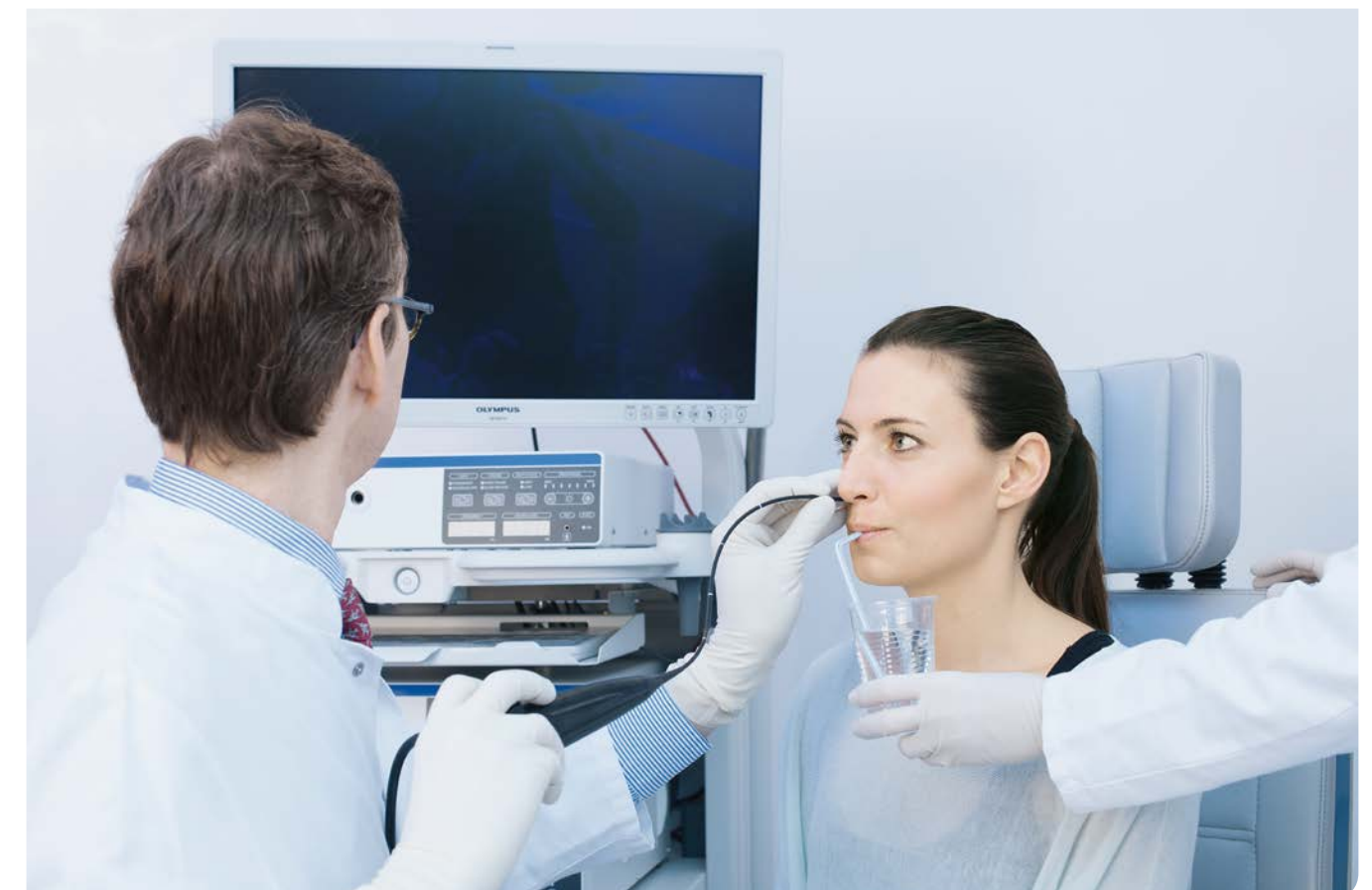


*Constant wide (normal) esophageal lumen*

#### TNE: How to Instruct Your Patient

##### Sequence of Endoscope Handling Movements and Instructions for the Patient:

- 1: "Breathe in and then hold your breath"  
→ Thus the patient is prepared for a series of swallowing exercises
- 2: "Try to swallow 10 sips of water in a rapid sequence"  
→ During swallowing, guide the endoscope above the esophageal opening / the postcricoid region. The upper esophageal sphincter "catches" the endoscope and pulls it inwards, thus it is pulled into the esophagus. You will suddenly see a lumen filled with bubbly fluids.
- 3: "Breathe again and do not swallow"  
→ After the bolus is transported caudally, the widened lumen is clearly visible until the next swallow sets in.
- 4: "Swallow again"  
→ After peristaltic constriction during swallowing, the esophagus widens again and downstream peristaltic movements can be seen.  
→ If you want, you can now inspect the lumen with NBI illumination.  
→ Slowly pull back the endoscope and observe the mucosa.  
After passing the postcricoid region you will end up in the hypopharynx.



*Setting of the examination: Examiner with the endoscope, nurse holding a glass of water with a straw*

## 4.6. Examination of Children

### 4.6.1. General Remarks

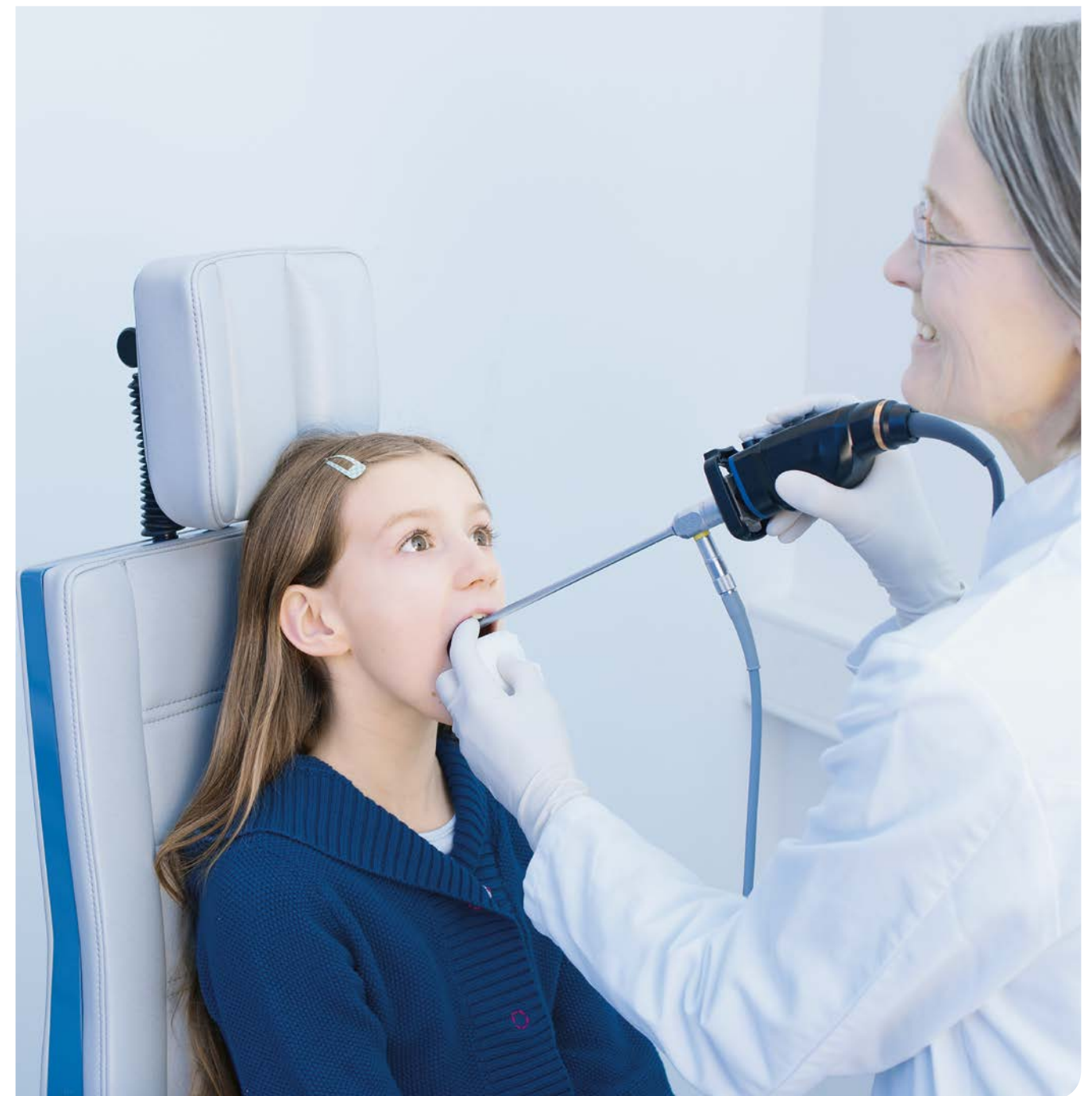
- There are various settings in which children may be examined.
- The most suitable setting will depend on the child's age and ability to cooperate.
- Rigid endoscopy can only be performed when the child is cooperative, it is seldom possible in babies and toddlers.
- There are big differences in children's ability to cooperate.
- Flexible endoscopy can be performed at any age, provided that the child may be held in a controlled position during the examination.
- In our experience, flexible endoscopy without immobilizing the child can often be performed from the age of 4–6 years and upwards.
- In our experience, rigid endoscopy can often be performed in children from the age of 6–8 years and upwards.
- For rigid endoscopy, a 70° endoscope is most suitable due to the superior cervical position of the larynx.
- In neonates and babies, flexible endoscopy can be performed with the baby sitting or lying and it is possible to perform a transnasal or transoral endoscopy. However, when small children have teeth they might bite on the flexible endoscope. In this case use transnasal access.
- In babies it often takes time to see the vocal folds and to assess their mobility because of the superior, anteriorly tilted arytenoid complex. Keep the endoscope tip positioned at the level of the uvula until you have seen enough.
- When examining a baby in a sitting position, the baby should sit upright and not half-lying. It is important to view the larynx from above and not from an anterior-superior angle – you will not see the vocal folds from the latter position.

#### Important:

- Video recording is highly recommended for subsequent off-line analysis and archiving a full record!
- For transnasal flexible endoscopy use topical local anesthetic in the nasal cavity (see chapter 3, preferably using anesthetic gel for application).
- Keep calm and do not fight with or bully the child.
- Explain to the parents that the examination – particularly when using the small flexible endoscope (diameter <2 mm) – does not hurt, but that the child has to be held in a controlled manner in order to prevent wriggling.
- The less the child moves the less it will be affected by the endoscope.
- Give precise instructions to the parents about the best way to hold the child so they feel safe even though their movement is restricted.

### 4.6.2. Transoral Rigid Endoscopy of Children

- Immobilizing a child is unhelpful for rigid endoscopy. However, holding them may offer some reassurance. To distract the child, involve them in the procedure. Have the child do something → e.g. holding their tongue with a gauze square.
- Ask the child to pant during the examination.

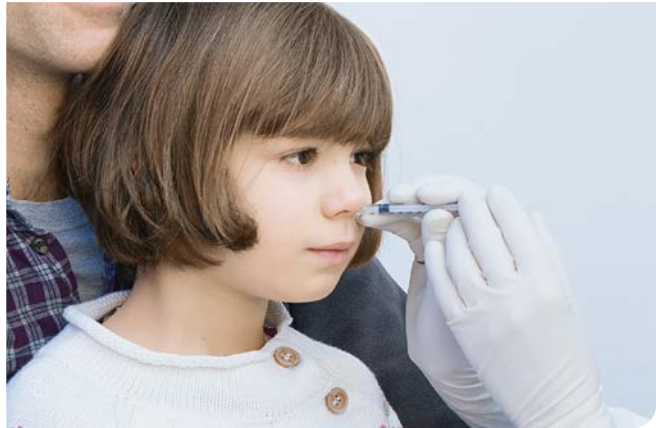

*Child capable of tolerating rigid endoscopy alone*

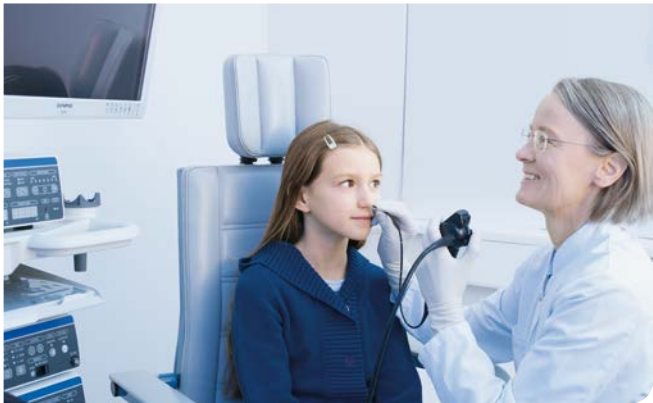


4.6.3. Transnasal Flexible Endoscopy of Children

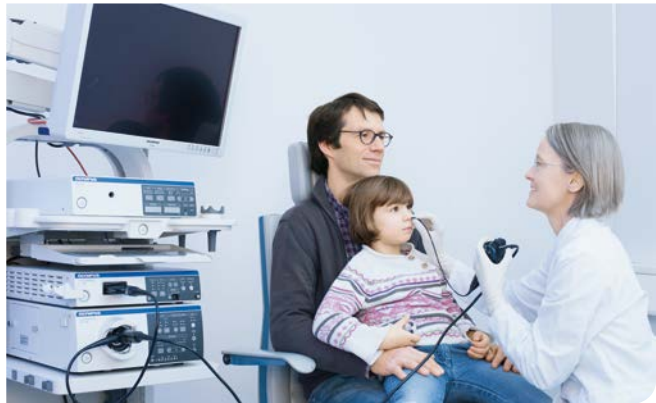For better visualization of the setting, the examiner holds the endoscope like a left-handed examiner.



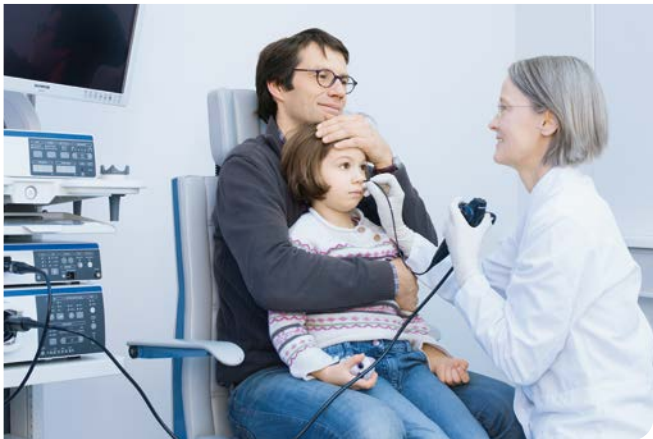Anesthetization: Children tolerate the application of lidocaine gel with a syringe better than spraying. Note that both hands are holding the syringe and the right hand holds contact with cheek.



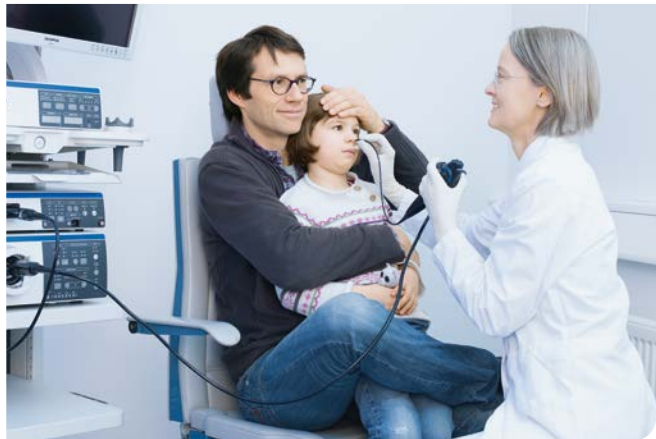Compliant child able to tolerate transnasal endoscopy



Transnasal endoscopy. Child, held by father

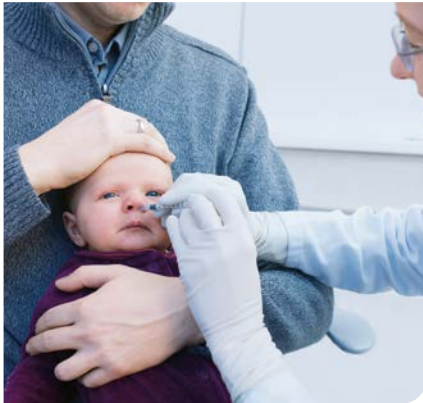

Child, held in controlled position. Note the position of the father's left hand and right arm.

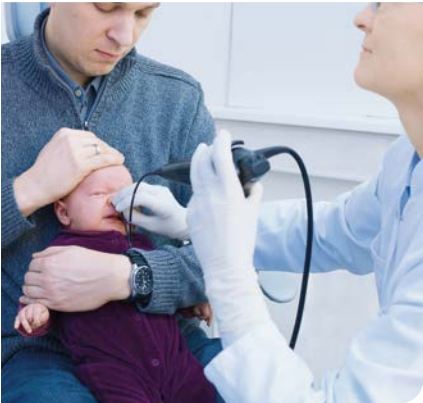

Child, held in controlled position. Note the position of the father's legs.

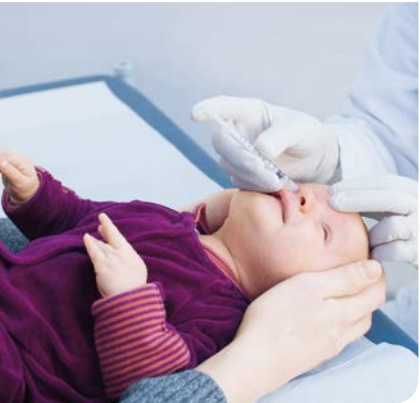4.6.4. Transnasal and Transoral Endoscopy of Babies (Flexible and Rigid)



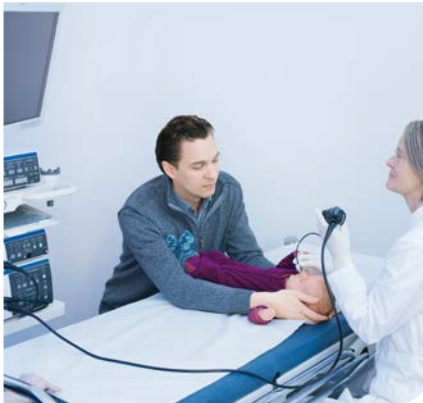Baby, sitting and held by father during anesthetization. Note that both hands hold the syringe and the right hand holds contact with cheek.



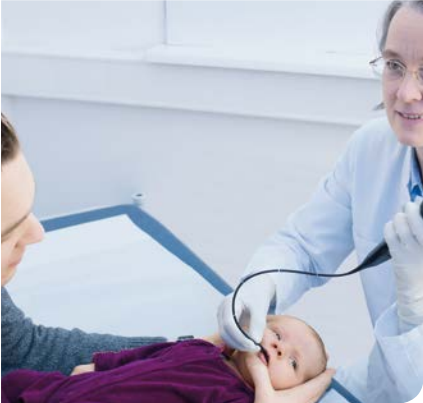Baby, held by father for transnasal endoscopy in sitting position.



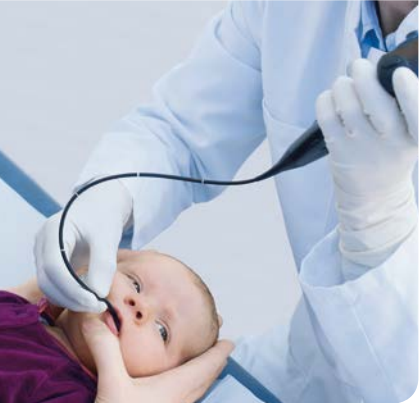Baby, lying and held by father for anesthetization of the nasal cavity. Note that the right hand with the syringe is stabilized on the baby's cheek.



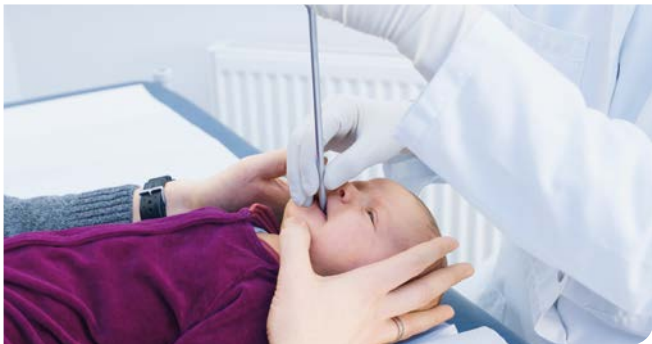
Baby lying for transnasal flexible endoscopy, father holding the child, examiner at head and looking at the monitor.



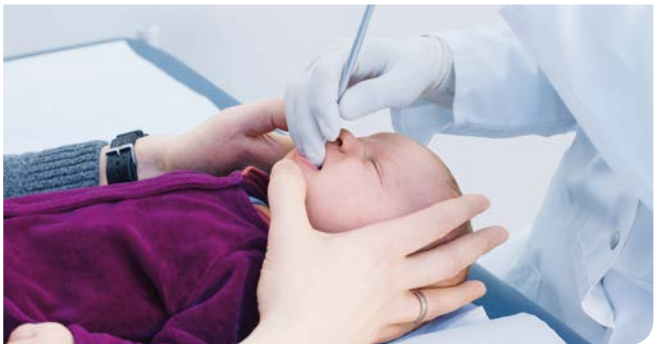
Alternative: Baby, lying for transoral flexible endoscopy. Note that the distal hand holding the endoscope is stabilized by contact with the cheek or mouth of the baby.



Same as before, enlarged



Alternative: Baby, lying for transoral 70° rigid endoscopy. Note that the distal hand with the endoscope is stabilized by contact with the cheek or mouth of the baby.



Same as before, note the different angle of the rigid endoscope after passing the velum. You can place one finger intraorally to guide the endoscope.

RECOMMENDED SEQUENCE OF  
PROCEDURES



RECOMMENDED SEQUENCE OF PROCEDURES

- In general, combining different methods, i.e. rigid and flexible endoscopy, stroboscopy, or NBI, helps to get maximum information about the larynx and its functions.
- For some clinical indications, special techniques may be more suitable (see Table 5.1).
- Before starting the endoscopy, prioritize for obligatory versus facultative maneuvers, according to the individual patient’s needs (see Table 4.2.).
- During examination you will learn how well the patient can tolerate the procedure so you can estimate how much time you have to continue.
- For clinical practice it helps a lot to have one routine process with the same sequence of procedures (see Table 5.2).

Recommended Sequence of Procedures During Endoscopy
<div>· First get an impression with a general view of the larynx and look for asymmetries, mucosal texture and form.</div> <div>· Watch for spontaneous movements such as paradox respiratory movements, tremor or myoclonus – do not rush through endoscopy maneuvers.</div> <div>· Check respiratory mobility with different maneuvers. (This takes some time; don’t rush.)</div> <div>· Consider that a subthreshold, almost elicited gag response can mimic a lack of unilateral vocal fold mobility. (We call it “pre-gag” immobility.)</div> <div>· Look for fine structures with the zoom (90° rigid endoscope) or by getting closer to the vocal folds (70° rigid endoscope, flexible endoscope: See Dipping Maneuver).</div> <div>· Use special light (e.g. stroboscopy blue light or NBI) for evaluating vocal fold surfaces and to avoid overmodulation when getting very close to the vocal folds.</div> <div>· Ask for repeated throat-clearing or coughing when secretion disturbs the view of the free edge of the vocal fold – or ask for inspiratory phonation. If necessary do it again and again until you are sure whether you see mucus or a vocal fold pathology.</div> <div>· Carry on with stroboscopy and special maneuvers. Always ask the patient to perform forced inspiration/inspiratory phonation and to phonate in falsetto voice.</div>

Table 5.1: Which Endoscopy Technique to Use for Which Clinical Goal

Clinical Question	Rigid Laryngoscopy				Transnasal Flexible Laryngoscopy		
	90°	90° + ZOOM	70°	+ STROBO-SCOPY	CHIP-ON-THE-TIP ENDOSCOPE	STANDARD ENDOSCOPE	+ STROBO-SCOPY
General view on larynx	✓		✓		✓	✓	
Fine structures		✓	✓	✓	✓		✓
Micro scars		✓	✓	✓	✓		✓
Anterior commissure			✓		✓	✓	
Subglottis, trachea	(✓)		(✓)		✓	✓	
Mobility of arytenoids	(✓)		(✓)		✓	✓	
Vocal fold pliability				✓			✓
Mucosal wave				✓			✓
Glottal closure				✓			✓
Configuration of vocal tract during speech or singing					✓	✓	
Exam with strong gag reflex					✓	✓	
Children			✓	(✓)	(✓)	✓	(✓)
Babies					(✓) (transoral)	✓	
Examination of swallowing					✓	✓	

✓ = Suitable technique for specific clinical question  
(✓) = Sometimes suitable

Table 5.2: Recommended Sequence of Routine Procedures

	Maneuver	Question
<b>Rigid Endoscope</b>		
Overview (halogen light)	Normal respiration	Spontaneous normal movements, paradoxical movements, tremor, myoclonus, spasm
	Phonation, throat-clearing, coughing, laughing, pressing with thoracic fixation	Respiratory mobility: Function of RLN, dislocation of cricoarytenoid joint. Supraglottal behavior, medial or anterior–posterior compression
	Falsetto phonation, glissando	Lengthening of vocal folds: Superior laryngeal nerve
Zoom / close-up view with halogen light	Normal respiration	Fine structures
Zoom / close-up view with blue light / NBI	Normal respiration	Fine structures, vessels, papilloma, dysplasia, carcinoma
Zoom / close-up view	Forced inspiration, inspiratory phonation	Mucosal pliability, vocal fold edema, pedunculated lesions, free edge of vocal folds
<b>Flexible Endoscope</b>		
(Halogen light) Position above velum	Normal respiration (look >5 sec)	Spontaneous movements of velum, tremor, myoclonus, spasm, velopharyngeal distance
	Phonation of “eee”, articulation of “coke” swallowing	Intentional movements of velum, paresis, paralysis, structural changes, velopharyngeal closure
Position for view on pharyngeal wall	Normal respiration (look >5 sec)	Spontaneous movements of pharynx, tremor, myoclonus
Position for overview of larynx	Normal respiration (look >5 sec)	Spontaneous normal movements, paradoxical movements, tremor, myoclonus, spasm
	Diadochokinesis test: “eee” and sniff, count and sniff, throat-clearing, coughing, laughing, pressing	Intentional respiratory movements of larynx
	Counting normally and very loudly, singing	Vocal tract configuration Supraglottic constriction
	Falsetto phonation, glissando	Lengthening of vocal folds: Superior laryngeal nerve
Position for close up view of vocal folds (halogen light and / or blue strobe light / NBI)	Dipping maneuver for vocal folds, subglottis, trachea: Long intense inspiration through the nose	Fine structures of vocal folds Structural changes at subglottis or trachea
	Forced inspiration Inspiratory phonation	Pliability of the mucosa, vocal fold edema; free edge of vocal folds after clearing secretions
If the patient has dysphagia	Examination of swallowing (FEES)	Dysphagia assessment
In the case of a tracheostomy	Transstomal inspection of trachea and subglottis	Obstructions, lesions, silent aspiration

	Maneuver	Question
<b>Stroboscopy (Rigid/Flexible Endoscope)</b>		
Stroboscopy flashlight (triggered)	Long “eee” or long “uuu” (ask for 10 seconds of phonation)  Try varying pitches and loudness levels in chest register	ASSESSMENT OF FUNCTIONAL LIMITATIONS Completeness and duration of glottal closure; amplitudes and mucosal wave, periodicity and symmetry of vocal fold vibration, phase shift, ventricular folds  SIGNS OF ORGANIC DISORDER Changes of mucosal wave, sulcus vocalis below free VF edge, scarring, epithelial thickening, loss of mucosal flexibility, infiltrating mass lesion
	Inspiratory phonation	Mucosal pliability (helps when ventricular folds are covering vocal folds during normal phonation)
	Falsetto / head register / very high pitch 10 seconds of “eee” (soft and loud)	Assessment of vocal fold vibration, specifically at the free edge





# TIPS & TRICKS

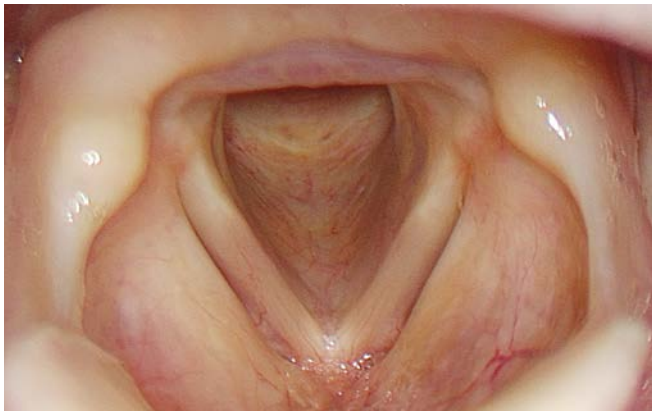
Using the procedures described above, imaging of the larynx is successful in almost all patients. However, there remain a few cases in which endoscopy “doesn’t work” in the sense that there are problems with the image quality or the vocal folds or the anterior commissure are not visible, or it is unclear how to interpret the organic findings. In the following section we describe tips and tricks and special maneuvers that help to cope with such problems and that give additional information about morphology and laryngeal functions. Some solutions apply to both rigid and flexible endoscopy. Keep in mind that some maneuvers solve different problems, and some problems can be handled using different maneuvers. We have divided this chapter into four parts: 6.1.: Poor Image Quality; 6.2. Patient-Related Problems; 6.3. Special Maneuvers; 6.4. Special Positioning of the Endoscope or the Patient. See also table 6.1.

## 6.1. How to Solve Problems with Poor Image Quality

Sometimes technique related problems occur during endoscopy and worsen image quality so you cannot see enough. Examples for reduced image quality are shown and solutions for these situations are described in this section (see also chapters 2.2. and 2.3.).

**Preconditions for Adequate Imaging**

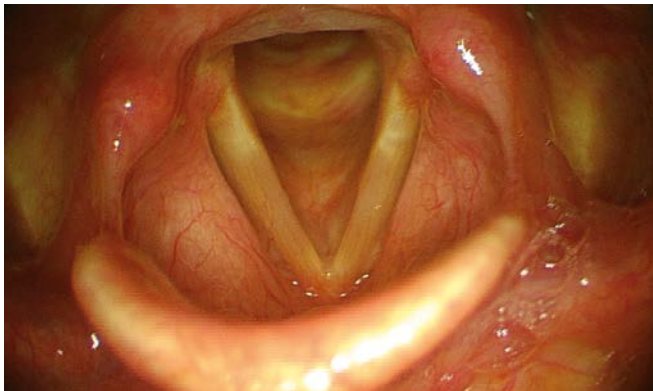
- Overall clean lens
- “White-balance”
- Adequate color and contrast
- No image rotation
- Region of interest (ROI) centered
- Adequate focus on the ROI
- Overall sufficient illumination
- Sufficient magnification



The larynx during quiet respiration. The image is acceptable and meets the preconditions.

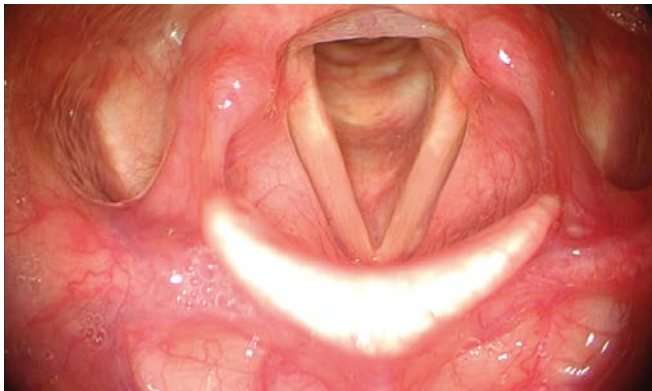
**Problem: Colors**

Unnatural colors (here: Too yellow)



**Solution:**

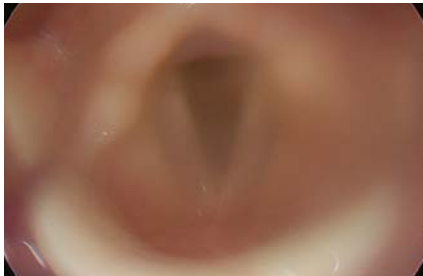White-balance the image



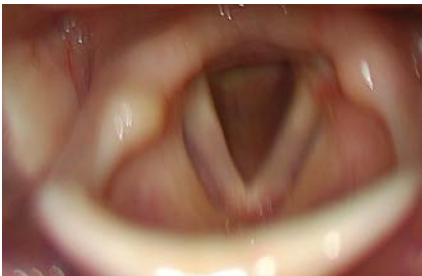**Problem: Blurred Image**

Endoscope lens is blurred

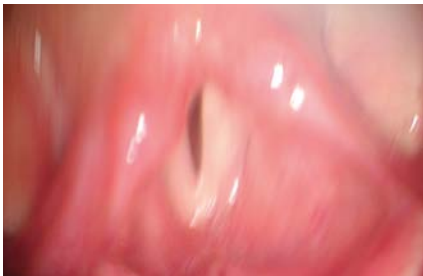A) Problem with fogging, B–E) Problem with secretions on the lens



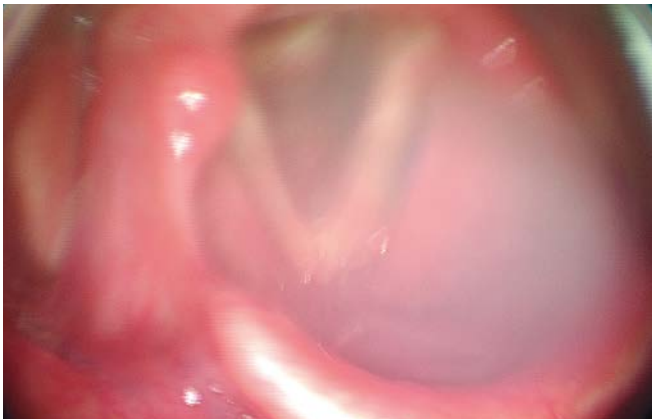A) Diffusely blurred image due to fogging



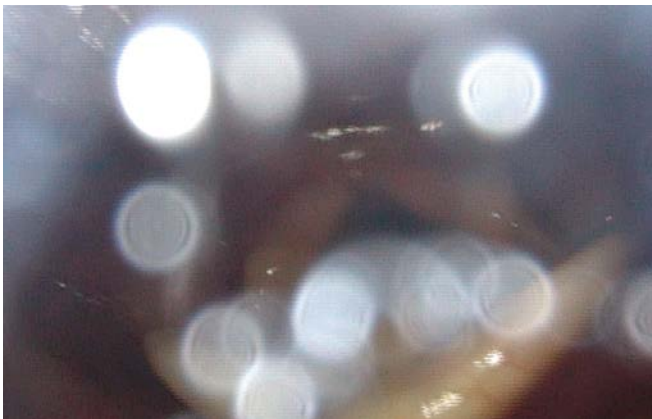B) Partially blurred image due to secretions on lens



C) Blurred image due to secretions on lens



D) Blurred image due to secretions on lens



E) Blurred image due to secretions on lens

**Solution:**

- Clean the lens by wiping it over the base of the tongue (rigid endoscopy: With a quick in-and-out movement in the direction of the endoscope).
- Ask the patient to cough. (“air brush”)
- Ask the patient to exhale forcefully while holding the tip of the endoscope above the glottis.
- Ask the patient to swallow. Swallowing provides a sort of “lens wiper” action (but only when performing flexible endoscopy).
- Ask the patient to swallow some water (flexible endoscopy).
- If the patient is supine and is producing copious secretions; the secretions tend to pool close to the tip of the endoscope, blurring the lens.

Solution: Turn the tip of the endoscope so that it lies in a more horizontal plane

- See also next page: antifogging



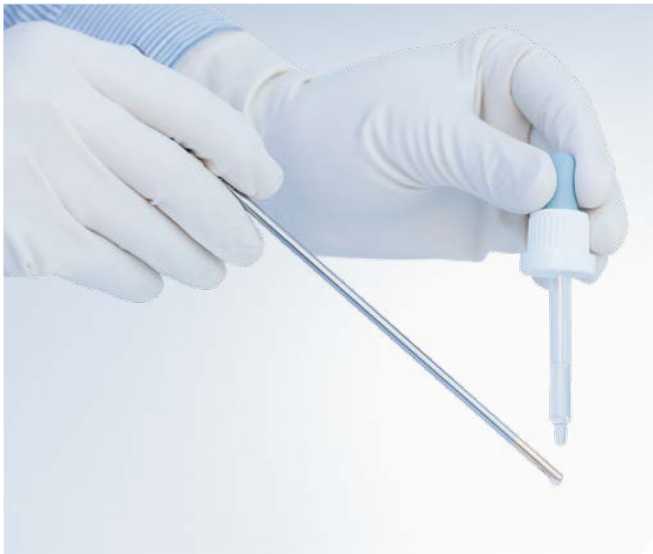**Problem: Blurred Image due to Fogging of the Lens**

A blurred image can also be due to fogging of the distal lens.

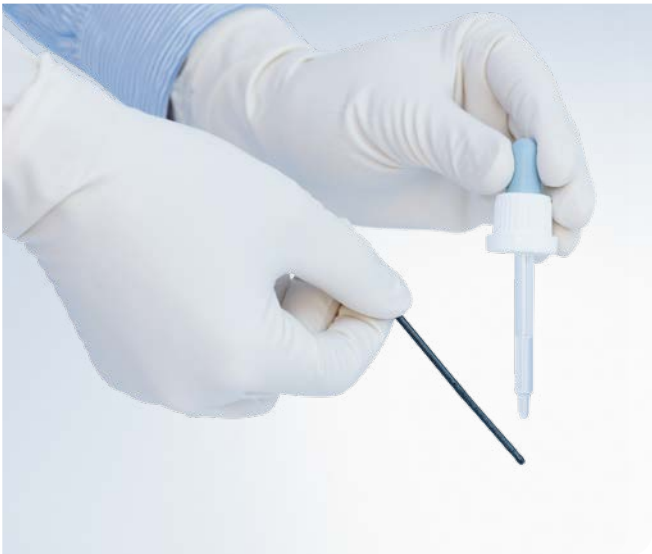**Solution:**

There are various techniques available to prevent fogging of the distal lens. Here we show some useful methods.

- Use of antifog solution
- Warming of the tip of rigid endoscope, e.g. with hot water (don't try this with flexible endoscopes)
- Touch mucosa of cheek or tongue: Saliva is a good antifog lubricant.



Antifog drops



Do not contaminate the pipette. One drop is enough. Do not wipe the lens afterwards.



Heating with hot water (only seconds)

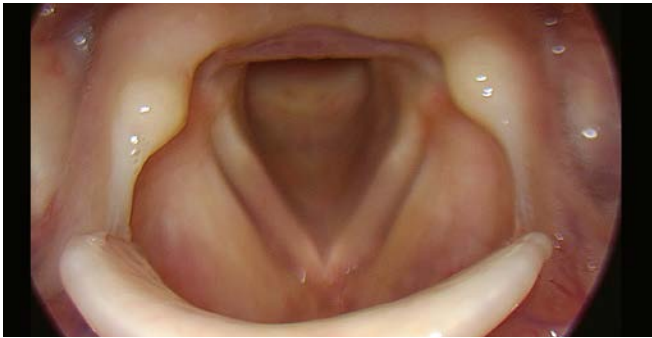**Problem: Defocussed Areas**

Not all structures in focus

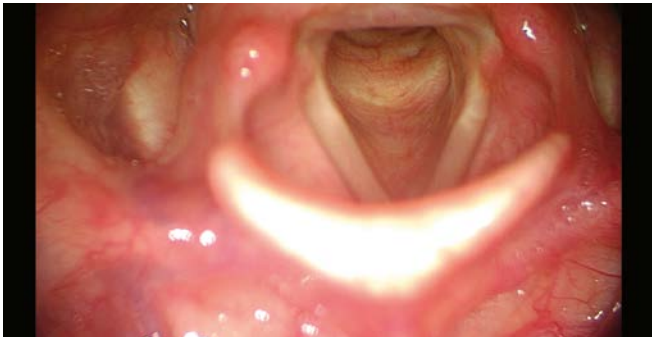
**Solution:**

**“You can’t get it all”!** 😊

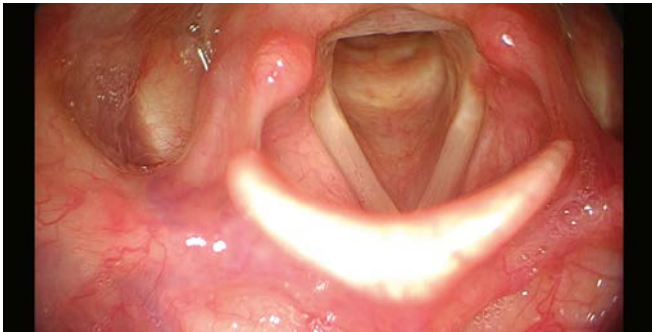→ Searching for best focus depending on region of interest (ROI). Sometimes you need multiple images.



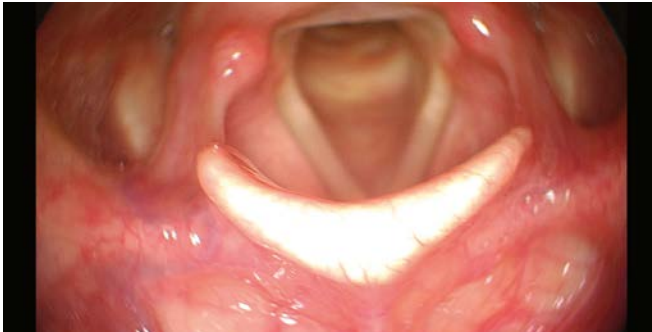Vocal folds not well focussed, only epiglottis in focus



Focus on level of cricoid shelf, vocal folds not well focussed.



Vocal folds are focussed, but epiglottis is overmodulated



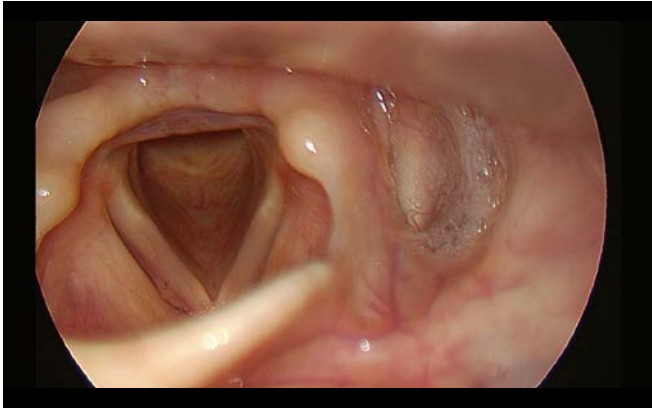Focus too superior and epiglottis overmodulated

**Problem: ROI Not Centered**

Region of interest not centered and thus not focussed (rigid endoscope)

**Solution:**

Move the tip of the endoscope medially.



Problem: Image Brightness Not Convincing

When the lens of the endoscope is placed very close to a surface, the image becomes overmodulated and ‘washed-out’ due to automatic camera overcorrection (average brightness of all pixel brightness values). These images show how illumination (brightness) can change image quality. Images which are too dark or too bright “lose” information.

Solution:

- Here again: You can’t get it all in one image
- Decrease light intensity by changing the gain control of the camera unit or light source from automatic to manual to adjust the illumination
  - Change to another light quality such as blue stroboscopy light or NBI.

Problem: Brightness Level

Image too bright

Solution:

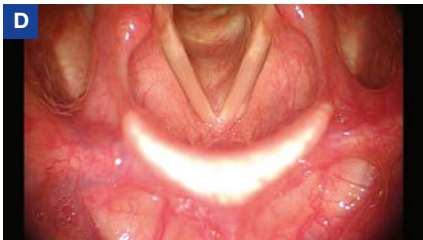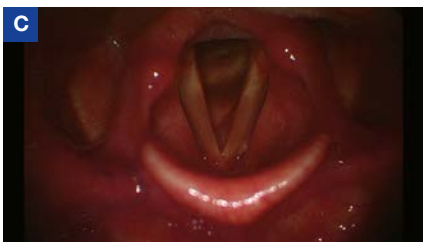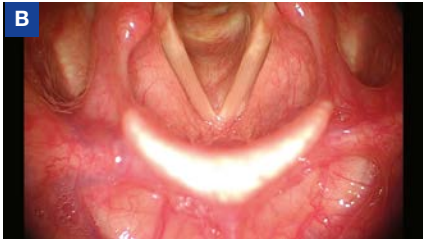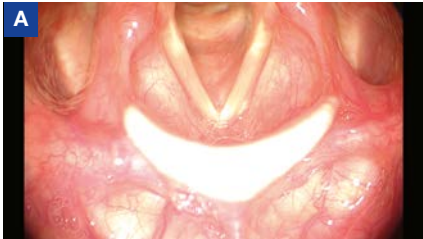A) Overmodulated image – use AGC or reduce the brightness manually. B) Same view with decreased light intensity

Problem: Brightness Level

Image too dark

Solution:

AGC or manual brightness enhancement



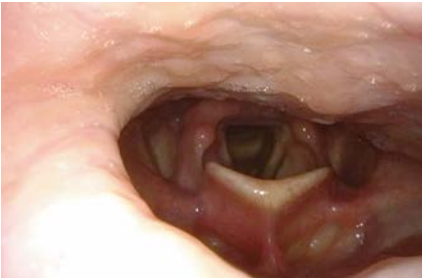A–D) Different examples for brightness variations

Note:

Sometimes regions of interest are optimally illuminated when the overall image is dark or bright. (see preceding page). FEES should be performed without setting automatic gain control of the lighting.

Problem: Partially Overmodulated – Not ROI

Look at illumination levels: Structures that are close to the lens (here: the velum) are overmodulated. Consequently, the camera reduces the light output (AGC mechanism), thereby producing insufficient laryngeal illumination.



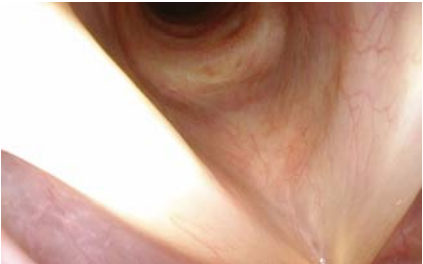Larynx seen from the nasopharynx.

Solution:

Because the larynx is your ROI, advance the endoscope. Try to shift the lens away from anatomical structures that get in the way of the endoscope’s passage.

Problem: Partially Overmodulated - but ROI

Note the differences in brightness within the image. The overmodulation of the camera is due to the apparent “white” tissue area caused by reflections. With AGC selected, the camera gain, which responds to average light values, would be reduced. This would produce an overall darkening of the image.



Vocal folds, tip of endoscope close to glottis

Solution:

Decide where the ROI lies. In this image the anterior commissure and anterior subglottic region are optimally illuminated. The right posterior vocal fold is too bright. If the right vocal fold is of interest, you can (A) wait until AGC reacts and then the vocal fold will be seen clearly, or, (B) when AGC is deactivated, move your endoscope away from the vocal fold to avoid overmodulation. (C) Three other alternatives remain: Switch on the strob light (which is usually not as bright), or use NBI-illumination, or ask an assistant to turn down the light power.



**Problem: Interlacing**

Motion artifacts with jagged, serrated contours.

**Solution:**

Camera recording problem. If interlacing occurs too often, change the image-capture mode by reducing frame-grabbing settings to odd or even fields (camera settings).



Source: [https://en.wikipedia.org/wiki/Interlaced\\_video](https://en.wikipedia.org/wiki/Interlaced_video)

**Problem: “Striped” Image**

Poor image quality, “striped” image (only with standard glass-fiber flexible endoscopes).

**Solution:**

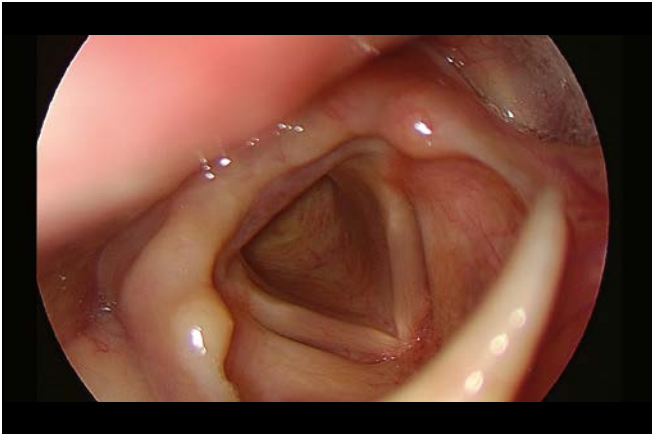Minimize moiré by slight defocussing (see 2.4.3. flexible endoscope and camera adjustment)

**Problem: Image Rotated**

The sagittal direction of the larynx is not vertically oriented on the monitor (rigid endoscopes)

**Solution:**

Correct alignment by rotating the (detachable) camera. (see chapter 2.4.2.)

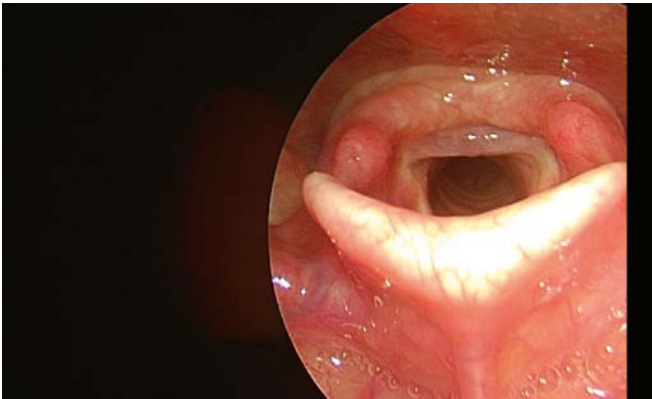


**Problem: Asymmetric Camera Frame**

Black margins are asymmetric (rigid endoscopes and standard flexible endoscopes).

**Solution:**

Warning! The camera adapter is only partially attached to the endoscope eyepiece. The camera could become disconnected and fall off with the next movement. Stop the examination and reconnect the adapter to the eyepiece.



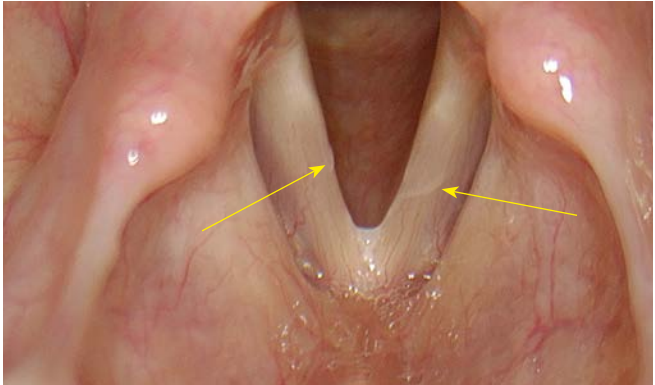
“Alarm”

6.2. Patient-Related Problems: Secretions and Gag Response

Unfortunately, not all patients are within normal limits when it comes to suitability for endoscopy. But we can also cope with these challenges. The most annoying factors that we encounter are secretions as well as the “foaming” saliva pooling in our ROI, which especially occurs after topical anesthesia, and, as everybody knows: The exaggerated gag response!

**Problem: Mucus Disturbance**

Mucus typically accumulates in the mid-membranous region of the free edge of the vocal fold when the patient phonates, thus either covering or mimicking prenodular lesions, nodules or leukoplakia.

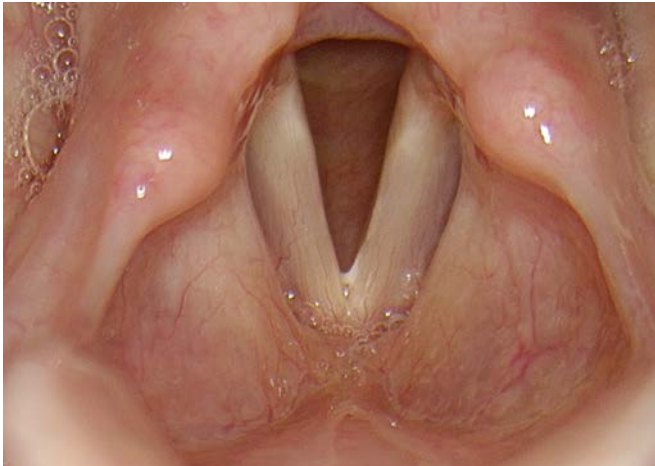

Mucus, mimicking a very small nodule on the right vocal fold and a scar or a tiny leukoplakia on the left vocal fold

**Solution:**

To differentiate between mucus on the vocal folds and mucosal lesions (both in rigid and flexible laryngoscopy):

- ➔ Repetitive soft throat-clearing, if necessary with increasing force, or cough until you see the free edge of the vocal fold.
- ➔ If coughing elicits a gag response, try with inspiratory phonation or with forced and rapid inspiration. It sometimes sucks the saliva away.



After throat-clearing

Problem: Extensive Gag Response

If there is an extensive gag response or coughing in spite of anesthesia the examination might not be possible.

Solution:

- |  |  |
|--|--|
| <ul style="list-style-type: none"><li>• Maximize spray anesthesia</li><li>• Use pantocaine instead of lidocaine</li><li>• Anesthesia of larynx (see chapter 3.4.)</li><li>• Let the patient phonate “eee” as long as possible (with or without a strobe) as a distraction!</li><li>• Acupressure at midpoint between lower lip and chin (Ren 24 Chengjiang, point in the middle of the mentolabial fold)</li></ul> | <p>Rigid Endoscopy:</p> <ul style="list-style-type: none"><li>• Patient position: Elbows on knees (see chapter 6.4.)</li><li>• Let the patient breathe through the mouth!</li><li>• Let the patient continue breathing and ask them not to hold their breath</li><li>• Close the nose to force breathing through the mouth</li><li>• Ask the patient to pant continuously</li><li>• Choose very lateral intraoral position for endoscope</li><li>• Change from 90° to 70° rigid endoscope (or to flexible endoscope)</li></ul> |
|--|--|
- Flexible Endoscopy:
- Slow inspiration through nose (see Dipping Maneuver)

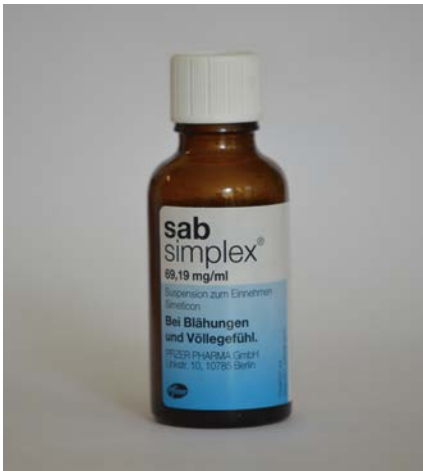Problem: Foaming

Foaming

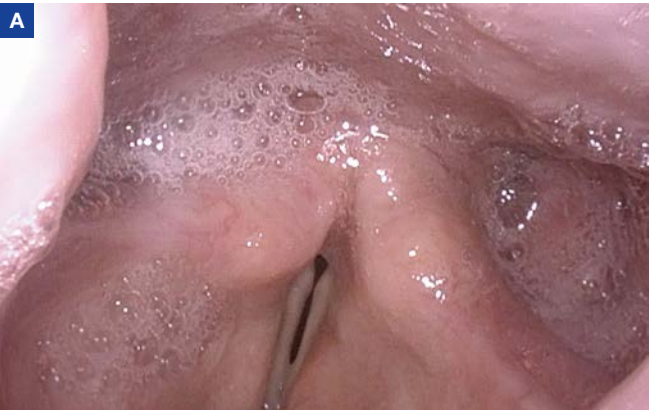After local anesthesia some patients react with “foaming” of secretions, i.e. increasingly foamy mucus accumulates and interferes with the examination. The annoying fact is that swallowing actually increases foaming.

Solution:

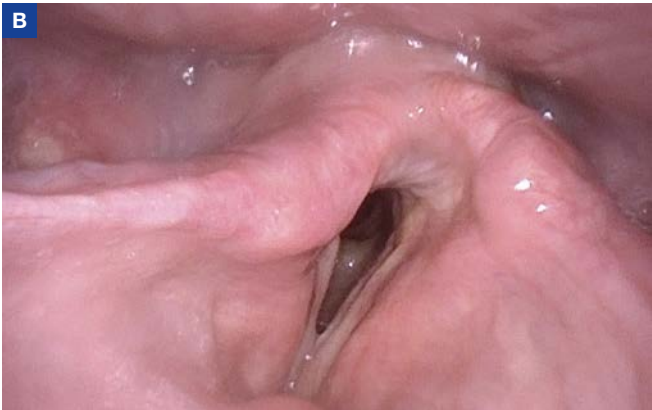- To reduce foaming, you can
- A) Use a suction tube and suck all secretions away or
  - B) Use Dimeticon and liquify the foam, so that it can be swallowed.



Ask the patient to swallow a spoonful of Dimeticon.



A) “Foaming” after local anesthesia



B) Same situation after administration of one teaspoon of Dimeticon

6.3. Special Maneuvers

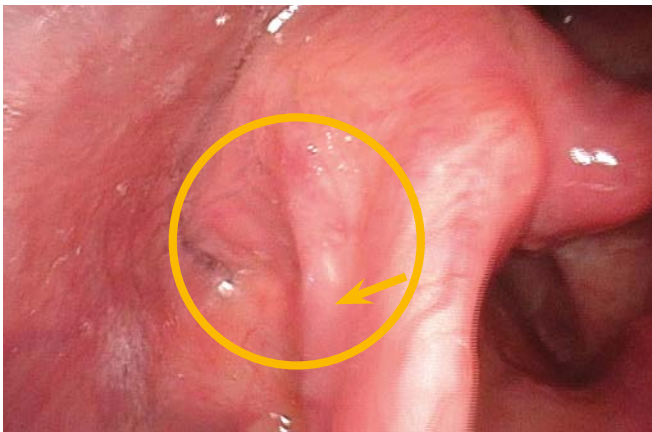In this chapter we describe special maneuvers that have proved helpful in the past. We recommend that you retain them in your endoscopy armamentarium in order to deal with situations demanding special tricks.

Also see Table 4.2.: Useful Maneuvers in Flexible Laryngoscopy

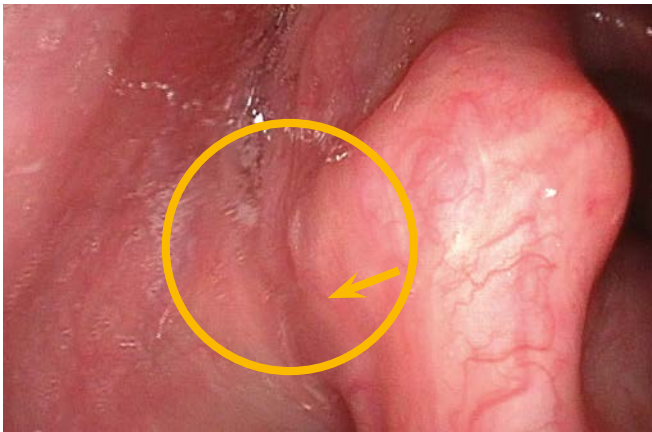Problem: Suspected Hypomobility

Solution:

- Use flexible laryngoscopy for testing the respiratory mobility of the arytenoids and the vocal folds.
- Video documentation with frame-per-frame off-line analysis is highly recommended.
- Perform various maneuvers:
- Repeated phonation of “eee”, quickly and slowly, in staccato mode
- Repeated sniffing with sharp inspiratory nasal sniffs
- Repeated “eee”-sniff (diadochokinesis) maneuvers
- Throat-clearing and coughing
- Laughing
- Look for the **active** lateralization of muscular process during vigorous abductory maneuver, e.g. forceful sniffing (A, B)
- Nota bene: The original definition of the “jostle sign” refers to a passive motion of the arytenoid by the other arytenoid. In our procedure of forceful sniffing, look for the active movement of the muscular process by activation of the posterior cricoarytenoid muscle. Sometimes it looks like a knee kicking under a blanket.



A) Look at posterior larynx, arrow points at region of muscular process. During phonation, the muscular process cannot be seen.



B) During forced inspiration, the arytenoid is actively maximally abducted and the muscular process may be visible (see arrow).

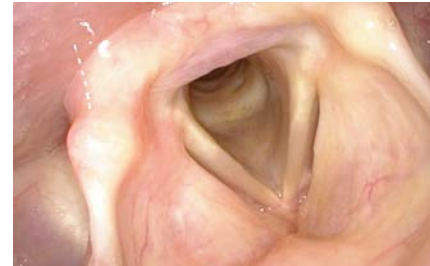Note:

Respiratory mobility of the arytenoids and vocal folds should always be tested thoroughly and with several maneuvers.



**Problem: Close-Up View of Vocal Folds Needed  
(Flexible Endoscopy)**

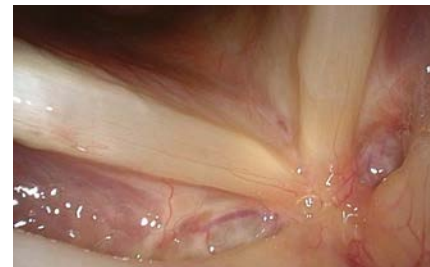Because of small morphologic changes of the vocal fold you want to get a very close-up view of the vocal folds.



*Vocal folds, normal distance*

**Solution:**

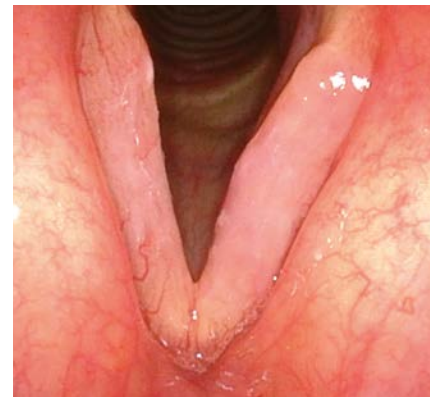- To get a very close-up view of the vocal folds or of the subglottis / trachea during flexible endoscopy perform the dipping maneuver with a long lasting inspiration through the nose (for a detailed description see chapter 4.5.1.)



*Vocal folds, high magnification during dipping maneuver*

**Problem: Size of Reinke's Edema Unclear**

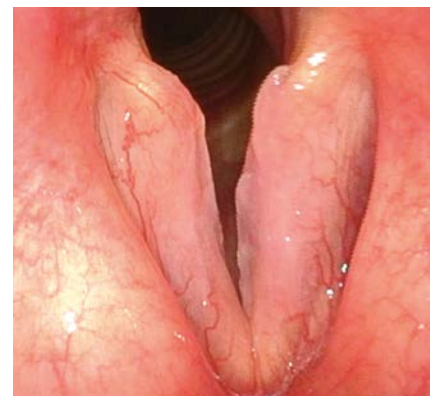- On occasion, localized Reinke's edema or pedunculated lesions at the free edge of the vocal fold are found on the superior surface of the vocal fold and will not be detectable in shallow respiration.



*Normal respiration*

**Solution:**

- Whether using rigid or flexible endoscopy, try asking the patient to perform a forced, rapid inspiration. This leads to suction of the medial part of the vocal folds into the glottis and thus the edema or pedunculated lesions at the free edge will become "aerodynamically medialized" and detectable.
- Forced and rapid inspiration (see also inspiratory phonation) may also help to clear mucus from the free edge of the vocal fold while avoiding the throat-clearing with associated blurring of the lens.



*Forced inspiration*

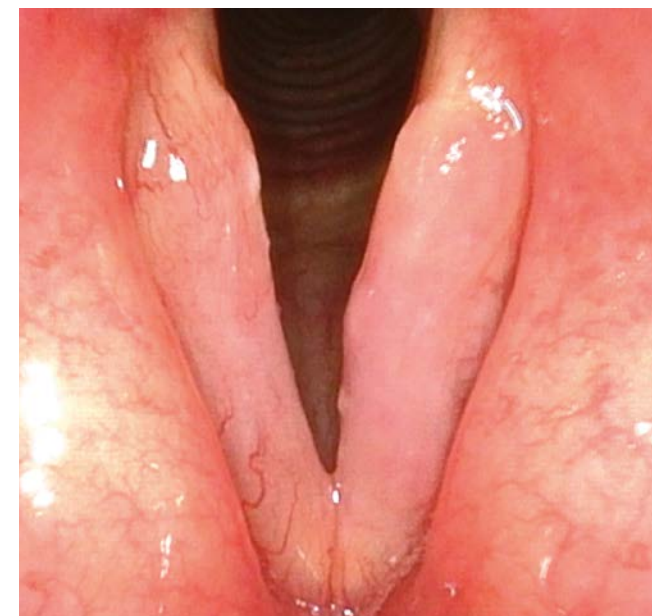**Problem: Ventricular Folds Covering Vocal Folds or  
Pliability and Free Edge of Vocal Fold Unclear**

- (1) The vocal folds cannot be seen during phonation because they are concealed by the ventricular folds.
- or**
- (2) You need a general impression about the mucosal pliability at the free vocal fold edge.
- or**
- (3) You want to rule out additional masses on the superior surface of the vocal folds.

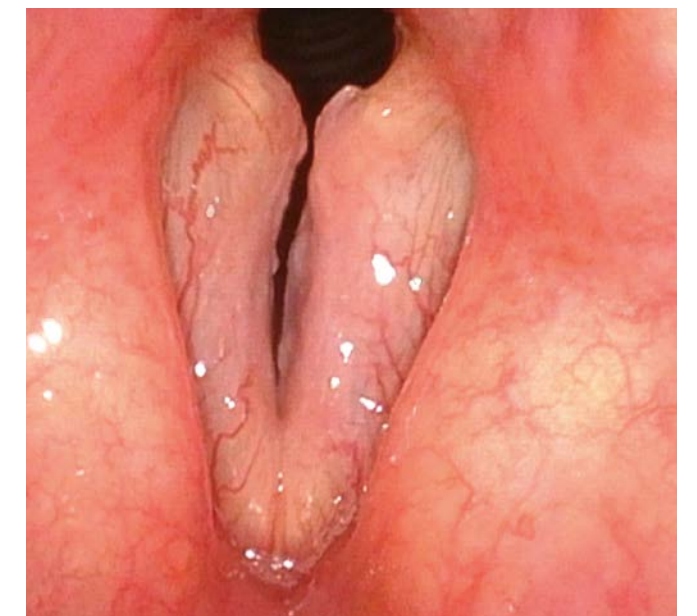
**Solution:**

During inspiratory phonation (both in rigid and flexible laryngoscopy), the following phenomena can be seen:

- (1) Inspiratory phonation adducts the vocal folds and abducts ventricular folds. With the ventricular folds moving laterally, the entire superior vocal fold surface and parts of the ventricle can be seen.
- (2) The free edge of the vocal folds is sucked into the glottis and shows where the mucosa of the free edge is normally pliable.
- (3) Reinke's edema or other mass lesions on the superior surface of the vocal folds can be detected.



*Respiration*



*Inspiratory phonation*

**Note:**

Forced and rapid inspiration and inspiratory phonation should always be part of the examination of benign mass lesions located on the vocal folds.

**Problem: Ventricular Folds Covering Vocal Folds (See Above)**

Ventricular folds are in a hyperadducted position and therefore cover the vocal folds.

**Solution:**

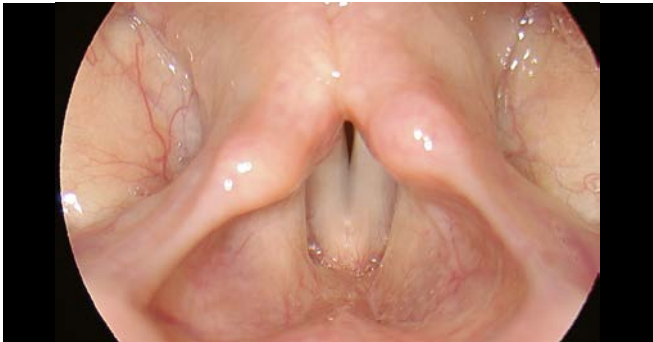- When the ventricular folds are covering the vocal folds during phonation, change from “eee” to “uuu” (especially in rigid laryngoscopy).
- Phonation of “eee” usually pulls the tongue base and epiglottis forward. Phonation of “uuu” additionally leads to abduction of the ventricular folds. The ventricular folds will move more laterally, the epiglottis sits slightly more upright, and the vocal folds can be seen. Even with rigid endoscopy “uuu” is possible. Make sure that your patient really tries hard to phonate “uuu”.
- Inspiratory phonation also adducts the true vocal folds and abducts false vocal folds (see above).

**Problem: SLN Function Unknown or Free-Edge Problem**

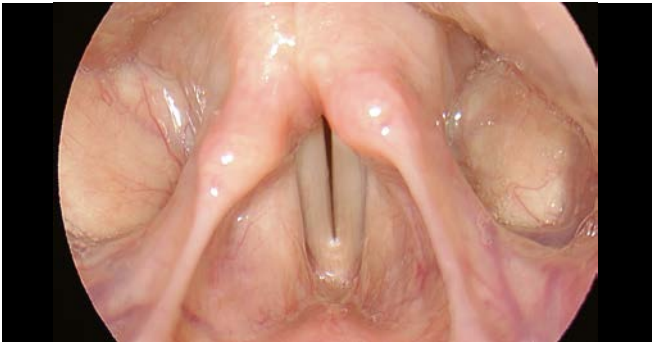(1) You need detailed information about the superior branch of the recurrent superior laryngeal nerve function.  
**or**  
(2) You are not sure whether the margin of the vocal fold is smooth and straight.

**Solution:**

- Falsetto phonation (both rigid and flexible laryngoscopy) leads to lengthening of vocal folds and gives information about CT muscle and superior laryngeal nerve function.
- If very small epithelial lesions of the free margin exist, they will show as contour irregularity (particularly, when using stroboscopy).



Low phonation with shortened vocal folds



Falsetto phonation, vocal folds stretched

**Note:**

Falsetto phonation should always be part of the examination of benign mass lesions of the vocal folds.

**Problem: Need to Inspect the Trachea**

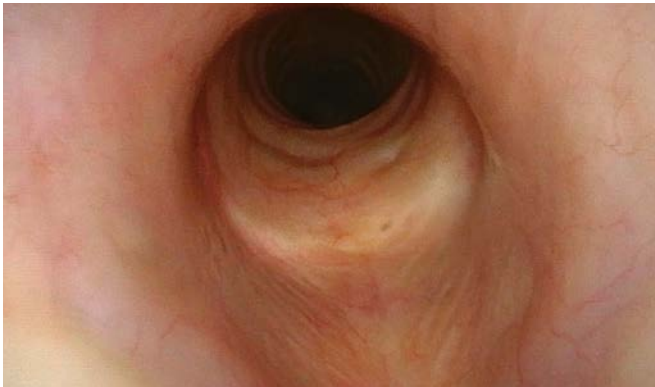Suspected changes in the trachea (flexible endoscopy)

**Solution:**

Chin-tuck maneuver, combined with dipping maneuver (see chapter 4.5.1.)



Head bent forward and flexible endoscope near to glottis



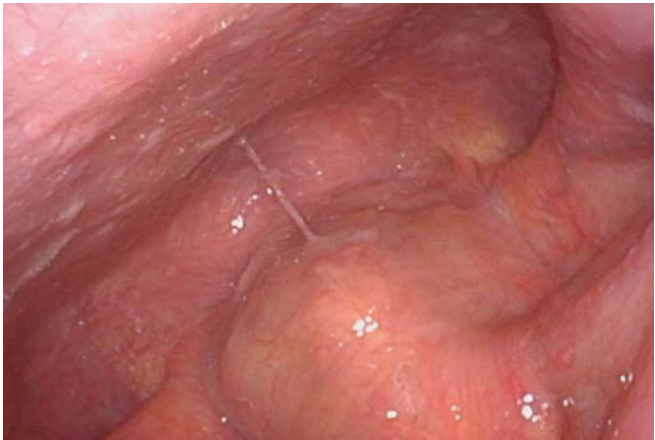Inspect the upper trachea

**Problem: Need to Inspect Piriform Sinus and Postcricoid Region**

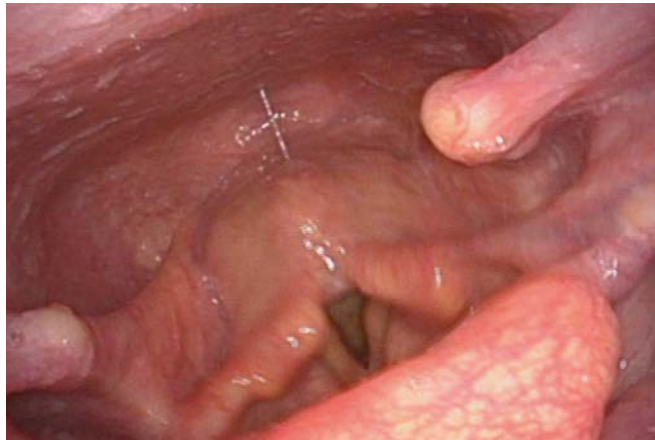You should inspect the piriform sinus and postcricoid region

**Solution:**

Ask the patient to perform a Valsalva maneuver (trumpet maneuver) while the endoscope is in place and the nostrils and mouth are completely closed.



While a Valsalva maneuver the postcricoid region can be seen.



In rare occasions, the upper horns of the thyroid cartilage stick into pharyngeal lumen during Valsalva maneuver.




**Problem: The Epiglottis Is Covering the Vocal Folds**

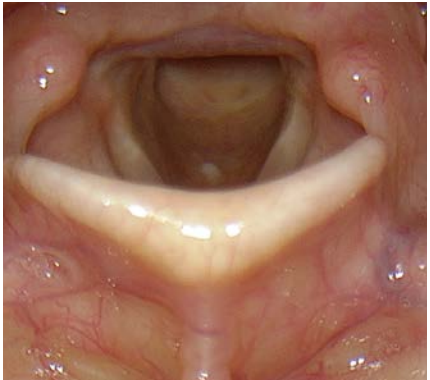You cannot see the vocal folds because the epiglottis is covering them.

**Solution:**

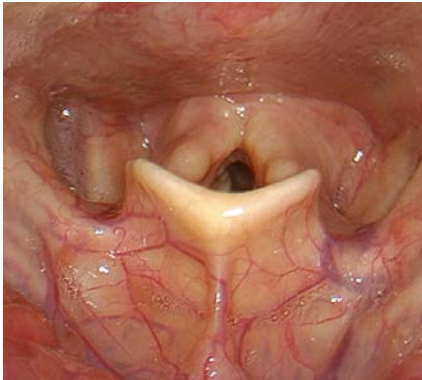
- Adjust the patient’s head and neck position to obtain a better view of the glottis (applies to rigid laryngoscopy).
- Ask the patient to actively cause the mandible to protrude.
- Phonation of “uuu” instead of “eee” (see above).



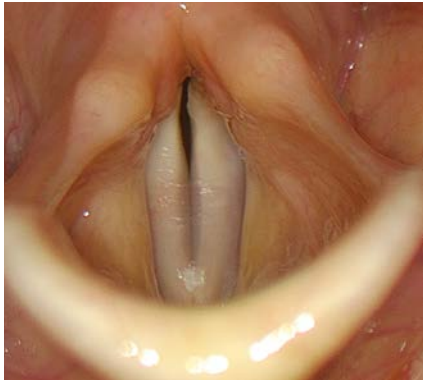
Ask patient to actively advance the mandible



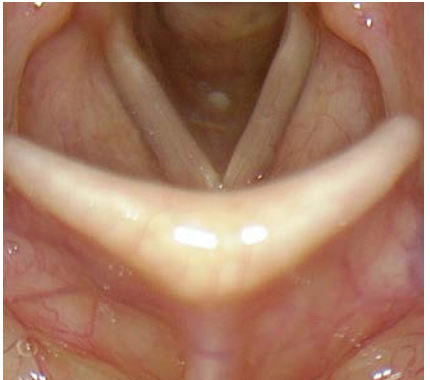
Jaw in normal position



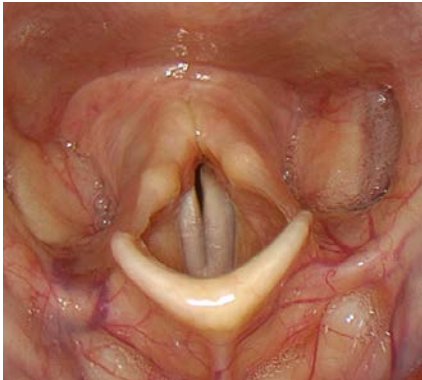
In some patients the glottis is not visible during respiration, but ...



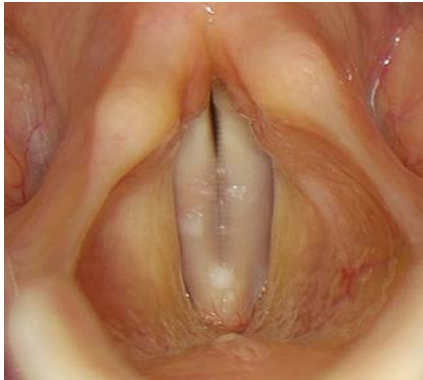In some patients the anterior commissure is not completely exposed during phonation of “eee” but ...



Jaw protrusion enables exposure of the entire glottis.



... is exposed during phonation of “eee.”



... is during phonation of “uuu.”

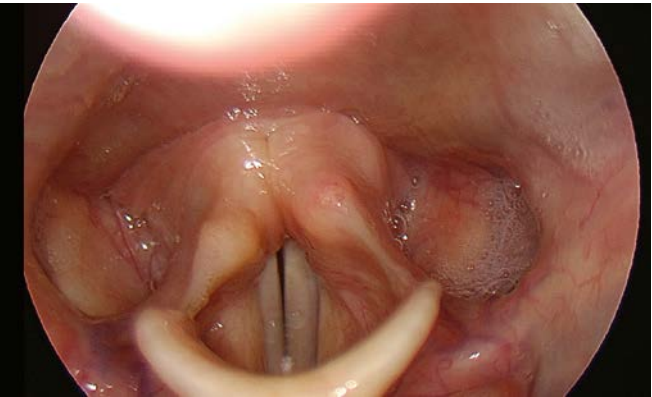
6.4. Special Positioning of Endoscope or Patient

Sometimes specific laryngeal structures – mostly the vocal folds – cannot be seen with the normal position of the patient and the normal position of the endoscope. Especially in rigid endoscopy, changes of the position of the patient or the examiner or special maneuvers with the tip of the endoscope may help to achieve a better visualization of the vocal folds.

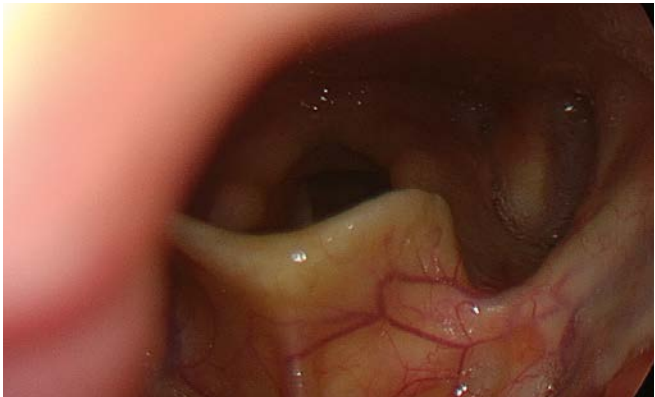
Below you will find some examples of insufficient exposure of the glottis.

**Problem: The Uvula Disturbs**

The uvula may intrude and disturb adequate illumination during rigid endoscopy. When the endoscope lens is placed very close to a surface, the image will show a local washed-out whitish patch due to the camera’s averaging light management software.



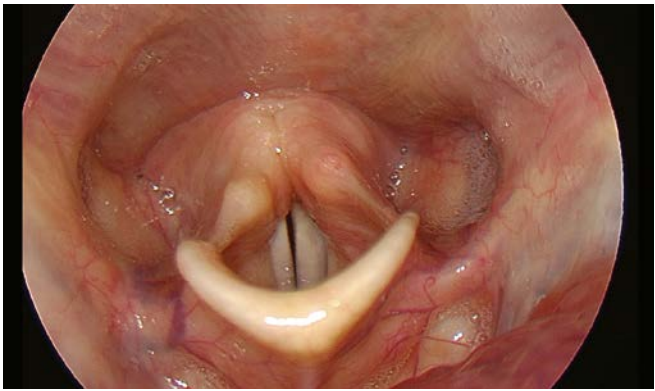
The uvula, which is protruding into the upper part of the image, is “washed out,” unfocussed and is disturbing the average light values for the whole image.



Again, the uvula is in the way. The camera's software senses the local white patch and automatically reduces the overall illumination for the image, thereby producing a darker picture. (The so-called AGC effect.)

**Solution:**

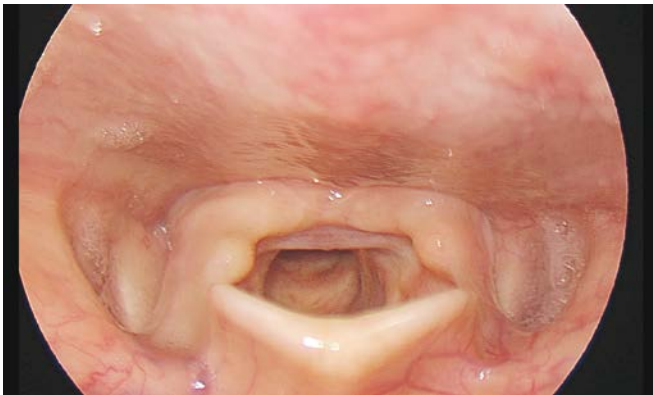When “fighting” with the uvula, try dropping the endoscope tip and advancing it a bit more inferiorly.



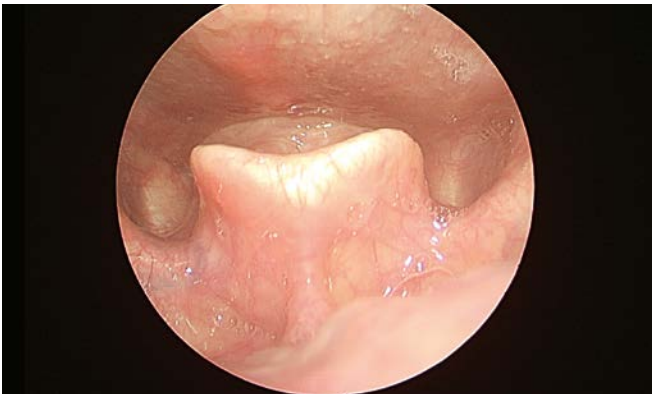
Better, but not ideal. Use the techniques described in this chapter to improve the endolaryngeal view.



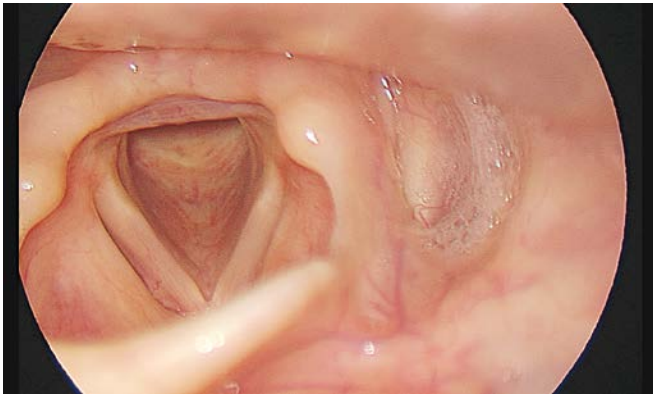
**Problem: No Sufficient Exposure of the Larynx in Rigid Endoscopy**  
Here we show examples of suboptimal positions for the endoscope tip.



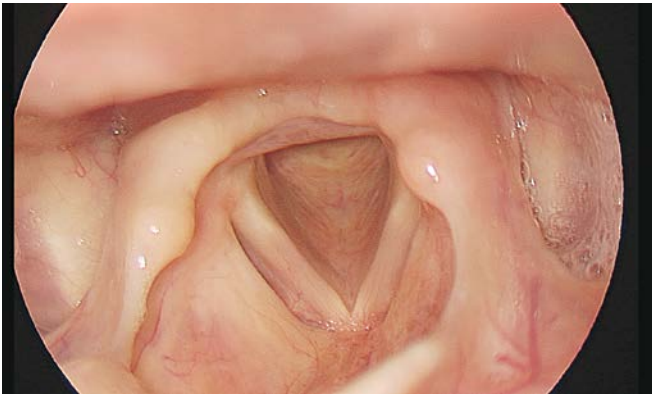
Tip of endoscope is too superior – anterior commissure cannot be seen. The entire upper part of the image displays the posterior pharyngeal wall (not region of interest).



Epiglottis is tilted too far posteriorly. Use maneuvers to advance epiglottis, e.g., let the patient phonate “uuu” or push the mandible forward.

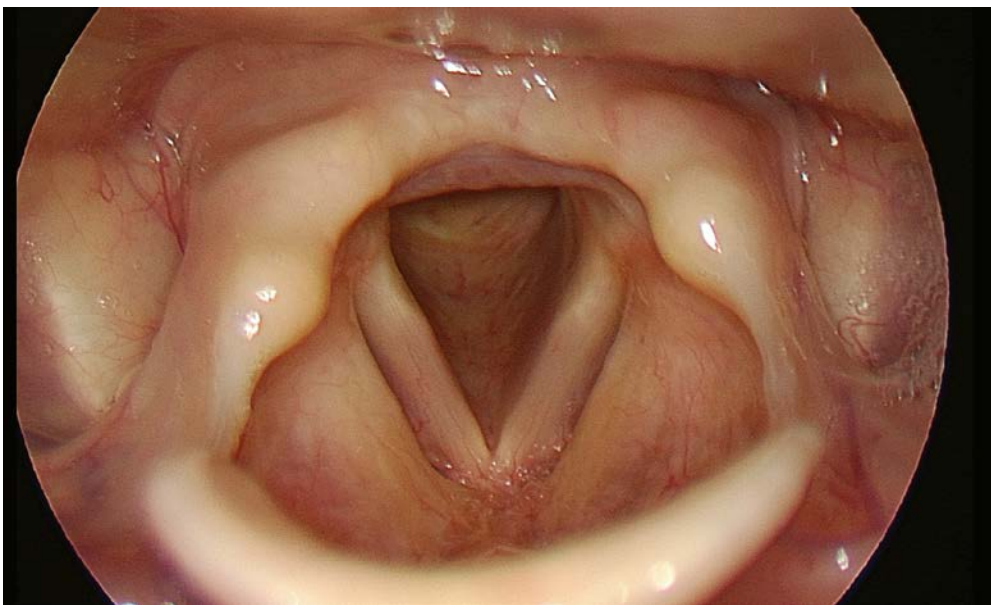


Although the anterior commissure can be seen, the region of interest (endolarynx) is not in the center of the image. The tip of the endoscope is too far to the left.



In comparison to the preceding figure, after rotating the rigid endoscope shaft the glottis and endolarynx are now visualized better. However, the left ventricular fold is only seen in part. A better solution: Shift the endoscope tip to the midline!

**Solution:**  
Improvement of positioning the rigid endoscope tip.  
See intraoral position of tip of rigid endoscope (see description above).



Good visualization of the larynx. Always try to image the larynx like in this example.

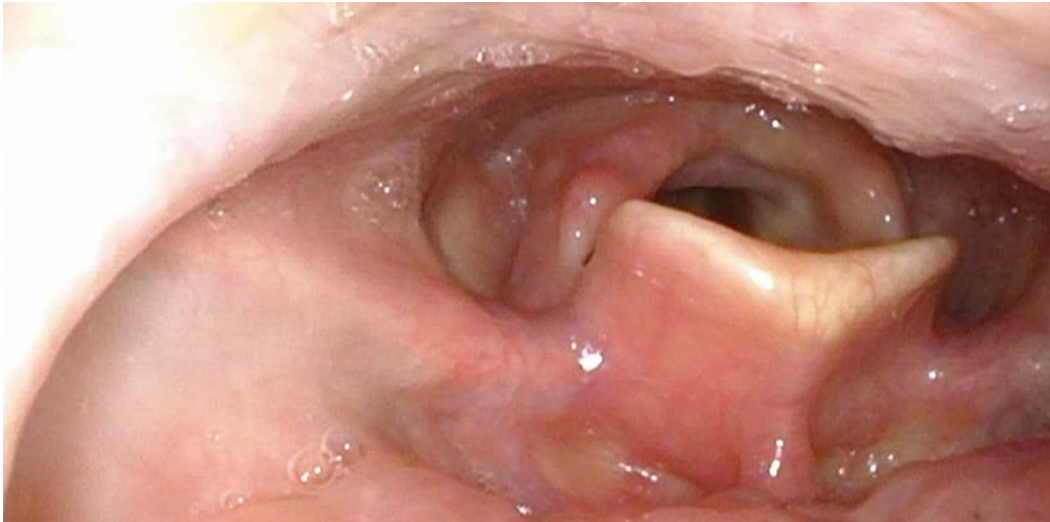

**Problem: The Epiglottis Disturbs**

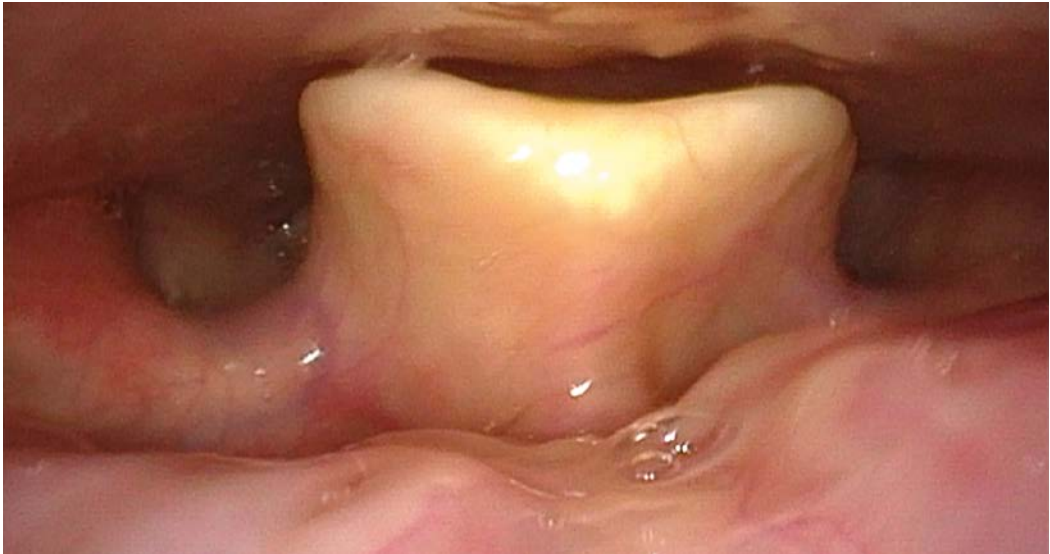The epiglottis may cover the glottic area while performing flexible endoscopy.

**Solution:**

- Advance flexible endoscope until it passes the level of the epiglottic rim.
- Phonation of “uuu” will shift the epiglottis into a more upright, vertical and anterior position.
- Ask patient to change the position of their head to sniffing position with cervical spine and jaw moved forwards (see below: Change of patient’s head position)



Flexible endoscopy, larynx seen from the level of the uvula



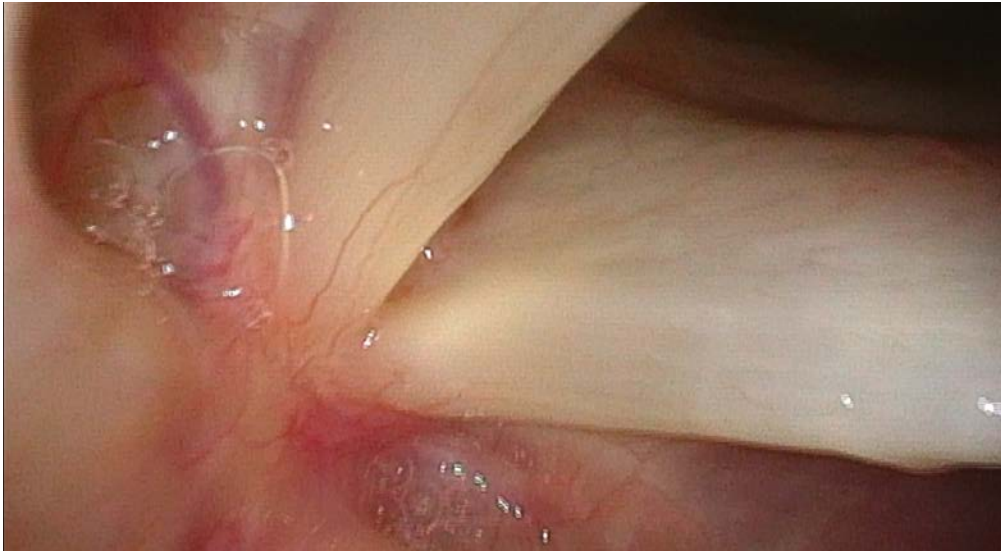
Epiglottis hiding vocal folds, patient’s head bent forward

**Problem: Need to Visualize Medial Surface of Vocal Fold**

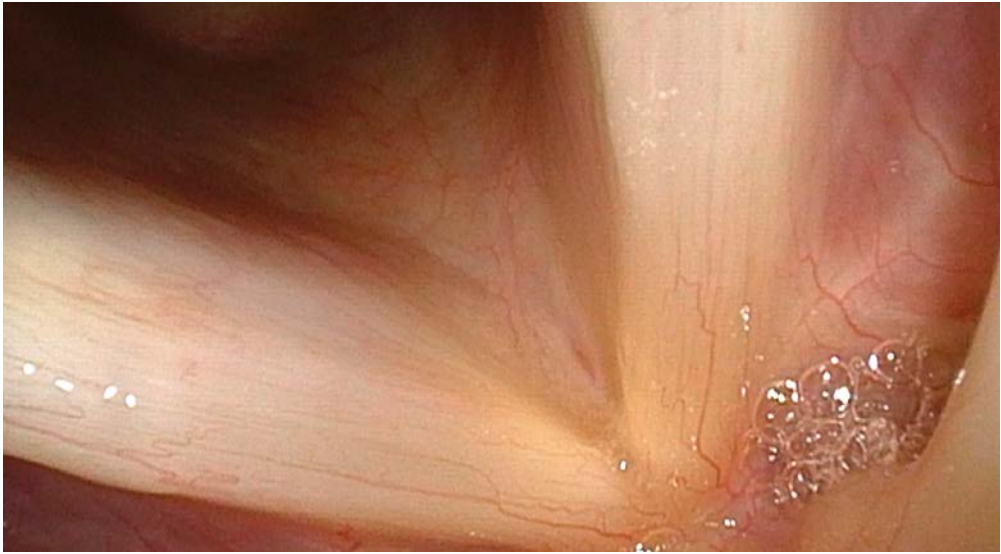The medial surface of the vocal fold cannot be visualized on flexible endoscopy.

**Solution:**

- Which nasal cavity is being used for the transnasal endoscopy? Try changing sides – right or left
- When deciding which nasal cavity side is most suitable for passing the flexible endoscope, consideration should be given not only to the size of the nasal cavities but also to the question of which vocal fold is of special interest. Select the right nasal cavity when you want a really good view of the left vocal fold and vice versa. (see chapter 3.3.: Anesthesia)



Passage through right nasal cavity: Left vocal fold can be seen better



Passage through left nasal cavity: Right vocal fold can be seen better

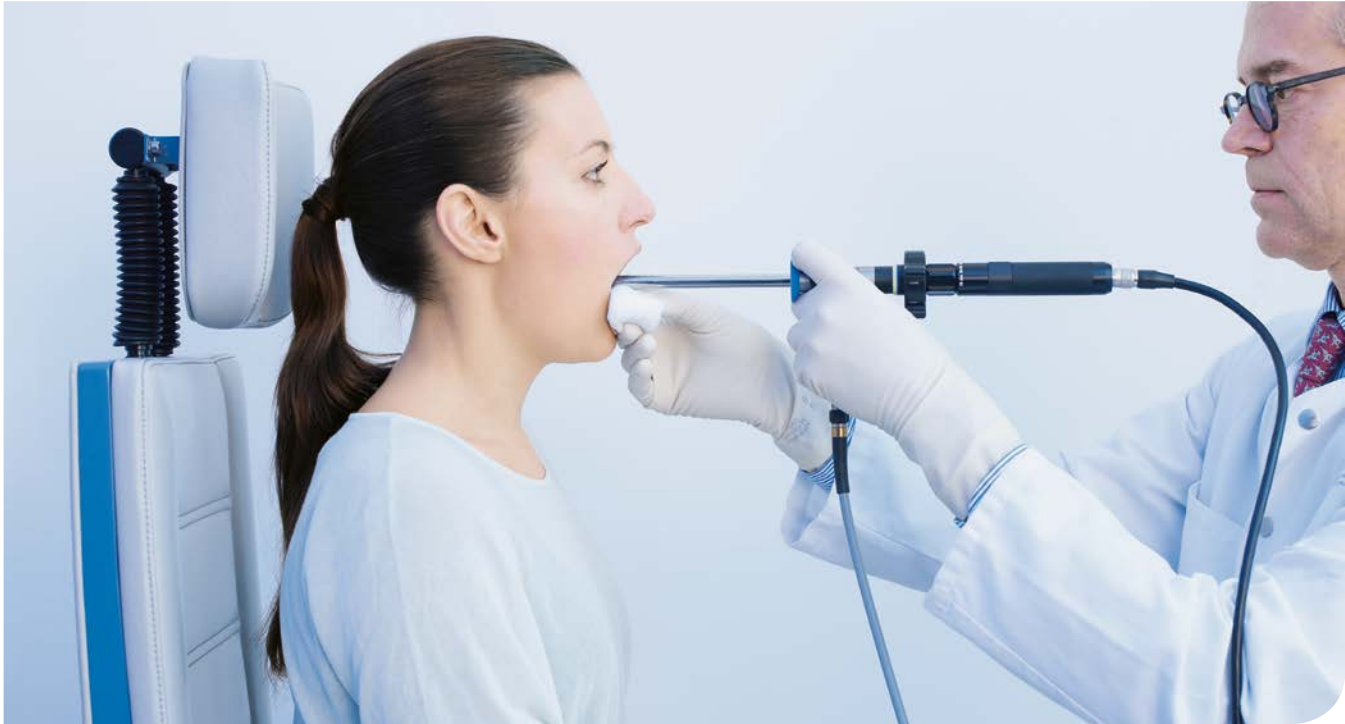

**Rigid Endoscopy - General Aspects of Positioning**

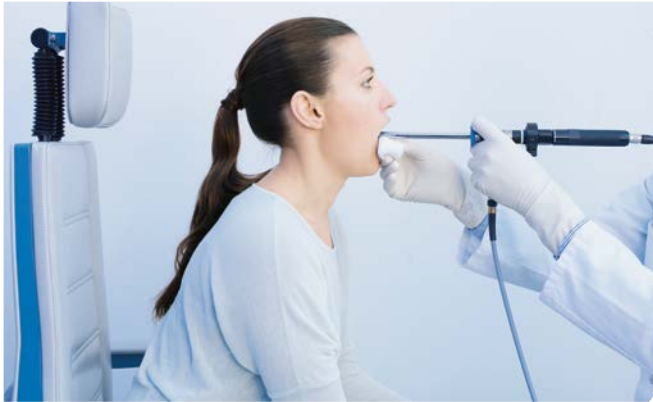- The position of the tip of the endoscope depends on patient's and examiner's posture.
- The position of the endoscope can be changed by different postures of the patient.
- Note the change of angle between endoscope and neck with different postures.
- For maximal anterior and posterior laryngeal exposures the positions of patient and examiner have to be changed accordingly.

**Elbows-on-Knees Position – 90° Rigid Endoscope**

- The 90° endoscope is typically held horizontally.



*Patient sitting, upper part of the body is straight and vertical*



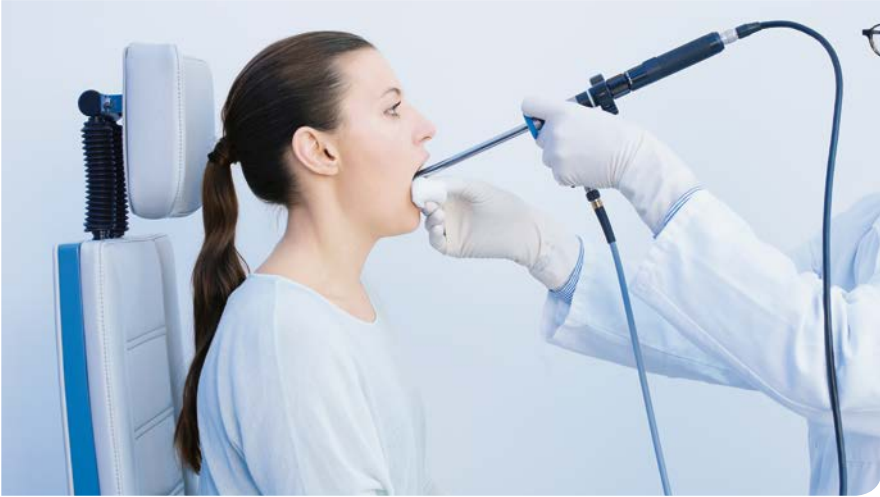*Patient sitting, upper part of the body slightly leaning forward, elbows on thighs*



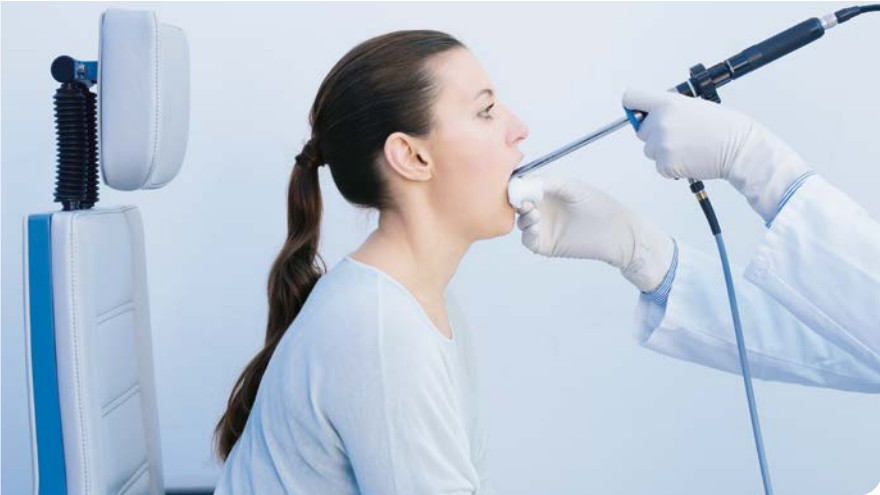*Patient sitting, upper part of the body strongly leaning forward, elbows on knees, neck hyperextended*

**Elbows-on-Knees Position – 70° Rigid Endoscope**

- The 70° endoscope is typically held steeper than the 90° endoscope.



*Patient sitting, upper part of the body straight and vertical*



*Patient sitting, upper part of the body slightly leaning forward, elbows on thighs*

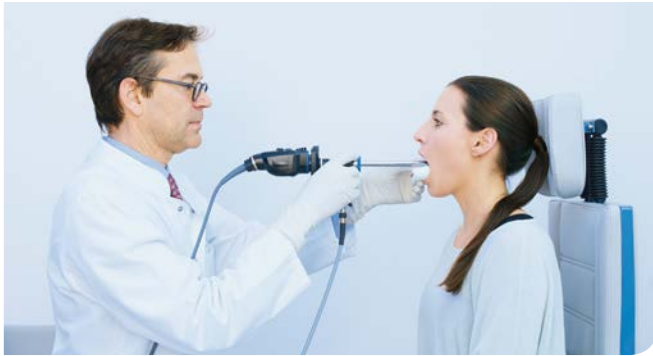

*Patient sitting, upper part of the body strongly leaning forward, elbows on knees, neck hyperextended. The axis of the endoscope almost points to the thoracic spine!*



Positioning of Patient and Examiner in Rigid Laryngoscopy

**Problem: Need to Visualize the Anterior Commissure or the Laryngeal Surface of the Epiglottis**  
Anterior commissure not visible



Normal position: Patient sitting, examiner sitting.

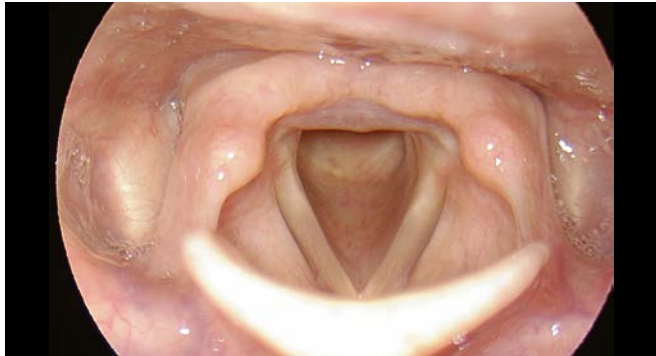


Image of larynx with normal position

**Solution:**  
Position according to **Türk:**  
· Patient sitting, examiner standing  
· Good for better view of anterior commissure  
· Use this position for the examination of the laryngeal surface of the epiglottis, too.

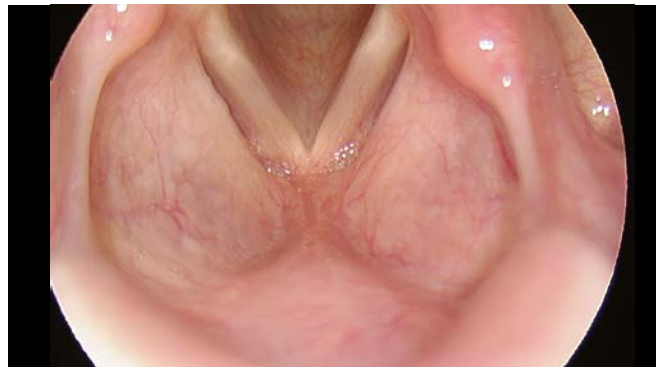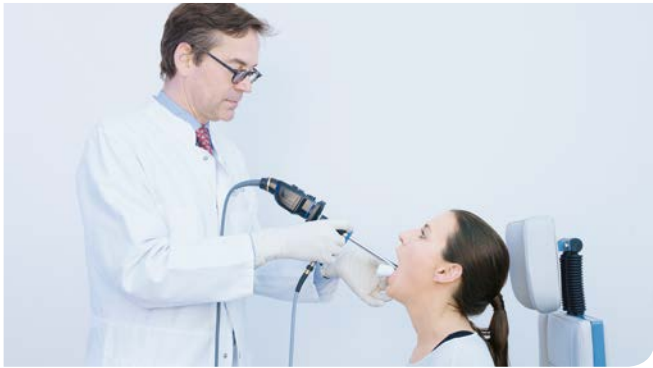



Image of larynx with position according to Türk

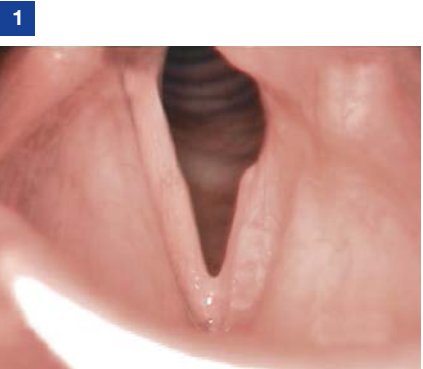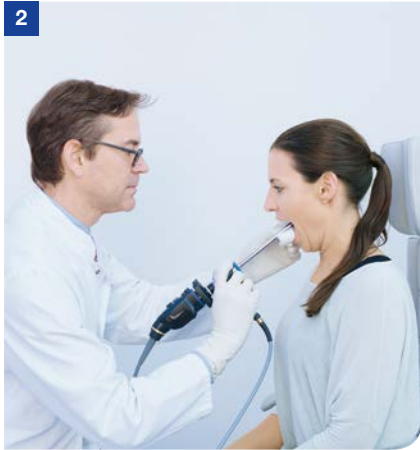Patient sitting, examiner standing (or sitting): In rigid endoscopy, the anterior commissure and the petiole can be visualized (position according to Türk).

**Problem: Suspected Posterior Glottic Stenosis (PGS)**  
Posterior larynx not visible

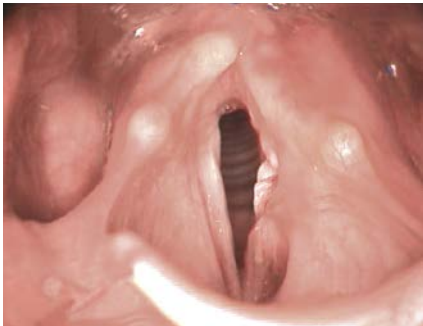**Solution:**  
Position according to **Killian:**  
- Patient standing, examiner sitting  
- Good for better view of posterior larynx  
- Use this position for ruling out posterior glottic stenosis (PGS) and scarring



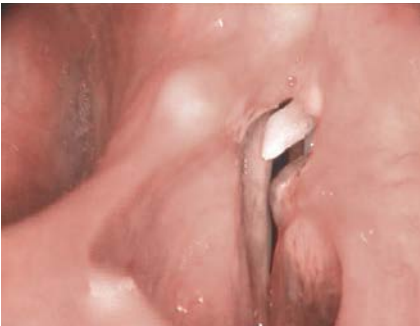1 Patient standing (or sitting), examiner sitting: In rigid endoscopy the posterior larynx and sometimes the entire trachea all way down to the carina can be visualized (position according to Killian).



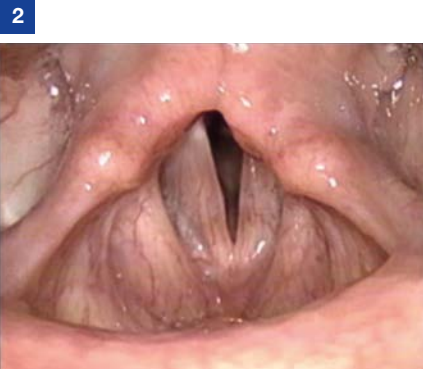
1a) Larynx after trauma seen with rigid endoscopy in normal position (respiration)



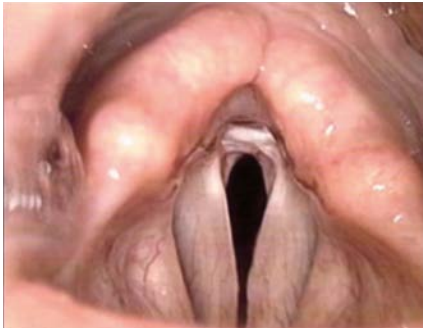1b) Same patient seen with rigid endoscopy according to Killian technique and endoscope held more to the left side. Now one can see that the trauma has ruptured the attachment of the vocal ligament to the vocal process (vocal fold avulsion).



1c) same as in b), during Falsetto phonation and with zoom. Displacement between vocal process and vocal ligament can be seen.



2a) Partial immobility of vocal folds. Here, maximum abduction is shown. Larynx seen with rigid endoscopy in normal position (respiration).

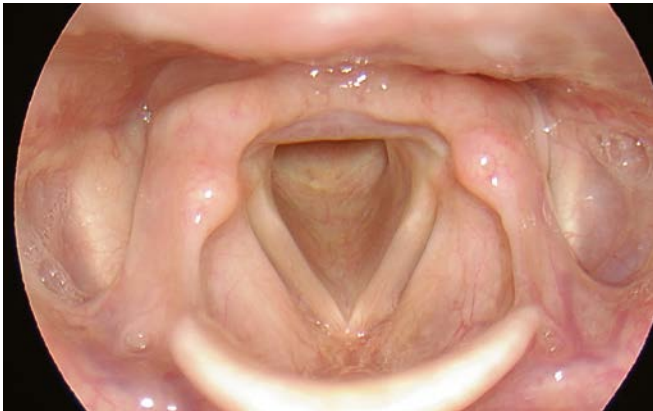

2b) Same patient seen with rigid endoscopy according to Killian technique. One can now see a scar bridge in the posterior larynx explaining the partial immobility of the vocal folds (posterior glottal stenosis).

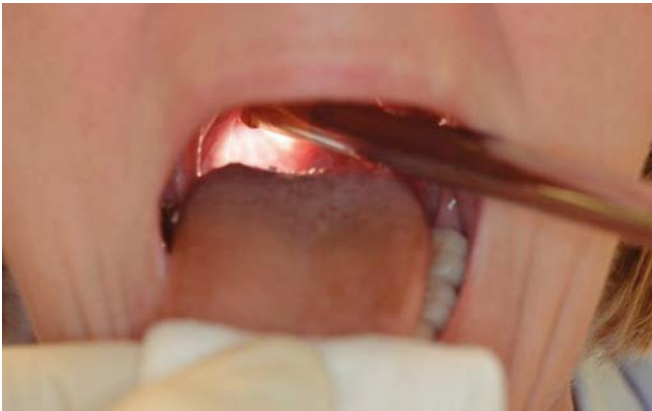**Note:**  
In flexible endoscopy these structures can be seen more easily – but only when the tip of the endoscope is close enough!



**Problem: Needing a Close-Up View of Vocal Folds or Anterior Commissure**  
How to obtain good quality close-up images of the glottis and anterior commissure using rigid endoscopy

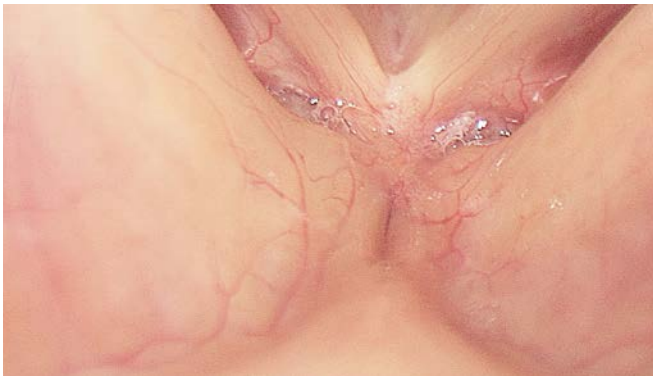


A) Larynx seen from the usual position of the 70° endoscope

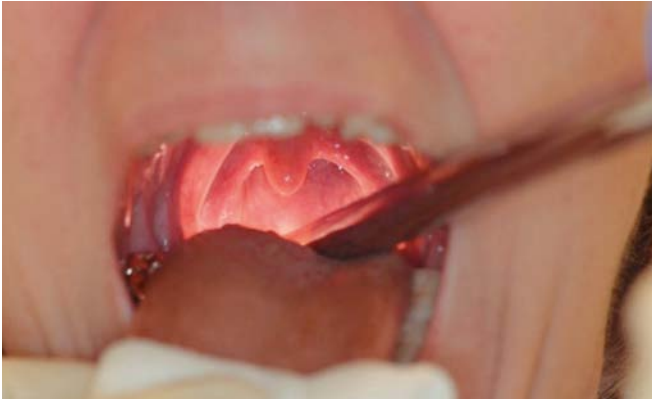

A) Normal position of the tip of a rigid endoscope within the oropharynx. For teaching purposes, the shaft of the endoscope was held in a pronounced lateral position in this picture.

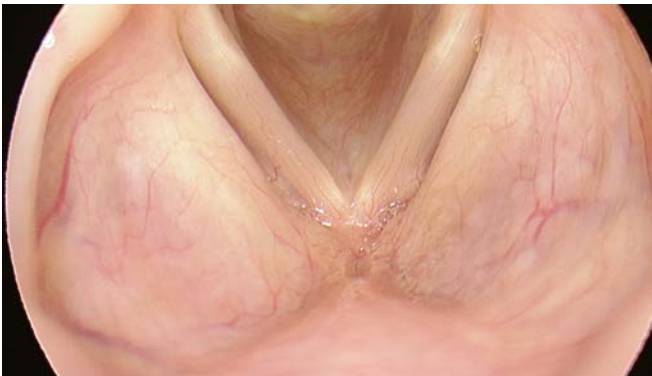- Solution:**
- Position the tip of the rigid endoscope just above the laryngeal inlet.
  - Placing the distal shaft of the endoscope on the tongue base and pressing it downwards enables you to get a closer view of the glottis.
  - This works particularly well when using the 70° endoscope, with which you can obtain a very close view of the glottis and (sometimes) a close view of the anterior commissure.
  - Try the elbows-on-knees position



If the patient can tolerate the more extreme positioning required for the 70° rigid endoscope you can also see the space between the petiole and anterior commissure.



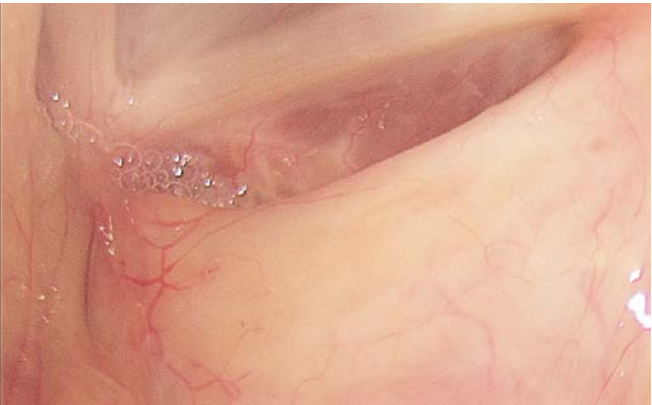
B) The tip of the endoscope has been positioned lower than in A), just above the laryngeal inlet. Again, for better demonstration purposes, the shaft of the endoscope is placed laterally.



B) The view of the larynx is magnified when the tip of the endoscope is positioned close to the glottis. This is achieved by pressing the shaft onto the tongue base. Note the excellent exposure of the anterior commissure.

**Problem: Need to Inspect Morgagni's Ventricle**  
How best to inspect Morgagni's ventricle (rigid endoscopy)

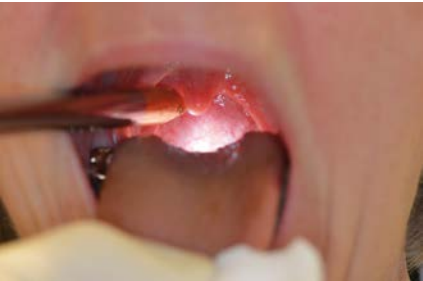- Solution:**
- Select a 70° rigid endoscope and have the patient sit in the elbows-on-knees position.
  - Anesthetize the pharynx and larynx thoroughly.
  - Dip the tip of the endoscope into the larynx by pressing the shaft onto the tongue base, advance it into the supraglottis and then rotate the tip towards the ROI.



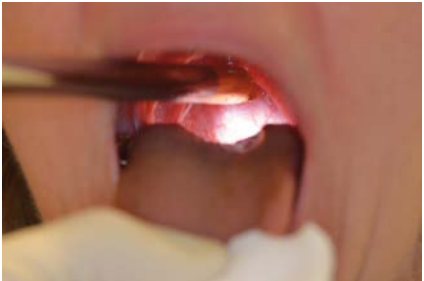If the patient can tolerate the more extreme positions required by the 70° rigid endoscope it may even be possible to obtain a glimpse into the ventricles of Morgagni.

**Problem: Need to Inspect the Piriform Sinus**  
How best to inspect the piriform sinus (rigid endoscopy)

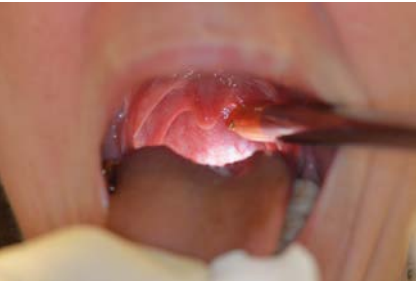- Solution:**
- You can change the axis of laryngeal visualization by employing different oropharyngeal positions for the endoscope in addition to simply rotating its tip.



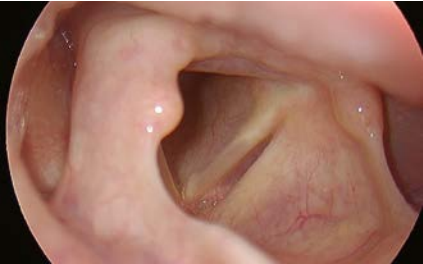A): Tip of the endoscope in right lateral position and rotated to the left



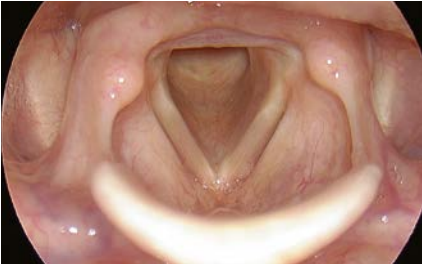B): Tip of the endoscope in the midline, not rotated



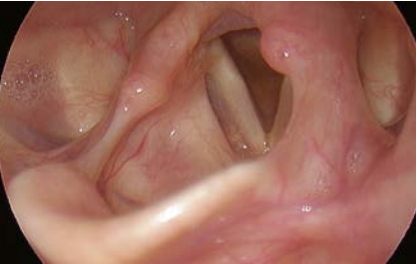C): Tip of the endoscope in left lateral position and rotated to the right



Larynx seen using technique (A)



Larynx seen using technique (B)



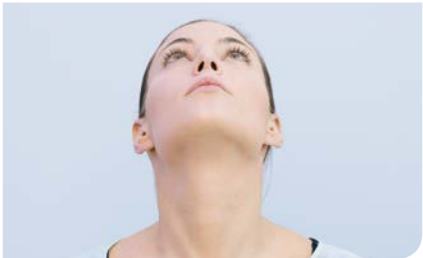Larynx seen using technique (C)



Change of the patient's head position



Head extended (chin lift) and turned to the right  
→ See left piriform sinus



Head extended (chin lift)



Head extended (chin lift) and turned to the left  
→ See right piriform sinus



Head bent to the right  
→ See left piriform sinus



Neutral position



Head bent to the left  
→ See right piriform sinus



Head turned to the right  
→ See left piriform sinus

**Problem: Need to Visualize Specific Pharyngeal Structures**

How best to expose specific pharyngeal structures

**Solution:**

Alter the position of the patient's head (especially in flexible endoscopy). Depending on the position of the patient's head it may be possible to achieve quite reasonable views of otherwise hidden parts of the pharynx.



Head turned to the left  
→ See right piriform sinus



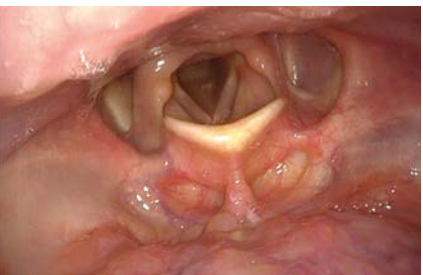Head bent forward and turned to the right  
→ See left vallecula and epiglottis



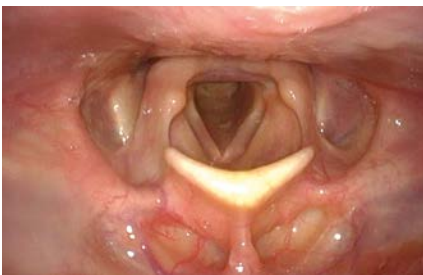Head bent forward  
→ See both valleculae and epiglottis



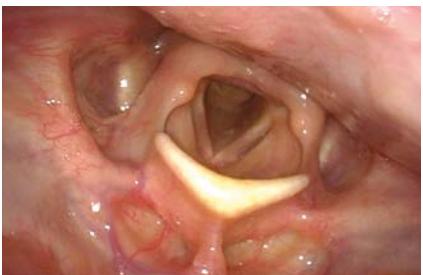Head bent forward and turned to the left  
→ See right vallecula and epiglottis



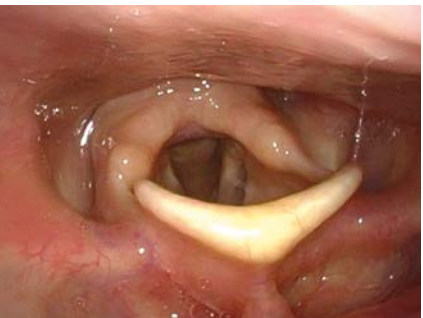Head extended and turned to the right



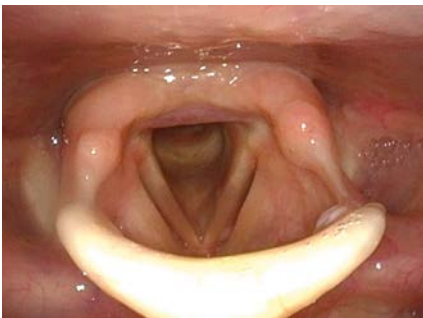Head extended



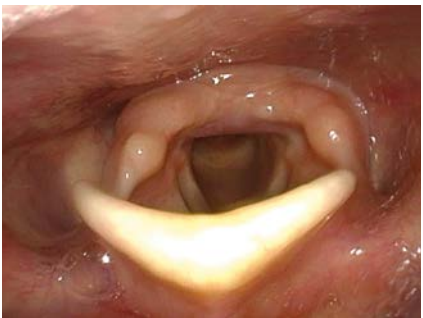Head extended and turned to the left



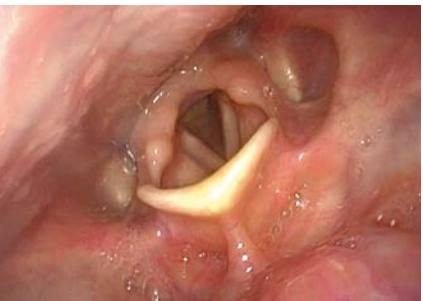Head bent to the right



Neutral position

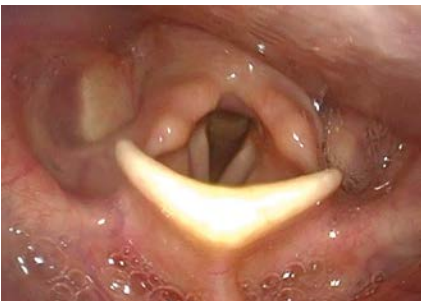

Head bent to the left

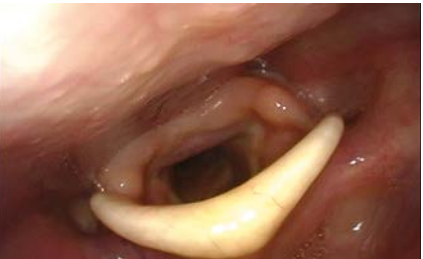

Head turned to the right

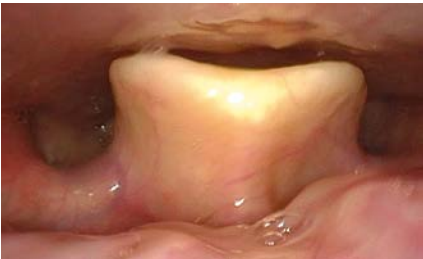Here, examples are shown how otherwise hidden parts of the pharynx can be visualized during flexible endoscopy when changing the patient's head position.



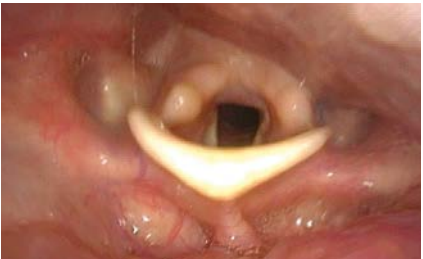Head turned to the left



Head bent forward and turned to the right

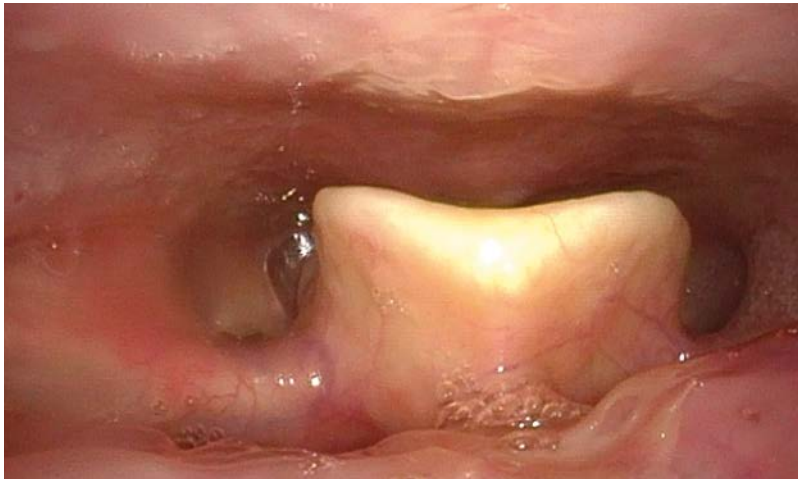



Head bent forward

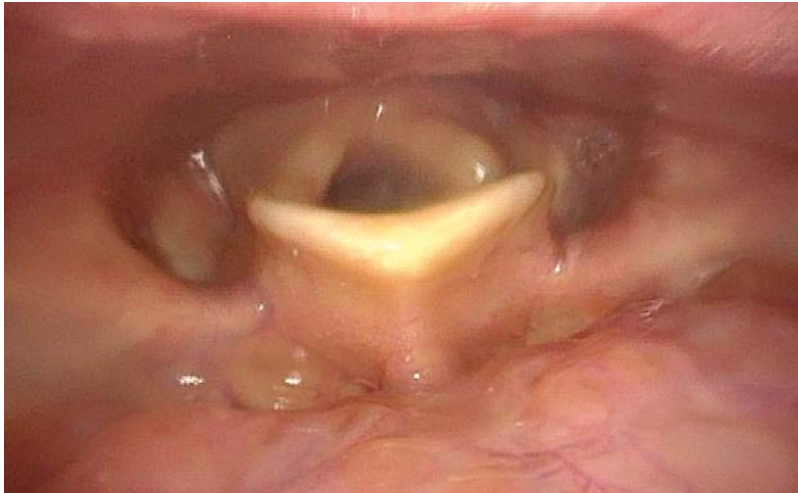

Head bent forward and turned to the left

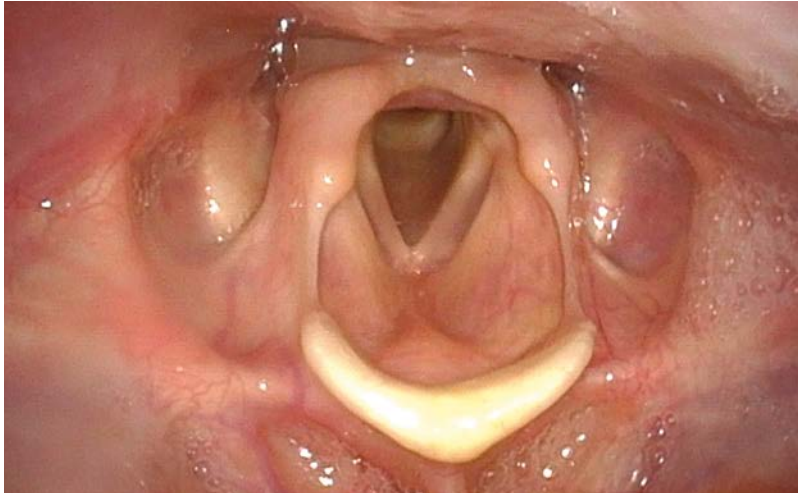




Cervical spine and jaw moved backwards. Pharynx is very narrow.



Habitual head position



Cervical spine and jaw moved forwards. Pharynx and larynx are open.

Table 6.1: How to Solve Special Problems

Rigid Endoscopy	
<b>Extensive gag response in spite of anesthesia</b>	Patient position: Elbows on knees Definitely breathe through the mouth! Close the nose, thus forcing breathing through the mouth Continue breathing, never holding breath Rapid panting Change from 90° to 70° rigid endoscope or to flexible endoscope Acupressure (Ren 24 Chengjiang, point in the middle of the mentolabial fold)
<b>Epiglottis hiding vocal folds</b>	Patient position: Elbows to knees Let patient phonate “eee” (best with strobe) Change phonation “eee” to “uuu” Ask patient to actively advance the mandible Change from 90° to 70° rigid endoscope or to flexible endoscope
<b>Vocal folds cannot be seen close enough</b>	Take 70° endoscope, steeper endoscope position
<b>Anterior commissure cannot be seen close enough</b>	Take 70° endoscope, push tip steeply downwards Position according to Türck
<b>Posterior larynx cannot be seen</b>	Position according to Killian
<b>One vocal fold cannot be seen because of perspective</b>	Change position of tip of endoscope sideways
Rigid and Flexible Endoscopy	
<b>Respiratory mobility unclear</b>	Try different phonatory and vegetative maneuvers, e.g. coughing
<b>Ventricular folds hiding vocal folds</b>	Change phonation “eee” to “uuu” Inspiratory phonation for assessment of mucosal movability
<b>Size of Reinke’s edema unclear</b> <b>Suspected mass lesion at free edge of vocal fold</b>	Repetitive forced and rapid inspiration Inspiratory phonation
<b>Mucus on vocal folds</b>	Repetitive throat-clearing / cough / inspiratory phonation
<b>Cough during close-up flexible endoscopy of vocal folds and trachea</b>	Anesthesia of larynx Forced, slow inspiration through nose (see Dipping Maneuver)
<b>Foaming</b>	Let patient swallow a spoonful of Dimeticon
<b>Endoscope blurred</b>	Cough Touch tongue base with tip of endoscope Swallowing as “wiper” (only flexible endoscopy)
<b>Overmodulated image</b>	Decrease light intensity Change from automatic to manual brightness control
<b>Question of vocal fold level difference</b>	Traditional examination with mirror
Flexible Endoscopy	
<b>Passage closed by velum</b>	Ask patient to breathe through his nose
<b>One vocal fold cannot be seen because of perspective</b>	Choose contralateral nasal cavity for access
<b>Vocal folds or anterior commissure or posterior glottis cannot be seen close enough</b>	Dipping maneuver, get close to ROI ! Let patient phonate “eee” and use stroboscopy
<b>Poor quality of image, “striped image”</b>	Minimize moiré by slightly defocussing (only fiberscope)



## STROBOSCOPY

# STROBOSCOPY

We would need a whole book to describe the technique of stroboscopy and all of its advantages. Unfortunately, it is only possible to cover some aspects in this section. Stroboscopy is an essential tool for the evaluation of mucosal waves and the pliability of the tissue of the vocal fold cover. Minor alterations in the normal waveform may provide the only sign that there is a mechanical problem. It may therefore help to distinguish organic voice disorders from functional disorders.

Some technical details should be considered:

- Check for different pitches and various loudness levels.
- Use moving mode and fixed mode.
- Most patients stop phonation after one or two seconds – that is too short for thorough evaluation of the vibratory functions.
- For example say to the patient: “Please give me an “eee” for 10 seconds.”
- Stroboscopy in patients with aphonia or with a very hoarse voice does not make sense.
- Voice recording and documentation of fundamental frequency and sound pressure level are essential – you want to know which sound was produced when assessing vocal fold vibration.
- See Table 5.2 for indications and advantages of stroboscopy.

**Useful Technical Terms in Stroboscopy**

- Pulsed vs. CW (continuous wave) light
- Halogen vs. xenon light
- Slow vs. fast motion
- Fixed vs. moving mode



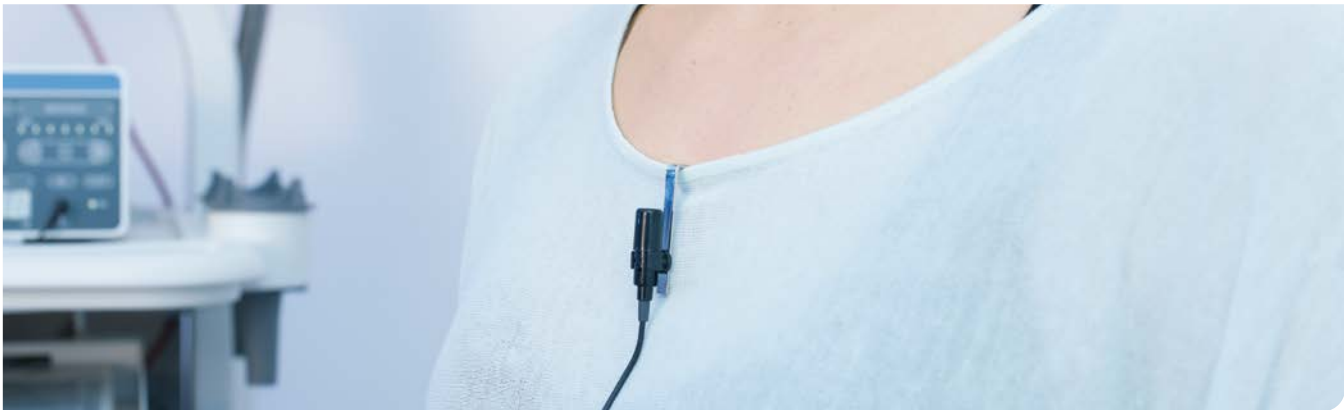Stroboscope: Front view



Frequency and sound pressure level are displayed on the stroboscope panel



When using a contact microphone to trigger the strobe flashes, it is important that the microphone is in close contact with the skin next to the larynx. Loose contact is a common cause of poor synchronization. Be prepared to correct the position of the microphone during examination. Note that the microphone can be placed over either thyroid ala or even further laterally (e.g. left or right) – see photo above.



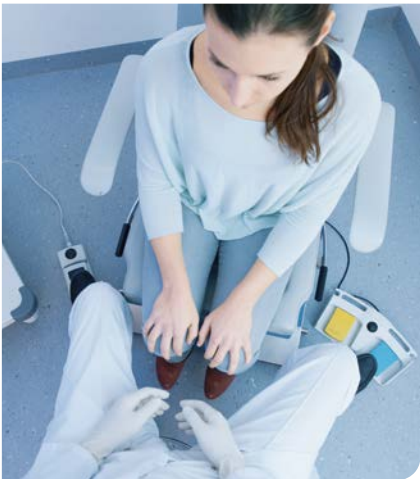When using a clip microphone – do not place it too far from the mouth. This neck position frequently works well. Additionally, setting the microphone too close to the mouth may produce artifacts due to turbulent airflow.



The foot pedal should be placed close enough to the examiner to ensure a stable standing or sitting position.



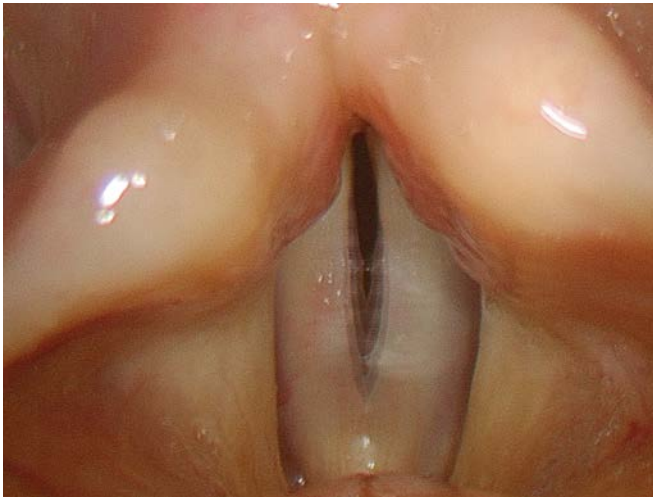A foot switch is important for changing your light source. If your instrumentation provides optional changing between fixed vs. moving stroboscopic imaging modes, check which mode is being used and how to switch between the modes (see arrow).



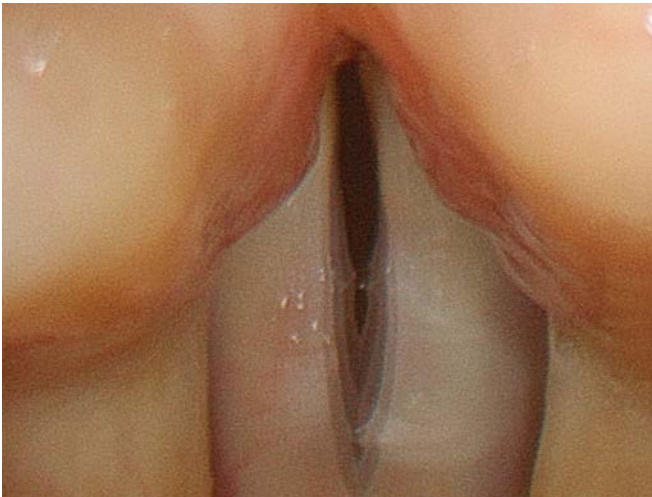
Foot pedals on both sides of the patient.



Important Criteria in Stroboscopy:	
→ <b>Symmetry of Vocal Fold Movement</b>	→ <b>Mucosal Wave</b>
- Phase symmetry / asymmetry, phase difference	- Symmetrical / asymmetrical
- Abnormal modes of vibration	- Normal / diminished / extended
- Alternating vibration	- Absent
→ <b>Periodicity of Vocal Fold Movement</b>	→ <b>Glottic Closure (vocal fold closure)</b>
→ <b>Regularity of Vibration</b>	- Complete / incomplete
→ <b>Amplitude of Vocal Fold Movement</b>	→ <b>Open Quotient</b>
- Symmetrical	→ <b>Glottal Gap</b>
- Normal / diminished / extended	- Posterior / anterior / elliptical / hourglass
- Absent	→ <b>Nonvibratory Mucosa / Stiffness</b>

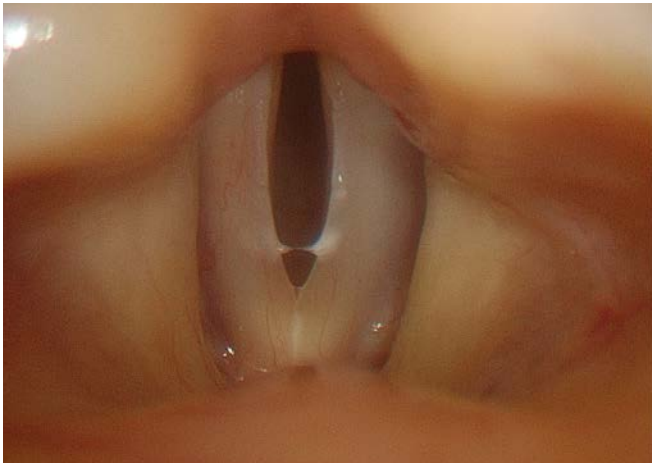
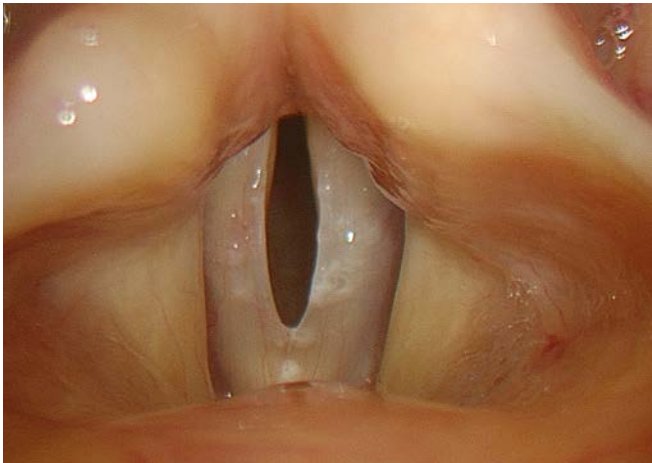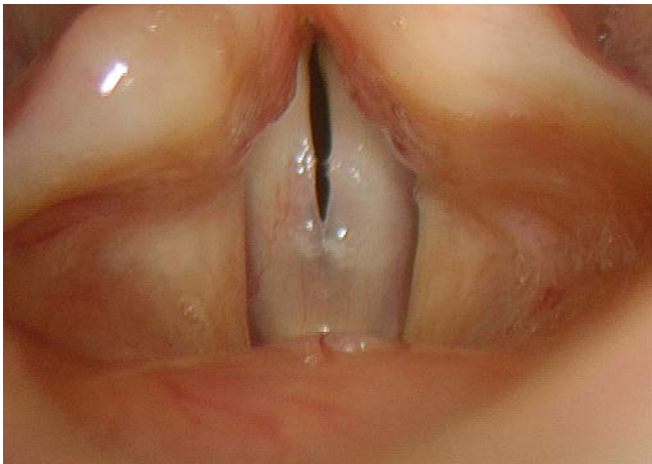
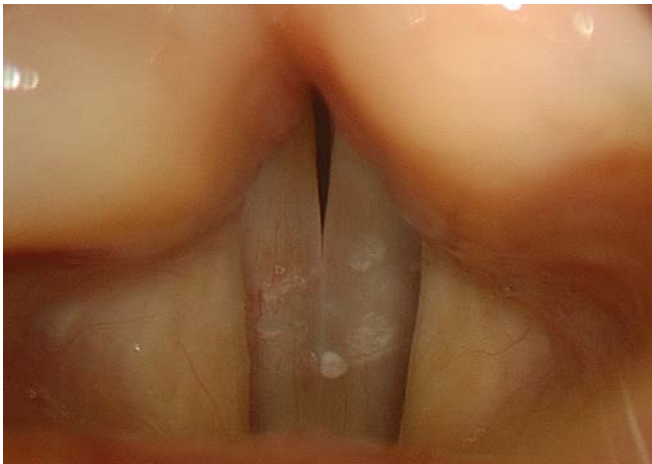
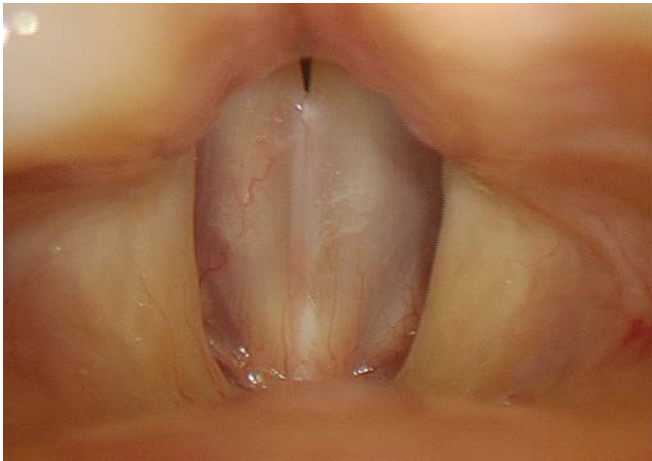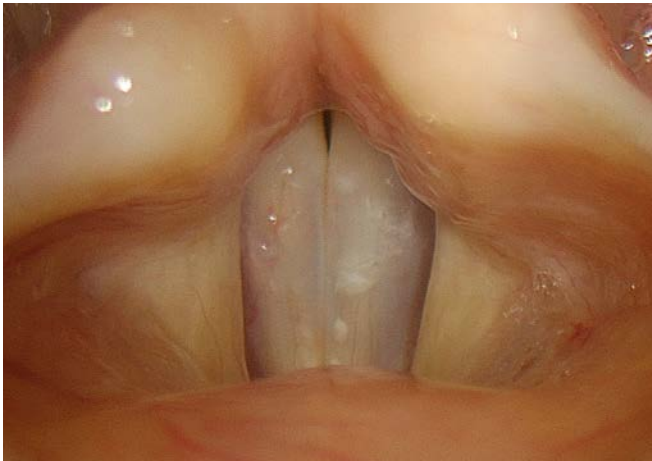


Multiple exposures, mostly due to impaired triggering



Same artifact as in previous image

Alternatives:
Alternatively to stroboscopy, imaging of the vibratory behavior of the vocal folds is possible with video kymography (VKG) and high-speed imaging.



Images obtained using a stroboscopic flashlight source have a slightly more blue quality than those obtained using a continuous wave light source. This discrepancy can easily be corrected by digital image processing. In addition, the images may be somewhat darker than those obtained using a continuous light source. Image quality is generally improved by getting the tip of the endoscope as close to the vocal folds as possible.

## OFFICE-BASED PHONOSURGERY



OFFICE-BASED PHONOSURGERY

In office-based phonosurgery various procedures can be performed. All of them depend on good technical imaging skills during laryngoscopy.

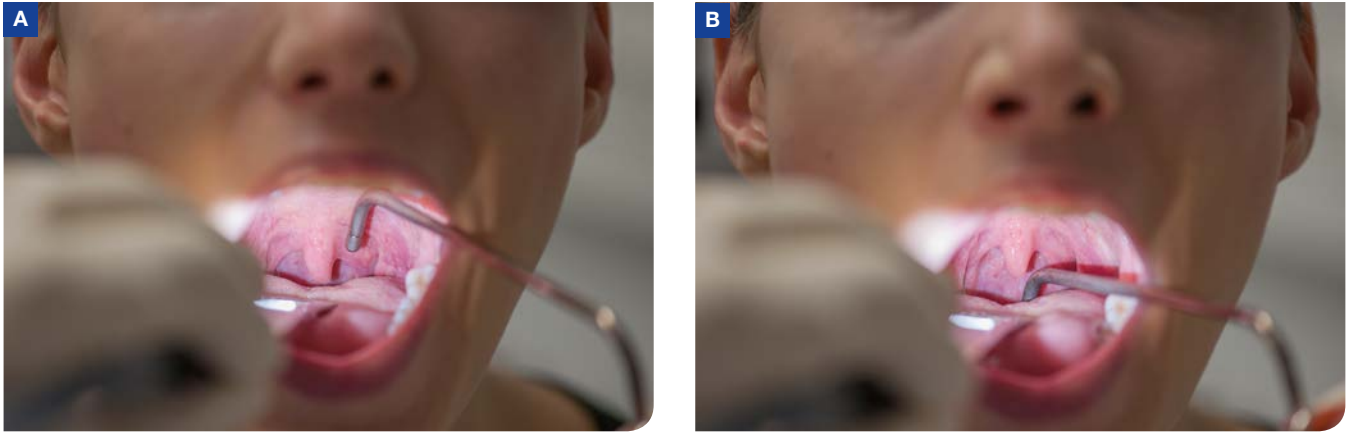
- The transoral approach has been used for more than one hundred years. For excision of tiny lesions, a high level of magnification is very helpful. Here the 90° rigid endoscope with zoom has advantages. For other purposes the 70° rigid endoscope has the advantage of a good overview and does not need refocusing when changing the position during endoscopy.
- With the transnasal approach, procedures such as laser treatment can be performed. Excisions or injections are also possible, but with this technique the procedure may be less precise compared to the transoral technique.
- For percutaneous vocal fold augmentation, the visualization of the glottis with transnasal flexible endoscopy is very helpful. This approach needs two surgeons.
- Another possibility is splitting the surgical transoral approach and transnasal endoscopic visualization. This approach needs two surgeons.

Table 8.1 Phonosurgical Office-Based Procedures

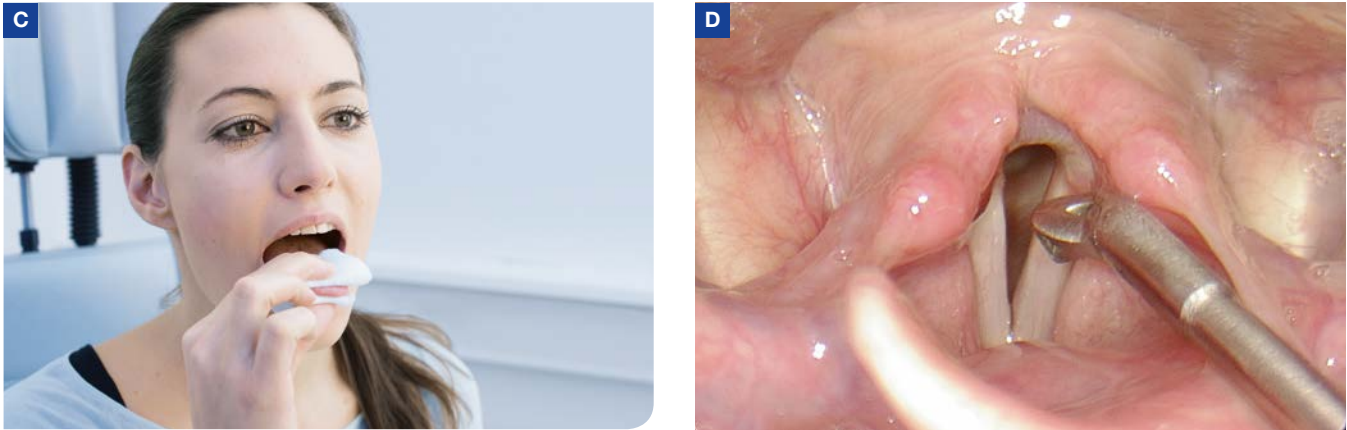
	Rigid Transoral	Flexible Transnasal	Percutaneous Procedure with Transnasal Visualization
Excision	+	(+)	-
Biopsy	+	+	-
Augmentation	+	(-)	+
Injection (e.g. steroids, botulinum toxin)	+	+	+
Laser	+	+	-

+ = suitable access for specific procedure  
(+) = sometimes suitable


8.1. Phonosurgery, Rigid Transoral Procedure



Topical anesthesia before indirect transoral intervention; A) Oro- and hypopharynx; B) Endolarynx (spatula was used in this case to expose the posterior oral cavity for didactic purposes only – otherwise it is done with tongue protruded, see C)



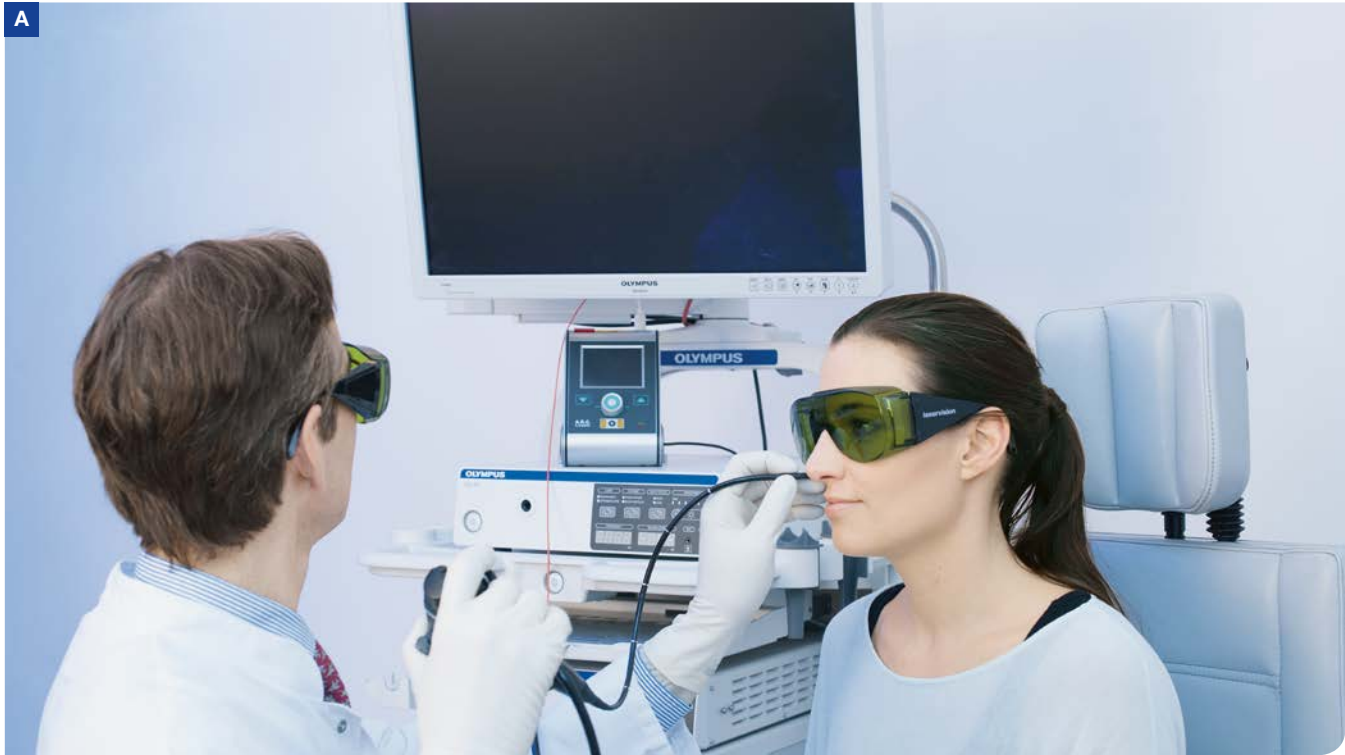C) Patient holds own tongue so that surgeon has both hands free for intervention. D) Instrument transorally routed, visualized with 70° rigid endoscope



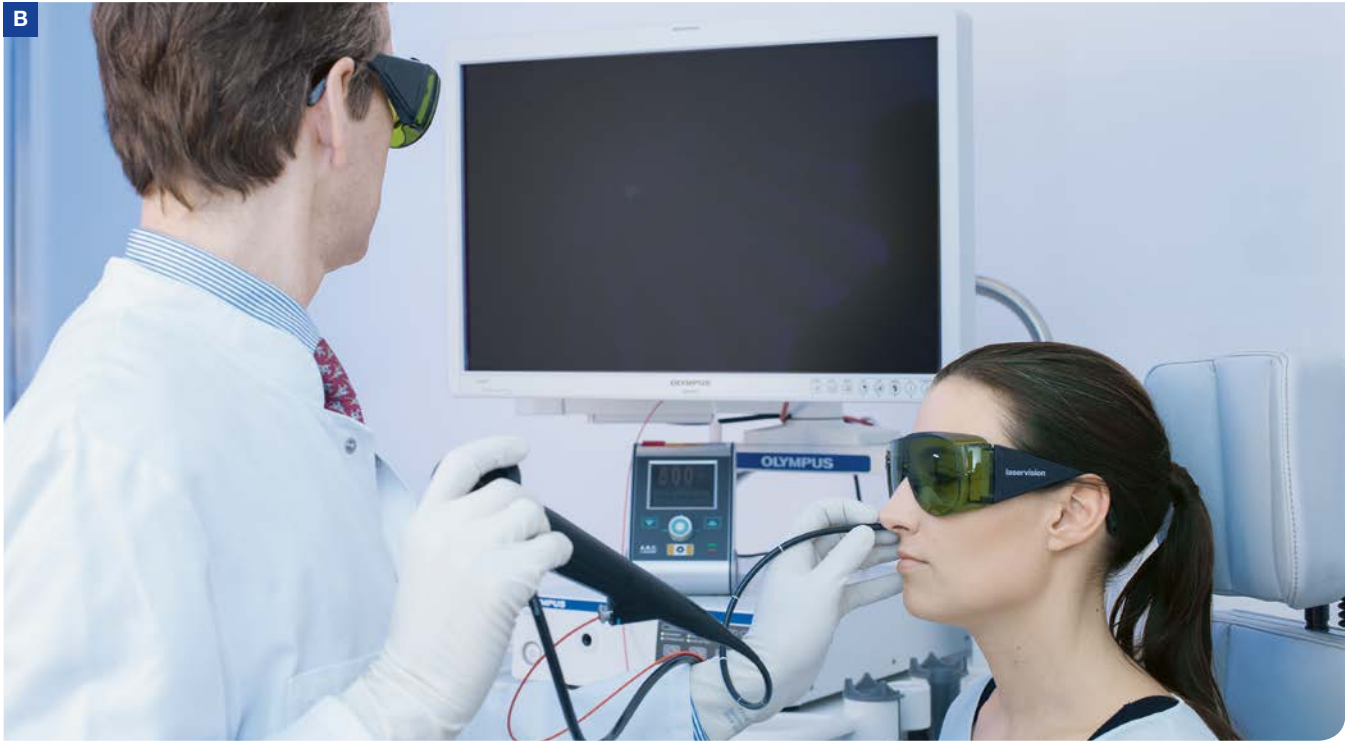E) Surgeon visualizes tip of curved instrument via video endoscope and monitor display. Patient holds own tongue. F) Same procedure as in (E). Here, laser safety measures are taken. Surgeon activates laser via foot pedal (not displayed).



8.2. Phonosurgery, Flexible Transnasal Procedure

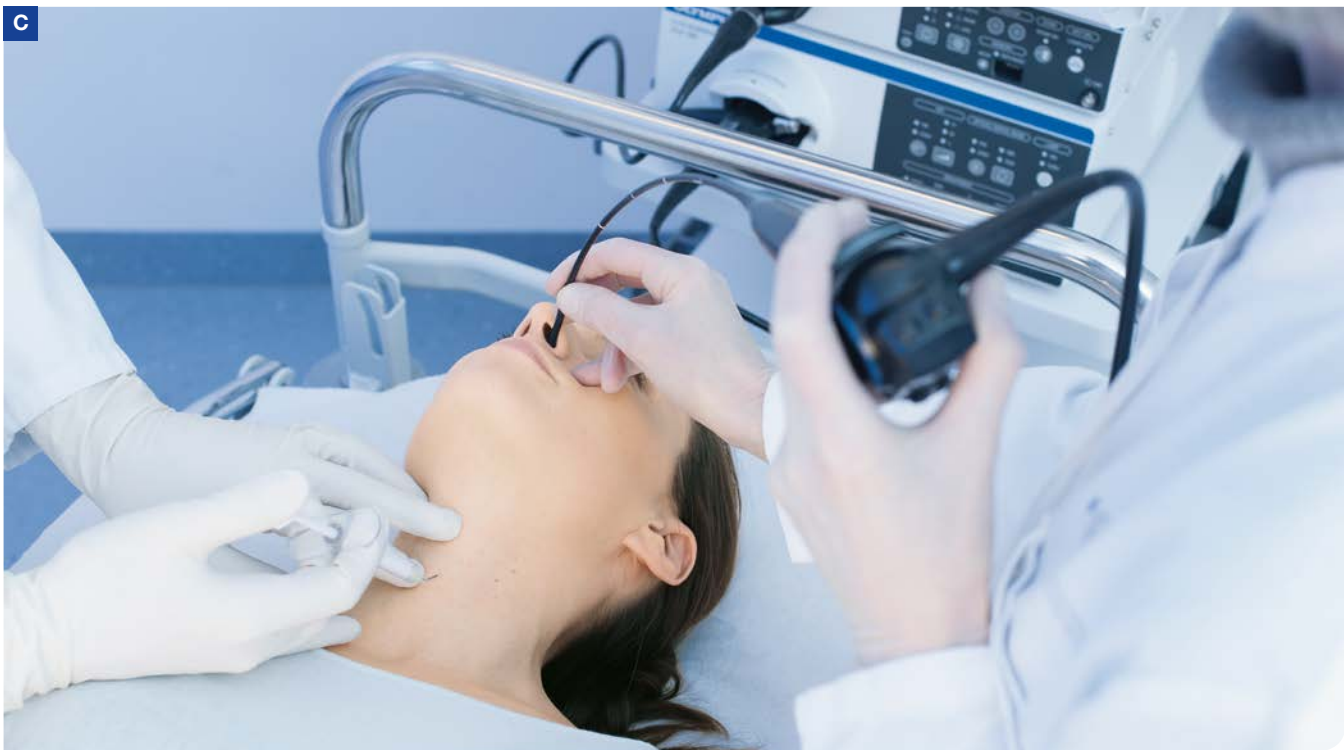
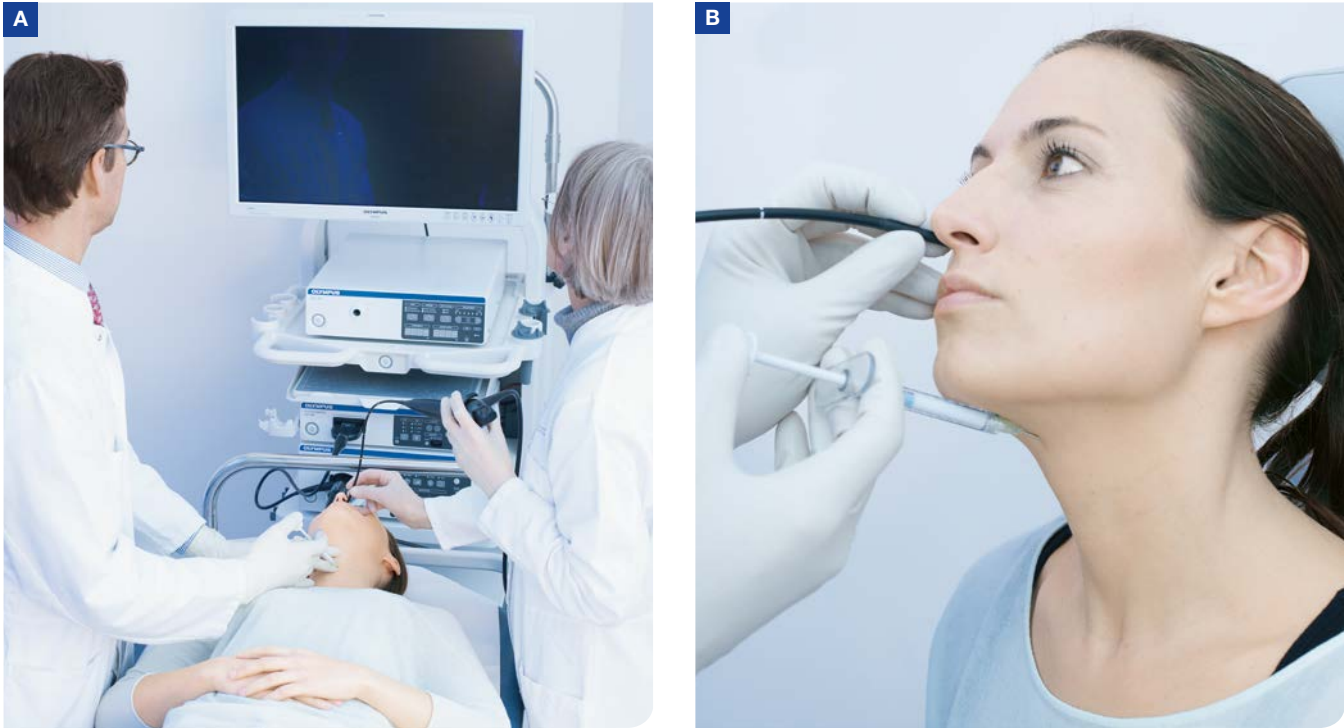

A) Transnasal laser surgery of larynx. Surgeon can handle entire procedure without an additional endoscopist because glass fiber can be advanced by surgeon. Laser activation via foot pedal.



B) Same procedure as in (A). Here, surgeon is standing to hold his arms more comfortably within a longer lasting intervention.

8.3. Phonosurgery, Percutaneous Procedure with Transnasal Visualization



A–C) Percutaneous augmentation.  
A, C) Surgeon (left) injects (here: Cricothyroid approach). Positioning of needle is monitored with the help of an endoscopist (right).  
B) Demonstration of needle position and angulation for thyrohyoid approach. Here, surgeon supports advancement of endoscope. Nevertheless, this procedure needs an endoscopist (not displayed in B).



## ACKNOWLEDGEMENTS / DISCLOSURE / THE AUTHORS

# ACKNOWLEDGEMENTS

This manual was made possible by the support of many people and institutions. Olympus Medical offered support by giving us the freedom to choose both the style and content of this manual. Special thanks go to Thomas Gruteser, who was not only excited from the very beginning when the idea came up, but who also helped us on many occasions – and who finally accepted our proposal when we decided to enlarge the manual from a brochure format to a little book. Marc Simon was patient and helpful in his media coordination for this manuscript and in communicating every wish to the agency PROFIREPRO.

Janina Stade was our ideal patient-model for almost all the pictures and survived the photo shoots, which involved being subjected to approximately 20 hours worth of mimicked endoscopy sessions. She even continued to smile right up to the very last photograph. She did a tremendous job!

We are indebted to Tom Harris who read multiple versions of the manuscript and helped enormously with the English wording.

We cannot adequately express our thanks to all supporters and helpers in the way they deserve, and we hope that mentioning their names will be accepted as acknowledgment:  
All patients that helped us to improve our endoscopy technique while tolerating our efforts to visualize the larynx; Frank Müller; Stefan Noster; Frank Möbius; the children in chapter 4.6.; Daniel Schroeder; Peter-Christian Vorreiter (Olympus); the Olympus photographic team comprised of Marc Simon (Media Coordinator), Georgia Macrae-Otten (Brand Manager), the photographer J. Konrad Schmidt, the team of PROFIREPRO GmbH; the team of the Deutsche Stimmklinik.

## Disclosure

The authors confirm that there were no conflicts of interest when writing this manuscript. There are no financial relationships with any commercial interest relating to the content of the manuscript, and the authors have nothing to disclose.

Reprints of endoscopic images with kind permission of DEUTSCHE STIMMKLINIK Management GmbH.

# THE AUTHORS


Susanne Fleischer, MD, specializes in digital laryngoscopy, stroboscopy and the clinical diagnosis and management of organic and functional voice disorders.

Markus Hess, MD, specializes in diagnostics and therapy of voice disorders and phonosurgery. He has earned a worldwide reputation as a leading phonosurgeon and has contributed to several leading textbooks and published numerous articles on related subjects.


Academically, both authors are affiliated with the University Medical Center Hamburg Eppendorf, UKE, Department of Voice, Speech and Hearing Disorders. Together with Frank Müller they founded the first multidisciplinary voice clinic in Germany, the DEUTSCHE STIMMKLINIK ([www.stimmklinik.de](http://www.stimmklinik.de)), which is located in Hamburg on the grounds of the UKE.



Universitätsklinikum  
Hamburg-Eppendorf



DEUTSCHE  
STIMMKLINIK





SPECIALIZED TECHNICAL EQUIPMENT

# SPECIALIZED TECHNICAL EQUIPMENT

## High Definition (HD)



### What Is HDTV?


HDTV (high-definition television) refers to a TV broadcasting format capable of displaying very clear images using an increased number of scanning lines.

### What Is the Benefit of HDTV?

- Approximately four times the volume of information of a standard quality video.
- High-resolution images.


## Volume of Information

SDTV



480 (NTSC) or 576 (PAL) scanning lines are effective

HDTV



1080 scanning lines are effective

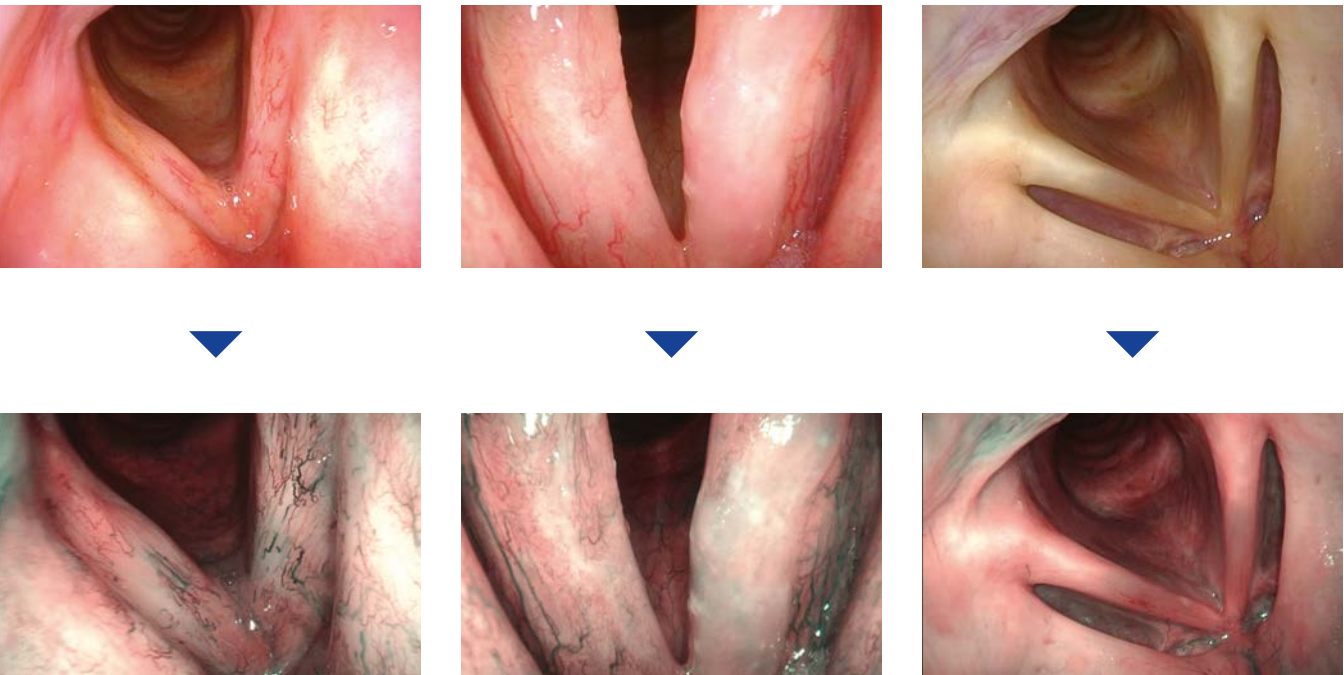
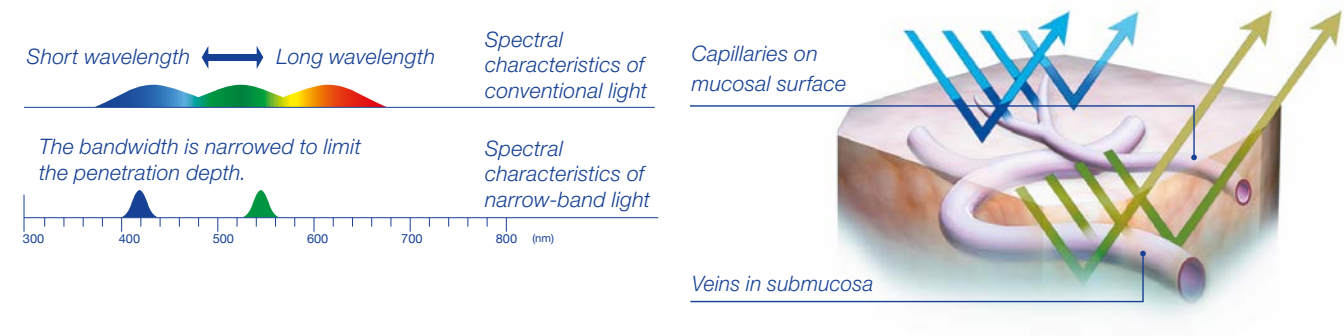Approx. 2x

## Narrow Band Imaging (NBI)



NBI is an optical image enhancement technology that improves the visibility of vessels and other tissues on the mucosal surface. Narrow-band illumination, which is strongly absorbed by hemoglobin and penetrates only the surface of tissues, is good for enhancing the contrast between the two. As a result, under narrow-band illumination, capillaries within the mucosal surface are displayed in brown on the monitor while veins in the submucosa are displayed in cyan. Other companies also provide imaging with filtered light.

## Penetration Depth of Light According to Wavelength





## PREPARATION, CLEANING, AND HYGIENE

# GENERAL REMARKS

## Classification of Guidelines

- Flexible endoscopes used for ENT examinations are classified as semicritical medical devices.
- Semicritical device contact with the mucous membranes or superficially damaged skin.
- Semicritical device should undergo cleaning and disinfection after each patient.
- The goal is to bring the endoscope up to a level of safety at which it does not represent a means of transmission of pathogenic microorganisms or other potentially dangerous chemical substances for both the patient and the staff.

**References: National Guidelines and Recommendations for ENT Endoscopes:**

- **Germany:**  
Robert Koch Institut: Anforderungen an die Hygiene bei der Aufbereitung von Medizinprodukten (2012).
- **United Kingdom:**  
Department of Health – Decontamination of flexible endoscopes –Decontamination of nasendoscopes (2013).
- **United States of America:**  
Step-by-step guidelines for reprocessing flexible laryngoscopes (2007).

## Cleaning

- Prior to any disinfection procedure, ENT endoscopes need to undergo accurate cleaning.
  - Removal of all visual debris is important to achieve sufficient disinfection efficacy.
  - Use only detergents dedicated for medical endoscopes.

# CHEMICALS FOR DISINFECTION

## Chemicals for Disinfection

- Always use the disinfectant solution according to the manufacturer’s instructions for achieving proper disinfection efficacy (contact time, concentration and temperature).
  - **Glutaraldehyde (GA):** Glutaraldehyde products are provided under a variety of brand names and are available in a variety of concentrations. Glutaraldehyde solutions range in concentration from 2.4–3.4 and have varied maximum reuse lives. Glutaraldehyde has excellent biocidal activity, is active in the presence of organic matter and is noncorrosive to metals, rubbers and plastics. However, glutaraldehyde can fix proteins and allows for biofilm formation. Glutaraldehyde is suspected to enhance allergic reactions or disease when it gets in direct contact with vapor or fumes. Glutaraldehyde has limited or no sporicidal efficacy.
  - **Orthophthalaldehyde (OPA):** Orthophthalaldehyde 0.55% is a disinfectant and demonstrates good microbiocidal activity. Like glutaraldehyde, orthophthalaldehyde fixes proteins and allows for biofilm formation. Orthophthalaldehyde has only limited allergic impact to users. However, reports from the U.S. show potential risk for disease to patients where residual OPA remains on instruments.
  - **Peracetic acid (PAA):** Peracetic acid has a wide spectrum of activity. It allows fast, efficient and reproducible inactivation of all relevant microorganisms. Unlike GA and OPA, peracetic acid is not supposed to cause allergic reactions on patients and staff. PAA has additional potential for sporicidal efficacy.

**Please Note:**

- Alcohol is not accepted as disinfectant for medical devices. It is therefore not suitable to use it for the disinfection of an ENT endoscope. 70% ethyl or isopropyl alcohol can be used for an enhanced drying phase after disinfection.
- If the disinfectant solution is reused, routinely check its efficacy with a test strip recommended by the manufacturer. Do not use solutions beyond their expiration date.

## Use of an Inappropriate Chemical Can Easily Result in a Damaged Endoscope






# MANUAL REPROCESSING OF A FLEXIBLE ENDOSCOPE WITHOUT A WORKING CHANNEL

**Precleaning**

**1 Wipe the Insertion Tube**




Gently wipe the external surfaces of the insertion tube with a cloth moistened in detergent solution.

**!** This guide is only a summary of steps necessary to properly reprocess your endoscope. Follow the detailed steps outlined in the ENDOSCOPE REPROCESSING MANUAL that was included with your endoscope.

Use only those detergent / disinfectant solutions in processes which have been validated for sterilizations in accordance with national and local regulations and/or guidelines.


**Leakage testing**

**2 Attach the Tester**




Attach the leakage tester to the venting connector on the endoscope.

**3 Apply Pressure**



Automatic leakage tester


Connect Leakage tester to the maintenance unit or the light source and turn the power switch on.



Manual leakage tester

Close the pressure release lever. Press the hand pump so that the pointer stays within the green area.


**4 Observe**



Immerse the entire endoscope in water, observe for 30 seconds while angulating the bending section and confirm that there is no continuous trail of bubbles.

**CAUTION:** If a leak is detected, remove from water and contact the manufacturer.

**5 Detach the Tester**



Remove the endoscope from the water and release the air pressure in the endoscope.

When using manual leakage tester, open the pressure release lever.

When using automatic leakage tester, turn the maintenance unit or light source off. Detach the leakage tester from the air source and then the endoscope.

**Manual Cleaning**

**6 Clean the Surface**



Immerse the endoscope in detergent solution. Using a lint-free cloth, gently wipe all debris from the endoscope's external surfaces. Soak in detergent solution for the recommended time.

**7 Rinse the Endoscope**



Immerse the endoscope in water. Using a clean, lint-free cloth, thoroughly rinse and wipe the endoscope.


**8 Wipe the Surfaces**



Remove the endoscope from water. Use a soft, lint-free cloth to remove excess moisture from the endoscope and cleaning accessories in preparation for disinfection.

**Disinfection**


**9 Disinfect the Endoscope**



Immerse the endoscope in the disinfectant solution. Soak for the time specified by the manufacturer.


**Rinsing**

**10 Rinse the Surfaces**




Remove the endoscope from the disinfectant solution and immerse in deionized water. Using a sterile, lint-free cloth, thoroughly rinse and gently wipe all external surfaces.

**11 Wipe the Surfaces**



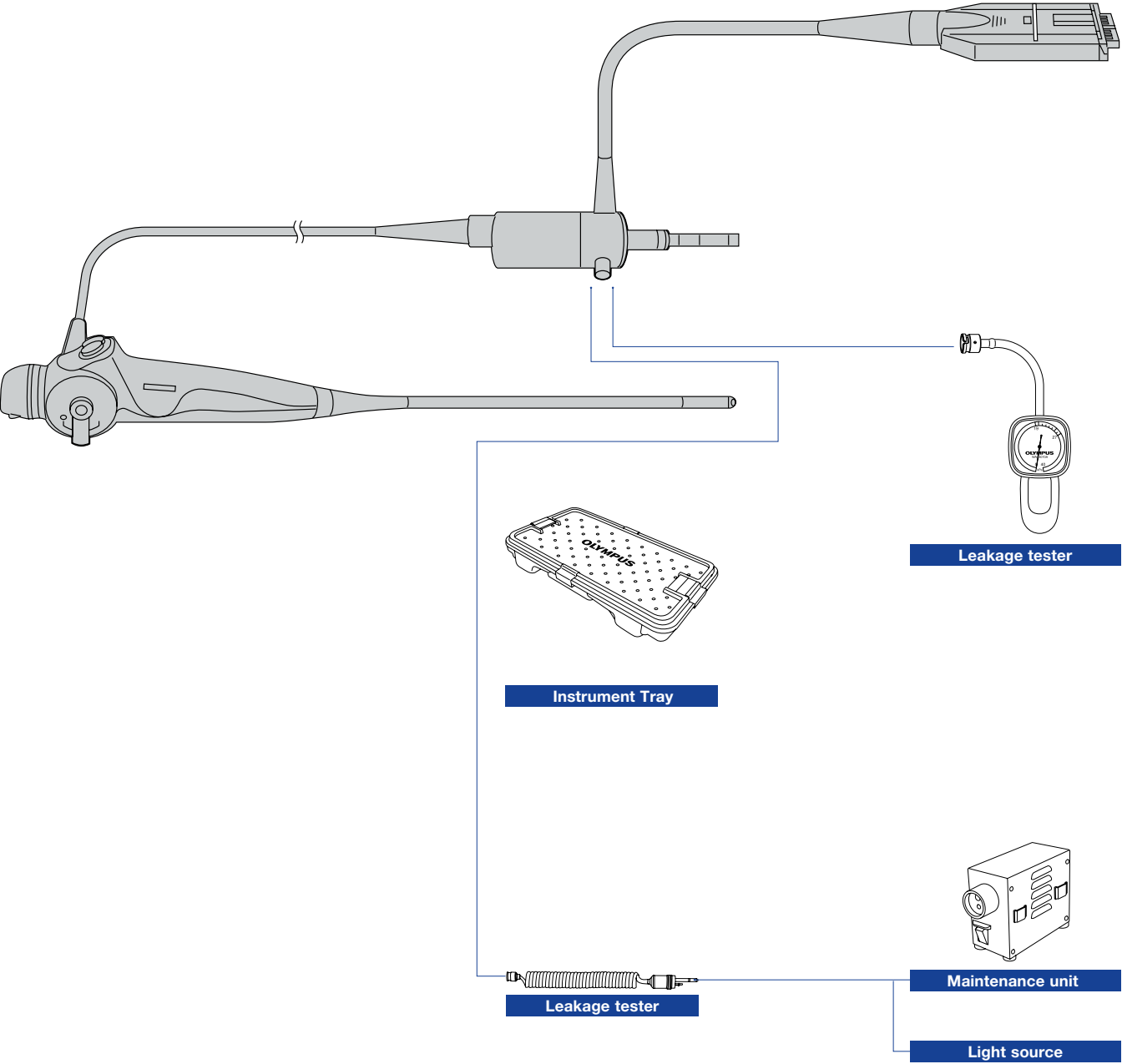
Gently wipe and dry endoscope with a sterile, lint-free cloth.

**12 Wipe the Surfaces with Alcohol**



Using a sterile, lint-free cloth moistened with alcohol, thoroughly and gently wipe the external surface of the endoscope.

# REPROCESSING TOOLS




**!**

- Clean, disinfect, and sterilize all attachments and cleaning accessories according to their instruction manual.
- Always wear personal protective equipment when cleaning, disinfecting, or sterilizing an endoscope.
- ALL channels of the endoscope MUST be cleaned and disinfected or sterilized during EVERY reprocessing cycle, even if the channels were not used during the previous patient procedure.
- Decisions regarding what methods of cleaning, disinfection, and sterilization should be used are the responsibility of trained specialists.
- Contact your local hygiene representative to determine the situation in which disinfection rather than sterilization would be appropriate in your facility.
- When you use detergent solution and disinfectant solution, always follow the manufacturer's recommendations regarding temperature and soaking time.

# MANUAL REPROCESSING OF A FLEXIBLE ENDOSCOPE WITH A WORKING CHANNEL

1

Wipe the Insertion Tube



Gently wipe the external surfaces of the insertion tube with a cloth moistened in detergent solution.

2

Detach Accessories



Disconnect the forceps/irrigation plug.

3

Flush Detergent



Fill a syringe with detergent solution and flush the solution through the instrument channel three times.

!

This guide is only a summary of steps necessary to properly reprocess your endoscope. Follow the detailed steps outlined in the **ENDOSCOPE REPROCESSING MANUAL** that was included with your endoscope. Use detergent solution and disinfectant solution which feature validated processes in accordance with national and local regulations and/or guidelines.

4

Attach the Tester



Attach the leakage tester to the venting connector on the endoscope.

5

Apply Pressure



When using MB-155 with MU-1 or the light source

Connect MB-155 to the maintenance unit (MU-1) or the light source and turn the power switch on.



When using WA23070A

Close the pressure release lever. Press the hand pump so that the pointer stays within the green area.

6

Observe



Immerse the entire endoscope in water, observe for 30 seconds while angulating the bending section and confirm that there is no continuous series of bubbles.

**CAUTION: If a leak is detected, remove from water and contact Olympus.**

7

Detach the Tester



Remove the endoscope from the water and release the air pressure in the endoscope.

When using MB-155, turn the maintenance unit or light source off. Detach the leakage tester from the air source and then the endoscope.

8

Brush the Channel



Immerse the endoscope in detergent solution. Clean the external surfaces using a clean cloth. Brush the instrument channel and channel port. Repeat until all debris is removed.

9

Clean the Channel



Fill a syringe with detergent solution and flush the solution through the instrument channel three times.

10

Clean the Surface



Using a lint-free cloth, gently wipe all debris from the endoscope's external surfaces while the endoscope is immersed in detergent solution for the recommended time.

11

Rinse the Endoscope



Immerse the endoscope in water and rinse. Attach a syringe and flush clean water through the channel three times. Remove the endoscope from water and inject air three times.

12

Wipe the Surfaces



Using a lint-free cloth, thoroughly and gently wipe and dry the external surfaces of the endoscope in preparation for disinfection.

13

Flush Disinfectant



Immerse the endoscope in the disinfectant solution. Using a syringe, fill the channel with disinfectant solution.

14


Disinfect the Endoscope



Disconnect the syringe while the endoscope is immersed. Soak for the time specified by the manufacturer.

15

Rinse the Surfaces



Remove the endoscope from the disinfectant solution and immerse in deionized water. Using a sterile, lint-free cloth, thoroughly rinse and gently wipe all external surfaces.

16

Rinse the Channel



Attach a syringe and flush deionized water three times and inject air three times.

17

Flush Alcohol and Air



Attach a syringe filled with alcohol and flush three times. Inject air three times.

18

Wipe the Surfaces



Disconnect the syringe. Using a sterile, lint-free cloth, thoroughly and gently wipe and dry the external surfaces of the endoscope.

19

Wipe the Surfaces with Alcohol



Using a sterile, lint-free cloth moistened with alcohol, thoroughly and gently wipe the external surfaces of the endoscope.

11 PREPARATION, CLEANING, AND HYGIENE  
REPROCESSING TOOLS

# REPROCESSING TOOLS

The diagram illustrates the reprocessing tools for a flexible endoscope with a working channel. A central illustration of the endoscope is shown with lines connecting it to various tools and components. The tools are categorized as follows:

- Channel Cleaning Brush:** BW-15B, BW-421B (disposable / dual-ended brush), BW-411B (disposable / combination brush).
- Channel Opening Cleaning Brush:** MH-507 or MAJ-1339 (disposable).
- Syringe 30 ml:** A standard syringe used for flushing.
- Leakage Tester:** A device used to check for leaks in the endoscope.
- Instrument Tray:** A tray used to hold the endoscope and its components.
- Maintenance Unit:** A unit used for maintaining the endoscope.
- Light Source:** A unit used for providing light to the endoscope.

!

- Clean, disinfect, sterilize all attachments and cleaning accessories according to their instruction manuals.
- Always wear personal protective equipment when cleaning, disinfecting, or sterilizing an endoscope.
- **ALL** channels of the endoscope **MUST** be cleaned and disinfected or sterilized during **EVERY** reprocessing cycle, even if the channels were not used during the previous patient procedure.
- Decisions regarding what methods of cleaning, disinfection, sterilization should be used are the responsibility of trained specialists.
- **Contact your local hygiene representative to determine the situation in which disinfection rather than sterilization would be appropriate in your facility.**
- When you use detergent solution and disinfectant solution, always follow the manufacturer's recommendations regarding temperature and soaking time.

134

135



# AUTOMATED REPROCESSING OF A FLEXIBLE ENDOSCOPE

## Use of Endoscope Washer-Disinfector

- ENT endoscopes also can be disinfected by using the washer-disinfector.
- Dedicated upgrade kits exist for ENT endoscopes.
- Some national guidelines already recommend the use of a washer-disinfector for ENT endoscopes:
  - United Kingdom, Department of Health – Decontamination of flexible endoscopes –Decontamination of nasendoscopes (2013):  
“Irrespective of whether an endoscope has lumens, decontamination in an EWD is likely to give enhanced risk reduction.”
  - The Netherlands, SFERD Handbook, version 2.1, (2011):  
Channel-less endoscope can be leak-tested in the washer-disinfector after every endoscopy program to ensure that the scopes are automatically tested.



ETD4: Endoscope Washer-disinfector

# STORAGE AND HANDLING OF A FLEXIBLE ENDOSCOPE

## Storage and Handling

- Since today’s endoscopes are more and more advanced and sophisticated, the cost of repairing them could cause a real headache to the health care facility. Damage can occur not only as a result of regular wear and tear but also due to the improper handling and transportation of endoscopes.
- Endoscopes during clinical use are contaminated by multiple microorganisms. Transporting contaminated endoscopes without placing them into a closed container highly increases the risk of contaminating the environment, health care workers, or clean endoscopes.
- Some examples from the national guidelines of various countries on how to properly handle flexible endoscopes:
  - USA – SGNA: Society of Gastroenterology Nurses and Associates: “Transport the endoscope to the reprocessing area in an enclosed container.”
  - Germany – RKI: Hygiene Requirements for Reprocessing Flexible Endoscopes and Additional Endoscopic Instrumentation: “The used endoscope is transported to the reprocessing room in a closed receptacle (e.g. a tray with a lid) in order to avoid contamination of the environment.”
  - The Netherlands - SFERD Handbook : “The transportation of the scopes should take place in closed containers that can be cleaned and disinfected properly.”



ETD+: Endoscope Drying Cabinet




















ETS: Endoscope Transport System

## PRODUCT INFORMATION














PORTFOLIO OVERVIEW








Flexible Endoscopes			
Video Scopes	<b>ENF-VH</b> N3828360 	<ul style="list-style-type: none"><li>Field of view: ..... 110°</li><li>Depth of field: ..... 5–50 mm</li><li>Distal end outer diameter: ..... 3.9 mm</li><li>Insertion tube outer diameter: .. 3.6 mm</li><li>Working length: ..... 300 mm</li><li>Angulation range: ..... Up: 130°, Down: 130°</li></ul>	
	<b>ENF-V3</b> N3828260 	<ul style="list-style-type: none"><li>Field of view: ..... 90°</li><li>Depth of field: ..... 3.5–50 mm</li><li>Distal end outer diameter: ..... 2.6 mm</li><li>Insertion tube outer diameter: .. 2.9 mm</li><li>Working length: ..... 300 mm</li><li>Angulation range: ..... Up: 130°, Down: 130°</li></ul>	
	<b>ENF-V2</b> N3633760 	<ul style="list-style-type: none"><li>Field of view: ..... 90°</li><li>Depth of field: ..... 5–50 mm</li><li>Outer diameter (distal tip): ..... 3.2 mm</li><li>Outer diameter (insertion tube): 3.4 mm</li><li>Working length: ..... 300 mm</li><li>Maximum angulation: ..... Up: 130°, Down: 130°</li></ul>	
	<b>ENF-VT2</b> N5408430 	<ul style="list-style-type: none"><li>Compatible with laser and electrosurgery treatments</li><li>Field of view: ..... 90°</li><li>Depth of field: ..... 2–40 mm</li><li>Outer diameter (distal tip): ..... 4.8 mm</li><li>Outer diameter: ..... 4.9 mm</li><li>Working length: ..... 365 mm</li><li>Maximum angulation: ..... Up: 130°, Down: 130°</li><li>Instrument channel ..... Ø 2.0 mm</li></ul>	
	<b>ENF-VQ</b> N3633860 	<ul style="list-style-type: none"><li>Field of view: ..... 90°</li><li>Depth of field: ..... 5–50 mm</li><li>Distal end outer diameter ..... 3.9 mm</li><li>Working length: ..... 300 mm</li><li>Angulation range: ..... Up: 130°, Down: 130°</li></ul>	
	<b>ENF-P4</b> 5363530 	<ul style="list-style-type: none"><li>Field of view: ..... 85°</li><li>Depth of field: ..... 5–50 mm</li><li>Distal end outer diameter: ..... 3.4 mm</li><li>Working length: ..... 300 mm</li><li>Angulation range: ..... Up - 130°, Down - 130°</li></ul>	
	<b>ENF-T3</b> N3823530 	<ul style="list-style-type: none"><li>Field of view: ..... 85°</li><li>Depth of field: ..... 5–50 mm</li><li>Distal end outer diameter: ..... 4.8 mm</li><li>Working length: ..... 365 mm</li><li>Channel inner diameter: ..... 2.2 mm</li><li>Angulation range: ..... Up: 130°, Down: 130°</li></ul>	

Flexible Endoscopes			
<b>Fiberscopes</b>	<b>ENF-GP</b> 5789030	<ul style="list-style-type: none"><li>Field of view: ..... 85°</li><li>Depth of field: ..... 5–50 mm</li><li>Outer diameter (distal tip): ..... 3.4 mm</li><li>Outer diameter: ..... 3.6 mm</li><li>Working length: ..... 300 mm</li><li>Maximum angulation: ..... Up: 130°, Down: 130°</li></ul>	
<b>Miniature Light Source</b>	<b>EndoLED</b> WA91502A	<ul style="list-style-type: none"><li>For flexible endoscopes</li><li>For AA type batteries</li><li>Dimensions: ..... Width: 34 mm Height: 112 mm Depth: 39 mm</li><li>Weight (without batteries): ..... 140 g</li></ul>	
<b>Fiberscopes</b>	<b>ENF-XP</b> 5363430	<ul style="list-style-type: none"><li>Field of view: ..... 75°</li><li>Depth of field: ..... 2.5–50 mm</li><li>Outer diameter (distal tip) ..... 1.8 mm</li><li>Outer diameter: ..... 2.2 mm</li><li>Working length: ..... 300 mm</li><li>Maximum angulation: ..... Up: 130°, Down: 130°</li></ul>	
Rigid Endoscopes			
<b>High Definition Laryngoscope</b>	<b>Telescope HD</b> WA96100A	<ul style="list-style-type: none"><li>Diameter: ..... 10 mm</li><li>Working length: ..... 167 mm</li><li>Direction of view: ..... 70°</li></ul>	
	<b>Telescope HD</b> WA96105A	<ul style="list-style-type: none"><li>Diameter: ..... 10 mm</li><li>Working length: ..... 167 mm</li><li>Direction of view: ..... 90°</li></ul>	
<b>Miniature Light Source</b>	<b>EndoLED</b> WA91500A	<ul style="list-style-type: none"><li>For rigid endoscopes</li><li>For AA type batteries</li><li>Dimensions: ..... Depth: 70 mm Height: 90 mm Depth: 35 mm</li><li>Weight (without batteries): ..... 119 g</li></ul>	
Camera Heads			
<b>Full HD 3CCD Camera Head</b>	<b>CH-S190-XZ-E</b> N3804860 	<ul style="list-style-type: none"><li>Enhanced resolution and control</li><li>Autoclavability</li><li>NBI (Narrow Band Imaging)</li><li>Three fully programmable remote switches</li><li>Optical zoom via remote control</li><li>Focus via remote control</li></ul>	
<b>HD Camera Head</b>	<b>OTV-S7 Pro H-HD-L08E</b> N3499640 	<ul style="list-style-type: none"><li>Head size (focus ring × total length) ... Ø 20 × 82 mm</li><li>Camera head weight: ..... 60 g (excluding cable)</li></ul>	









PORTFOLIO OVERVIEW

Telescopes for Larynx Surgery

			
4 mm OES ELITE Telescopes	Telescope WA2T400A	<ul style="list-style-type: none"><li>· Diameter: ..... 4 mm</li><li>· Working length: ..... 280 mm</li><li>· Direction of view: ..... 0°</li></ul>	 
	Telescope WA2T412A	<ul style="list-style-type: none"><li>· Diameter: ..... 4 mm</li><li>· Working length: ..... 280 mm</li><li>· Direction of view: ..... 12°</li></ul>	 
	Telescope WA2T430A	<ul style="list-style-type: none"><li>· Diameter: ..... 4 mm</li><li>· Working length: ..... 282 mm</li><li>· Direction of view: ..... 30°</li></ul>	 
	Telescope WA2T43WA	<ul style="list-style-type: none"><li>· Diameter: ..... 4 mm</li><li>· Working length: ..... 283 mm</li><li>· Direction of view: ..... 30° Wide angle</li></ul>	 
	Telescope WA2T470A	<ul style="list-style-type: none"><li>· Diameter: ..... 4 mm</li><li>· Working length: ..... 284 mm</li><li>· Direction of view: ..... 70°</li></ul>	 

			
5 mm Telescopes	Telescope WA50372B	<ul style="list-style-type: none"><li>· Diameter: ..... 5.4 mm</li><li>· Working length: ..... 299 mm</li><li>· Direction of view: ..... 0°</li></ul>	 
	Telescope WA50373B	<ul style="list-style-type: none"><li>· Diameter: ..... 5.4 mm</li><li>· Working length: ..... 299 mm</li><li>· Direction of view: ..... 30°</li></ul>	 
	Telescope WA50374B	<ul style="list-style-type: none"><li>· Diameter: ..... 5.4 mm</li><li>· Working length: ..... 299 mm</li><li>· Direction of view: ..... 45°</li></ul>	 

Imaging Systems


VISERA ELITE Light Source	CLV-S190 N3643950 	<ul style="list-style-type: none"><li>· Dimensions: ..... Width: 370 mm Height: 150 mm Depth: 474 mm</li><li>· Weight: ..... 14.9 kg</li><li>· Examination lamp: ..... xenon short-arc lamp, 300 W</li></ul>	
VISERA ELITE Video System Center	OTV-S190 N3643860 	<ul style="list-style-type: none"><li>· Dimensions: ..... Width: 370 mm Height: 150 mm Depth: 474 mm</li><li>· Weight: ..... 14.9 kg</li></ul>	
Trolley	WM-NP2 K10021613	<ul style="list-style-type: none"><li>· Mobile workstation</li></ul>	
Monitor	26" full HD OEV-262H N5374360	<ul style="list-style-type: none"><li>· Full 10 bit (1.07billion color) display (10 bit LCD panel and 10 bit processing)</li><li>· Advanced LCD panel with LED backlight</li><li>· 26" full HD (instead of WUXGA), contrast 1400:1 (instead of 1000:1), luminance</li><li>· 450cd/m² (instead of 400), 16:9 aspect ratio</li><li>· A.I.M.E. (advanced image multiple enhancer) without compromising resolution</li></ul>	
Video System Center	CV-170 	<ul style="list-style-type: none"><li>· Deliver sharp and clear details, boosting observation capabilities when viewing mucosal structures and other vessel patterns.</li><li>· Compatibility to NBI (see chapter xxxx)</li><li>· All-in-one design condenses its performance into a compact and convenient size.</li><li>· Long-life LED lamp minimizes lamp replacement and as a result maintenance is much easier.</li><li>· Ensuring long hours of operation while reducing energy and noise.</li></ul>	
		<ul style="list-style-type: none"><li>· Dimensions, standard: ..... Width: 295 mm Height: 145 mm Depth: 425 mm</li><li>· Weight: ..... 11 kg</li></ul>	
	E0497606	· CV-170 with ENF-V3	
	E0497607	· CV-170 with ENF-VH	
	E0497647	· CV-170 with ENF-VT2	




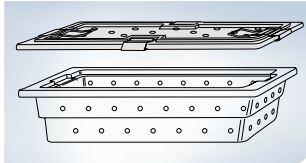
PORTFOLIO OVERVIEW

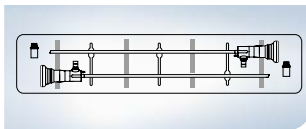
StrobeLED			
Light Source for Stroboscopy	CLL-S1 WA97010A	<ul style="list-style-type: none"><li>Reliable stroboscopy algorithm</li><li>Great illumination in permanent and stroboscopy mode</li><li>Noise-free</li><li>Adjustable duty cycle: Choice between more resolution or more brightness depending on the application</li><li>Low energy consumption</li><li>Low lifetime costs</li></ul> <ul style="list-style-type: none"><li>Dimensions: ..... Width: 370 mm, Height: 111 mm, Hephth: 475 mm</li><li>Weight: ..... 7.85 kg</li></ul>	
Documentation			
Image Management Hub	IMH-10 N3808460	<ul style="list-style-type: none"><li>Video and image storage at the same time</li><li>One-touch image record or capture</li><li>Linked to an Olympus video processor</li></ul> <ul style="list-style-type: none"><li>Dimensions: ..... Width: 370 mm, Height: 108.5 mm, Depth: 413 mm</li><li>Weight: ..... 8.5 kg</li><li>Recording media: ... Built-in hard disk, Blu-ray disc, DVD, USB</li></ul>	
Image Management Hub	IMH-20 N3808560	<ul style="list-style-type: none"><li>Touch-screen panel display</li><li>IMH-20 hubs will link to all Olympus systems. This reduces input time and helps make management more efficient.</li><li>Two-channel simultaneous recording</li></ul> <ul style="list-style-type: none"><li>Dimensions: ..... Width: 370 mm, Height: 167.5 mm, Depth: 413 mm</li><li>Weight: ..... 10.7 kg</li><li>Recording media: ... Built-in hard disk, Blu-ray disc, DVD, USB</li></ul>	
Reprocessing			
ETD4	<b>Specifications</b> <ul style="list-style-type: none"><li>Type/versions ..... ETD4 Plus or ETD4 Basic or ETD4 Basic Pure</li><li>Capacity ..... 2 flexible medical endoscopes. Optionally: Up to 4 ENT endoscopes</li><li>Process ..... Compatible with Olympus PAA or GA process chemistry</li><li>Outer casing ..... Stainless steel</li><li>Interfaces ..... Ethernet/TCP/IP printer port (parallel)</li><li>User interface ..... LC display 4 × 40 digits</li></ul> <hr/> <b>Dimensions</b> <ul style="list-style-type: none"><li>Dimensions (including cover) ..... Width: 900 mm, Height: 850 mm, Depth: 600 mm</li><li>Weight ..... 133.5 kg</li><li>Volume of the washing chamber ... 165 l</li><li>Maximum floor loading ..... 2158 N</li></ul> <hr/> <b>Electric power supply 400 V</b> <ul style="list-style-type: none"><li>Voltage ..... 400 V, 3 N AC 50 Hz</li><li>Voltage fluctuations ..... max. ± 10%</li><li>Fuses..... 3 × 16 A</li><li>Power consumption ..... 9.2 kW</li></ul>		

Reprocessing		
ETD Double	<b>Specifications</b>	
	Type/versions .....	ETD Double
	Capacity .....	3 flexible medical endoscopes
	Process .....	Compatible with Olympus PAA process chemistry
	Programs.....	· Standard programs for flexible medical endoscopes with different drying options · Thermoprogram for rigid instruments · Thermal self-disinfection
	Outer casing and frame .....	Stainless steel
	Interfaces.....	LAN printer port
	User interface.....	7-inch multicolor touch displays on both sides
	<b>Dimensions</b>	
	ETD Double unit .....	Width: 900 mm, Height: 2130 mm, Depth: 830 mm
	<b>Weight</b>	
	ETD Double unit .....	≤570 kg
	Maximum floor loading .....	5000 N
	<b>Electric Power Supply</b>	
	Voltage / frequency .....	400 V / 50 Hz
	Voltage fluctuations .....	+/-10%
	Fuses.....	3 × 16 A
	Power consumption .....	10.5 kW
EDC Plus	<b>Specifications</b>	
	Type/versions .....	EDC Plus
	Number of endoscope positions ...	8 (for extension units 8 and 4)
	Drying time (default setting).....	120 minutes
	Storage time (default setting) .....	168 hours
	Ambient temperature location .....	25°C (+/- 5°C) briefly 35°C
	Relative humidity location .....	30–75%
	<b>Dimensions</b>	
	EDC Plus .....	Width: 1280 mm, Height: 2130–2180 mm (height adjustable feet), Depth: 470 mm
	<b>Weight</b>	
	EDC Plus .....	200 kg
	Volume of cabinet.....	0.65 m³
	<b>Electric Power Supply</b>	
	Voltage / frequency .....	230 V / 50 Hz
	Connections .....	L1, N, PE
	Max. current.....	1,1 A
	Power consumption .....	250 W
Instrument tray	<b>For HD laryngoscopes</b>	· With lid and silicone mat
	WA05970A	· Dimensions: ..... Width: 537 mm Height: 139 mm Depth: 268 mm
	<b>For telescopes for larynx surgery</b>	· Instrument tray, for 2 telescopes
	WA05990A	· Dimensions ..... Width: 88 mm Height: 49 mm Length: 446 mm









 [www.olympus.eu/medical](http://www.olympus.eu/medical)



Specifications, design, and accessories are subject to change without any notice or obligation on the part of the manufacturer.

**OLYMPUS**

**OLYMPUS EUROPA SE & CO. KG**  
Postbox 10 49 08, 20034 Hamburg, Germany  
Wendenstrasse 14-18, 20097 Hamburg, Germany  
Phone: +49 40 23773-0, Fax: +49 40 233765  
[www.olympus-europa.com](http://www.olympus-europa.com)